CROSS SECTIONAL ANATOMY CT & MRI

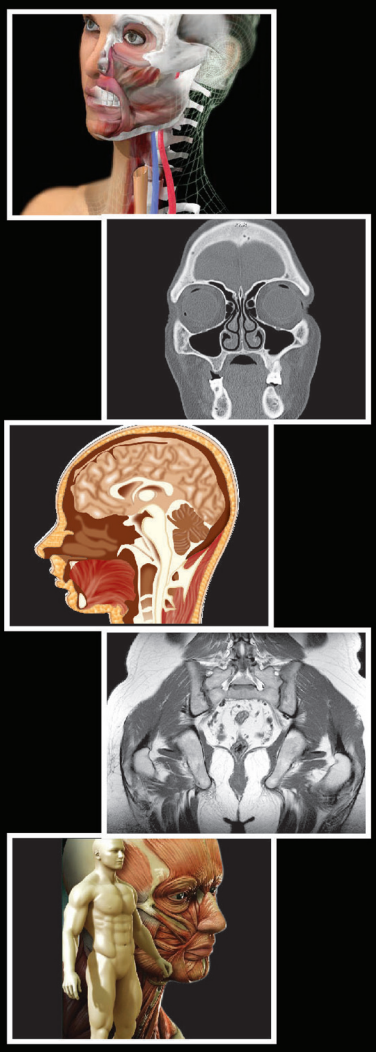

Govind Chavhan
Bhavin Jankharia

JAYPEE

Cross Sectional

ANATOMY

CT and MRI

Cross Sectional
ANATOMY
CT and MRI

Govind Chavhan MD DNB
Pediatric Radiologist
The Hospital for Sick Children
Assistant Professor, University of Toronto, Canada

Bhavin Jankharia MD
Consultant Radiologist
Jankharia Imaging Center, Mumbai, Maharashtra, India
Trustee, Radiology Education Foundation



JAYPEE BROTHERS MEDICAL PUBLISHERS (P) LTD
New Delhi • Panama City • London

Jaypee Brothers Medical Publishers (P) Ltd.

Headquarter

Jaypee Brothers Medical Publishers (P) Ltd
4838/24, Ansari Road, Daryaganj
New Delhi 110 002, India
Phone: +91-11-43574357
Fax: +91-11-43574314
Email: jaypee@jaypeebrothers.com

Overseas Offices

J.P. Medical Ltd.,
83 Victoria Street London
SW1H 0HW (UK)
Phone: +44-2031708910
Fax: +02-03-0086180
Email: info@jpmedpub.com

Jaypee-Highlights Medical Publishers Inc.
City of Knowledge, Bld. 237, Clayton
Panama City, Panama
Phone: +507-301-0496
Fax: +507-301-0499
Email: cservice@jphmedical.com

Website: www.jaypeebrothers.com
Website: www.jaypeedigital.com

© 2012, Jaypee Brothers Medical Publishers

All rights reserved. No part of this book may be reproduced in any form or by any means without the prior permission of the publisher.

Inquiries for bulk sales may be solicited at: jaypee@jaypeebrothers.com

This book has been published in good faith that the contents provided by the authors contained herein are original, and is intended for educational purposes only. While every effort is made to ensure accuracy of information, the publisher and the authors specifically disclaim any damage, liability, or loss incurred, directly or indirectly, from the use or application of any of the contents of this work. If not specifically stated, all figures and tables are courtesy of the authors. Where appropriate, the readers should consult with a specialist or contact the manufacturer of the drug or device. The authors have no financial interest in any procedure or product mentioned in this book.

Cross Sectional Anatomy CT and MRI

First Edition : **2012**

ISBN 978-93-5025-046-4

Printed at

Dedicated to

My wife Barakha
and
son Yash
for their love, support and time

—Govind Chavhan

Sana, Sach, Bijal and my parents
for their unstinting support

—Bhavin Jankharia

Preface

Cross sectional imaging like CT and MRI is the mainstay of medical imaging. Radiologists interpreting these images need to be thorough in human anatomy. Because of the vastness of the subject, it is difficult to remember anatomy. This atlas is our attempt to provide the quick reference for imaging anatomy to the radiologist while reporting. It will also be helpful to the radiology residents and those who need to understand the human anatomy.

CT and MR images of all body parts are given in all three planes. These images are accompanied by color diagrams for better understanding of the anatomy. The structures are labeled on these color images. We have also given CT and MRI angiographic images with labeling of all relevant branches.

We hope that in the era of Internet and 'Professor Google', where everything is available, this atlas will still serve as a handy, convenient and quick reference for reporting radiologists.

Best Wishes and Happy Reporting!

Govind Chavhan

Bhavin Jankharia

Acknowledgments

Authors would like to thank the following:

- The high resolution CT and MRI images used in this atlas were obtained at Jankharia Imaging, Mumbai. Authors would like to thank entire team at Jankharia Imaging for their help in this.
- Reshma Dalvi (Consultant Radiologist, Goa, India) for her significant contribution in chapters on Upper and Lower Extremities.
- Shri Jitendar P Vij (Chairman and Managing Director) and Mr Tarun Vij of M/s Jaypee Brothers Medical Publishers (P) Ltd., New Delhi for publishing this atlas.
- Mr Tarun Duneja (Director–Publishing) and his team of Graphics for the excellent work on color images.

Contents

SECTION 1: HEAD AND NECK

1. Brain 3
2. Orbit 27
3. PNS and Skull Base 35
4. Temporal Bones and TM Joint 47
5. Neck 59

SECTION 2: SPINE

6. Spine 73

SECTION 3: TRUNK

7. Chest 101
8. Abdomen 117
9. Pelvis 137

SECTION 4: UPPER EXTREMITY

10. Shoulder 161
11. Arm and Forearm 173
12. Elbow 179
13. Wrist 187
14. Upper Extremity Vessels 195

SECTION 5: LOWER EXTREMITY

15. Hips 201
16. Thigh and Calf 213
17. Knee 227
18. Ankle and Foot 237
19. Lower Extremity Vessels 259

Index *263*

Section 1



Head and Neck

- **Brain**
- **Orbit**
- **PNS and Skull Base**
- **Temporal Bones and TM Joint**
- **Neck**

CHAPTER 1

Brain



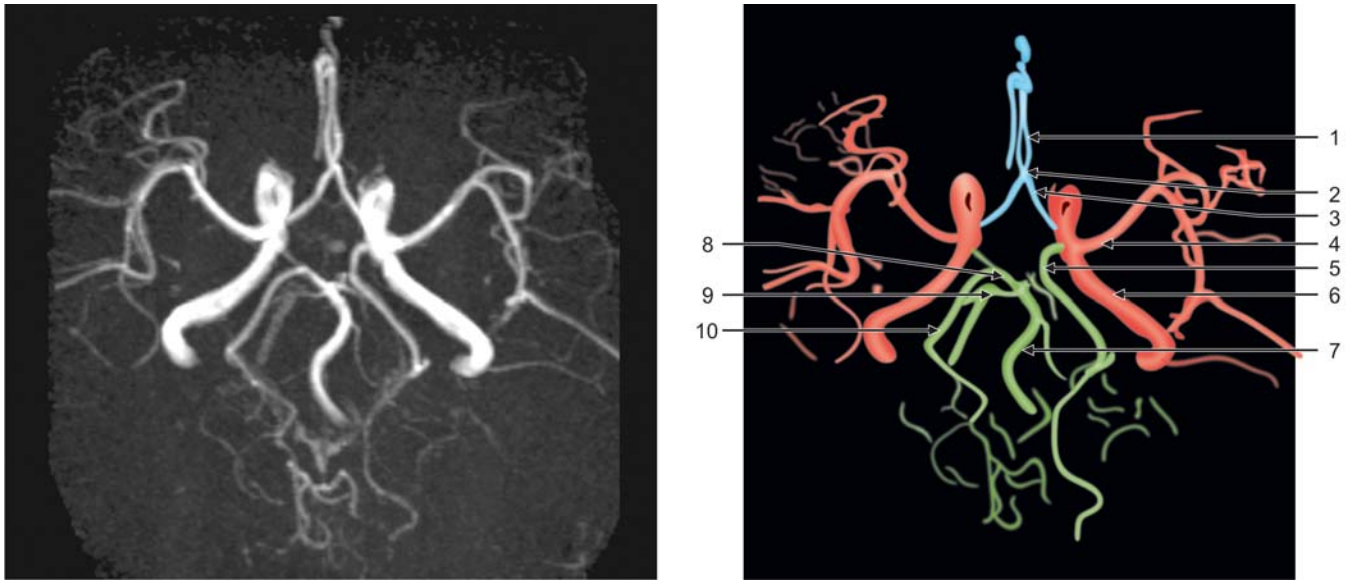

Figure 1.1

1. A2, anterior cerebral artery
2. Anterior communicating artery
3. A1 ACA
4. M1, Middle cerebral artery
5. Posterior communicating artery
6. Internal carotid artery
7. Basilar artery
8. P1, PCA
9. Superior cerebral artery
10. P2, Posterior cerebral artery

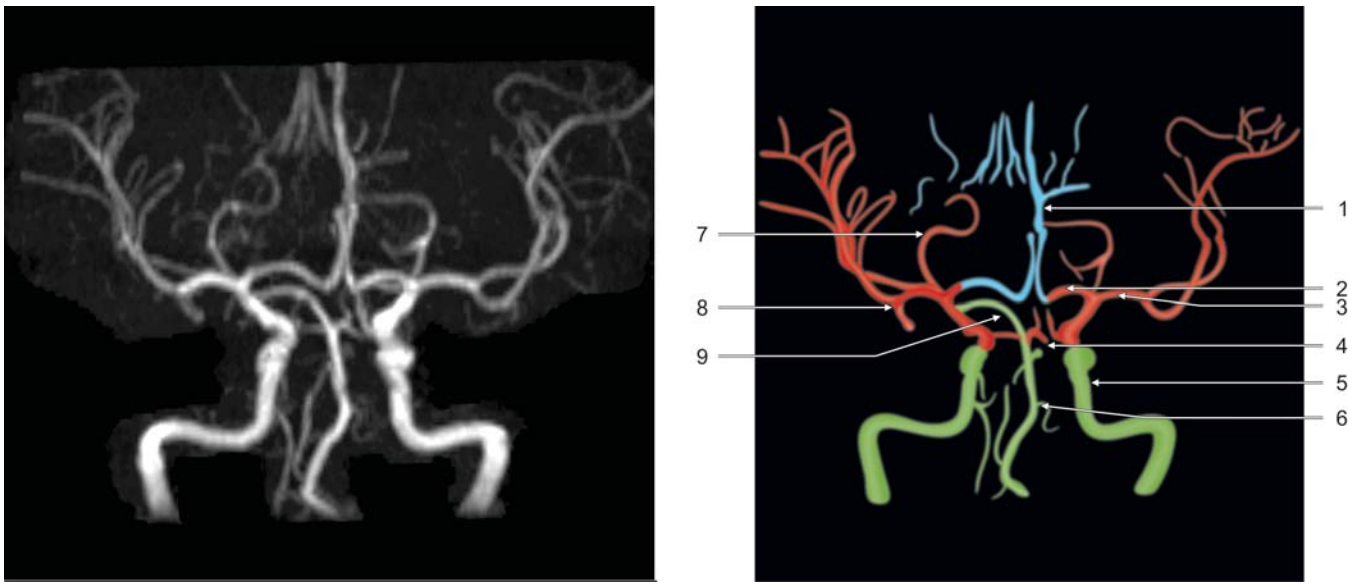

Figure 1.2

1. A2, anterior cerebral artery
2. A1, ACA
3. M1, middle cerebral artery
4. Superior cerebellar artery
5. Internal carotid artery
6. Basilar artery
7. PCA
8. MCA, genu
9. Posterior cerebral artery



Figure 1.3

1. Posterior cerebral artery
2. Superior cerebellar artery
3. Posterior communicating artery
4. Basilar artery
5. Anterior cerebral artery
6. Middle cerebral artery
7. ICA, supraclinoid
8. ICA, cavernous
9. Internal carotid artery, petrous part

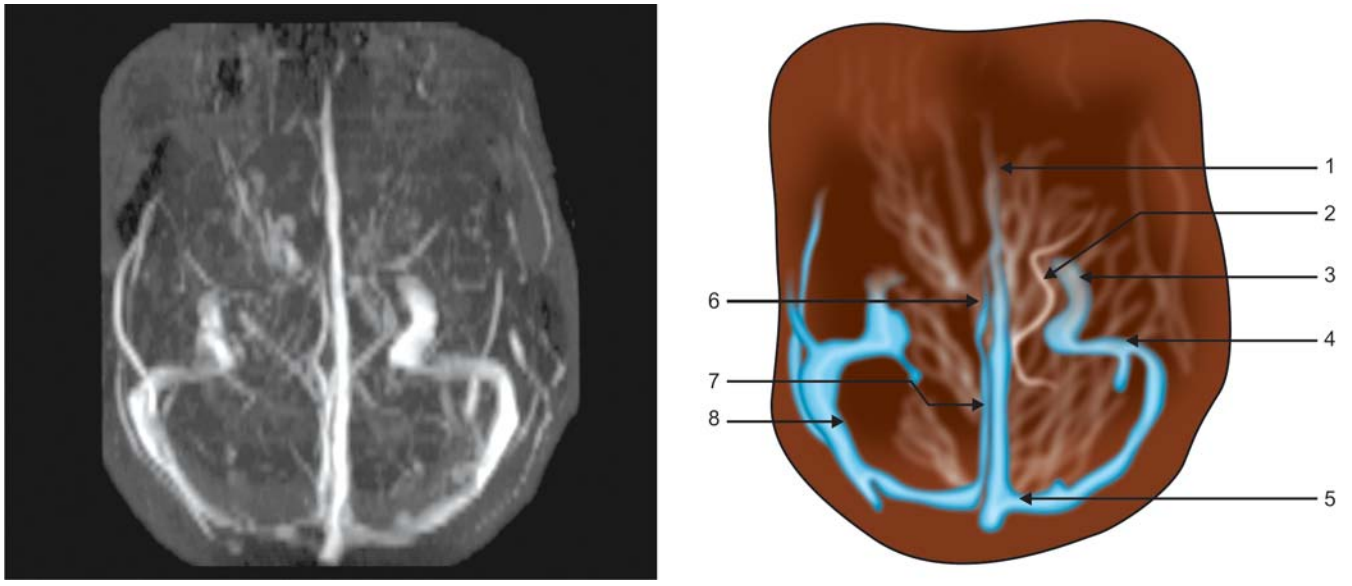

Figure 1.4

1. Superior sagittal sinus
2. Basal vein of Rosenthal
3. Internal jugular vein
4. Sigmoid sinus
5. Torcular herophili
6. Internal cerebral vein
7. Straight sinus
8. Transverse sinus

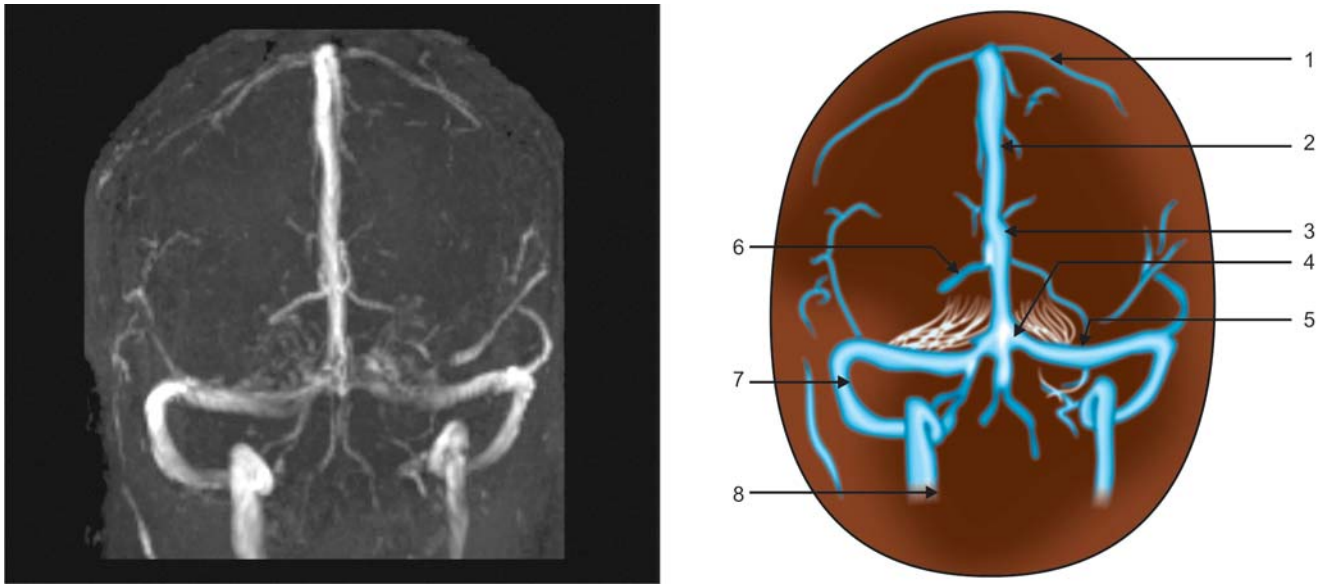

Figure 1.5

1. Cortical veins
2. Superior sagittal sinus
3. Internal cerebral vein
4. Torcular herophili
5. Transverse sinus
6. Basal vein of Rosenthal
7. Sigmoid sinus
8. Internal jugular vein

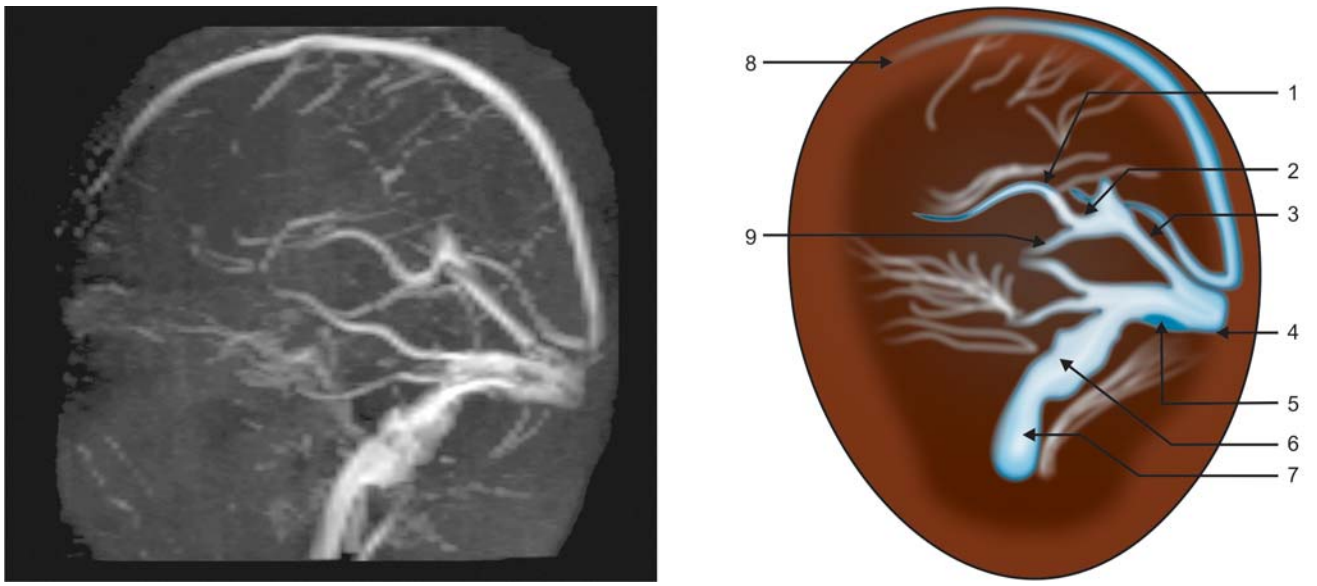

Figure 1.6

1. Internal cerebral vein
2. Vein of Galen
3. Straight sinus
4. Torcular herophili
5. Transverse sinus
6. Sigmoid sinus
7. Internal jugular vein
8. Superior sagittal sinus
9. Basal vein of Rosenthal

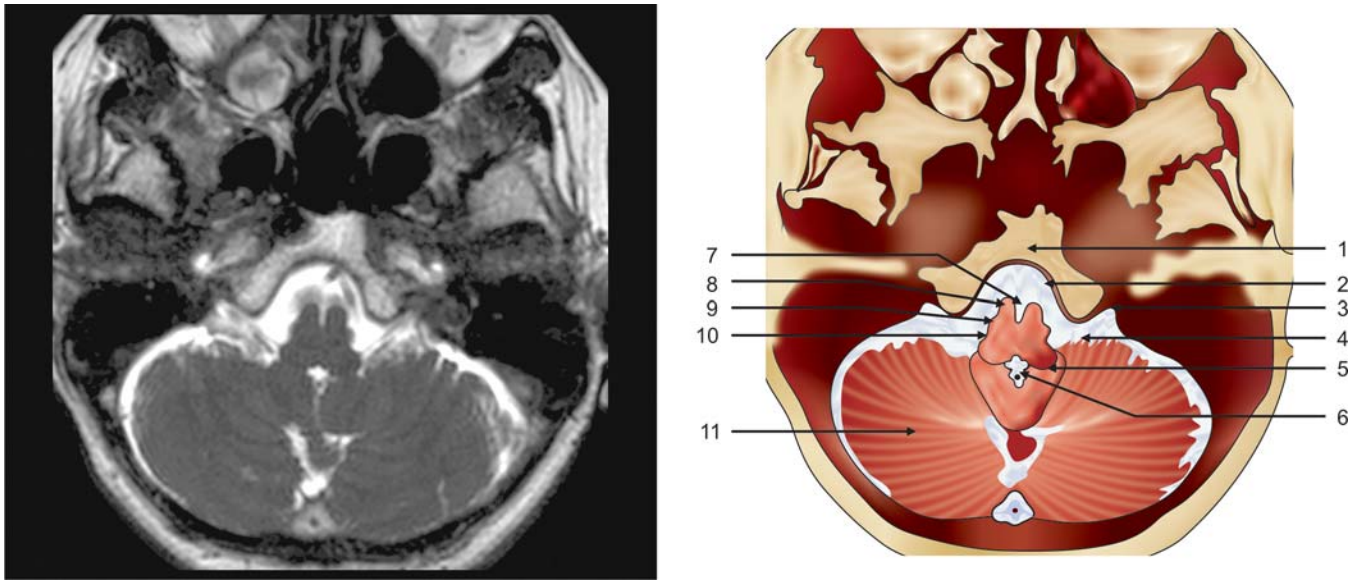

Figure 1.7

1. Clivus
2. Left vertebral artery
3. Jugular foramen
4. IX, X XI cranial nerves
5. Restiform body
6. Obex
7. Anterior median sulcus
8. Pyramid
9. Olive
10. Postolivary sulcus
11. Cerebellum

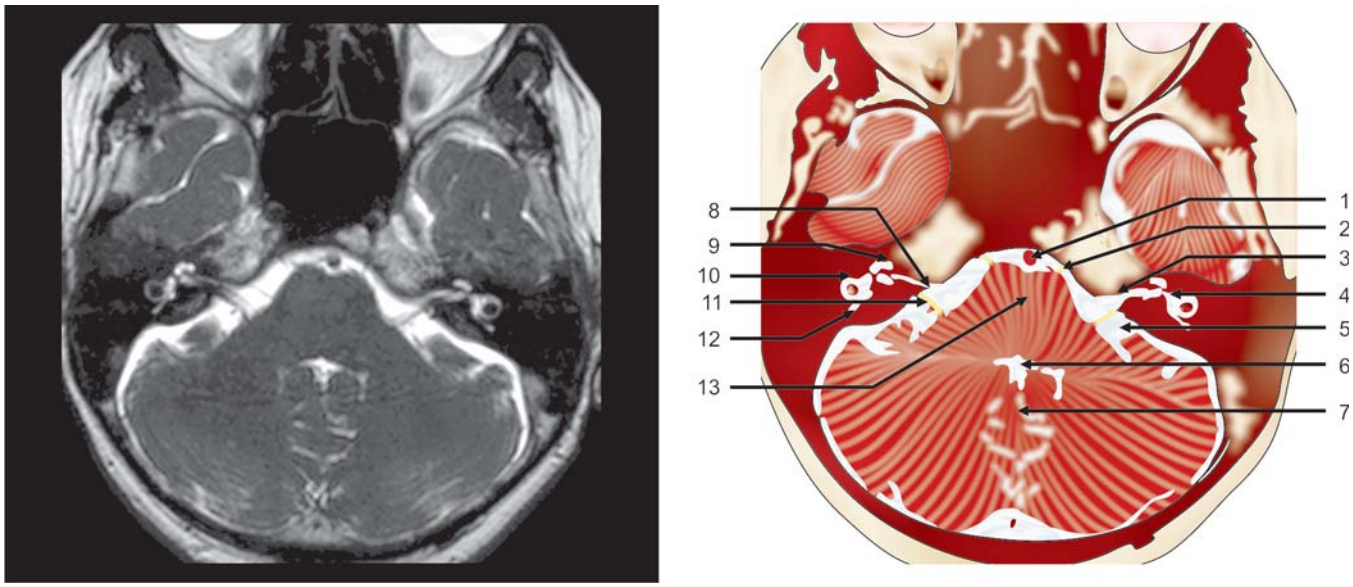

Figure 1.8

1. Basilar artery
2. Abducent nerve
3. Internal auditory canal
4. Vestibule
5. CP angle cistern
6. Fourth ventricle
7. Vermis
8. Facial nerve
9. Cochlea
10. Lateral semicircular canal
11. Vestibular nerve
12. Posterior semicircular canal
13. Pons

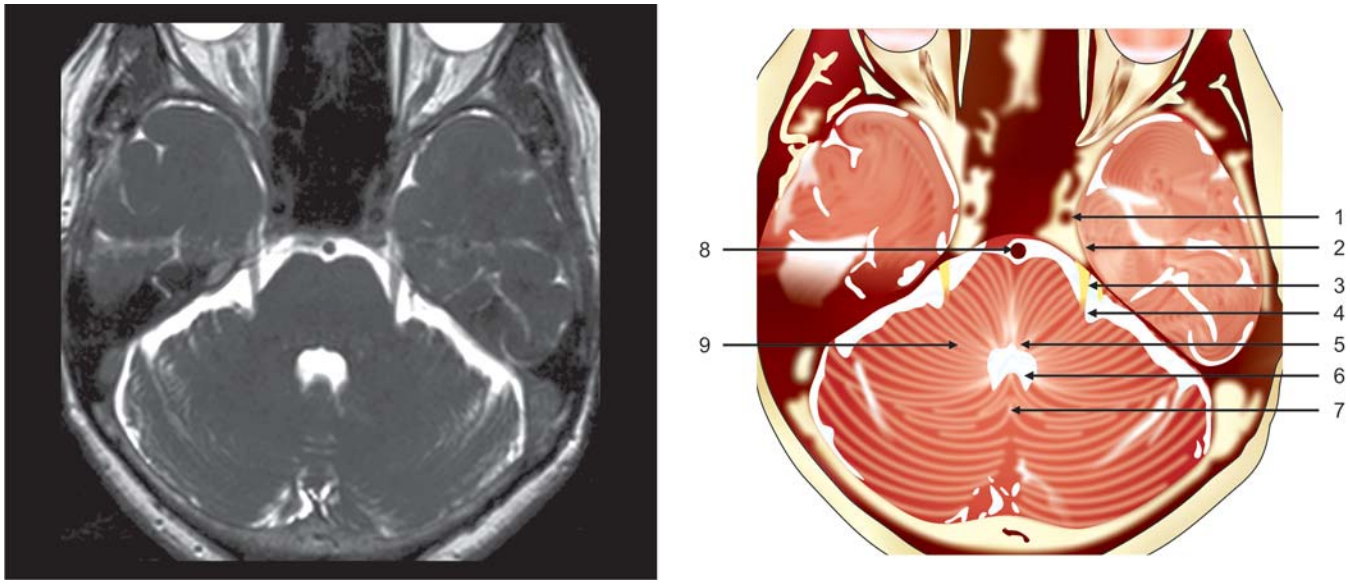

Figure 1.9

1. ICA
2. Meckel's cave
3. Trigeminal nerve
4. Root entry zone
5. Facial colliculus
6. Fourth ventricle
7. Vermis
8. Basilar artery
9. Middle cerebellar peduncle

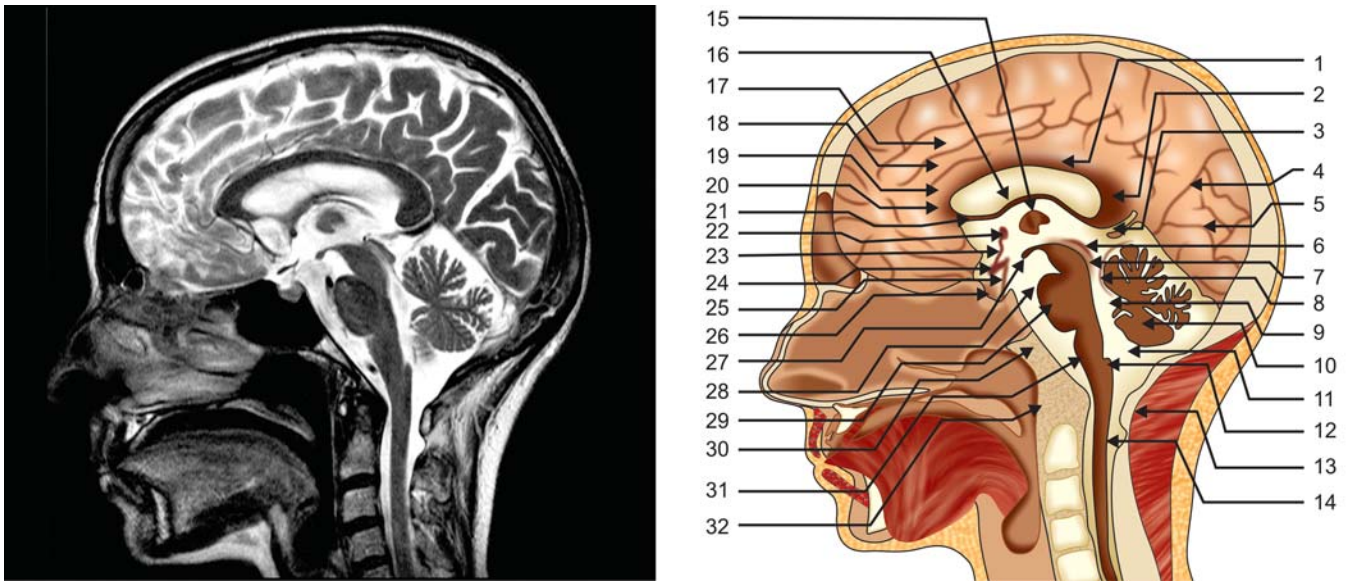

Figure 1.10

1. Corpus callosum body
2. Splenium
3. Vein of Galen
4. Parieto-occipital sulcus
5. Calcarine sulcus
6. Tectum
7. Aqueduct of sylvius
8. Superior medullary velum
9. Fourth ventricle
10. Cerebellum
11. Cerebellar tonsil
12. Obex
13. Posterior tubercle, C1
14. Spinal cord
15. Massa intermedia, thalamus
16. Fornix
17. Cingulate sulcus
18. Cingulate gyrus
19. Pericallosal sulcus
20. Genu, corpus callosum
21. Rostrum, corpus callosum
22. Anterior commissure
23. Anterior lamina
24. Optic chiasm
25. Pituitary stalk
26. Pituitary gland
27. Mammillary body
28. Basilar artery
29. Pons
30. Clivus
31. Medulla oblongata
32. Anterior tubercle C1

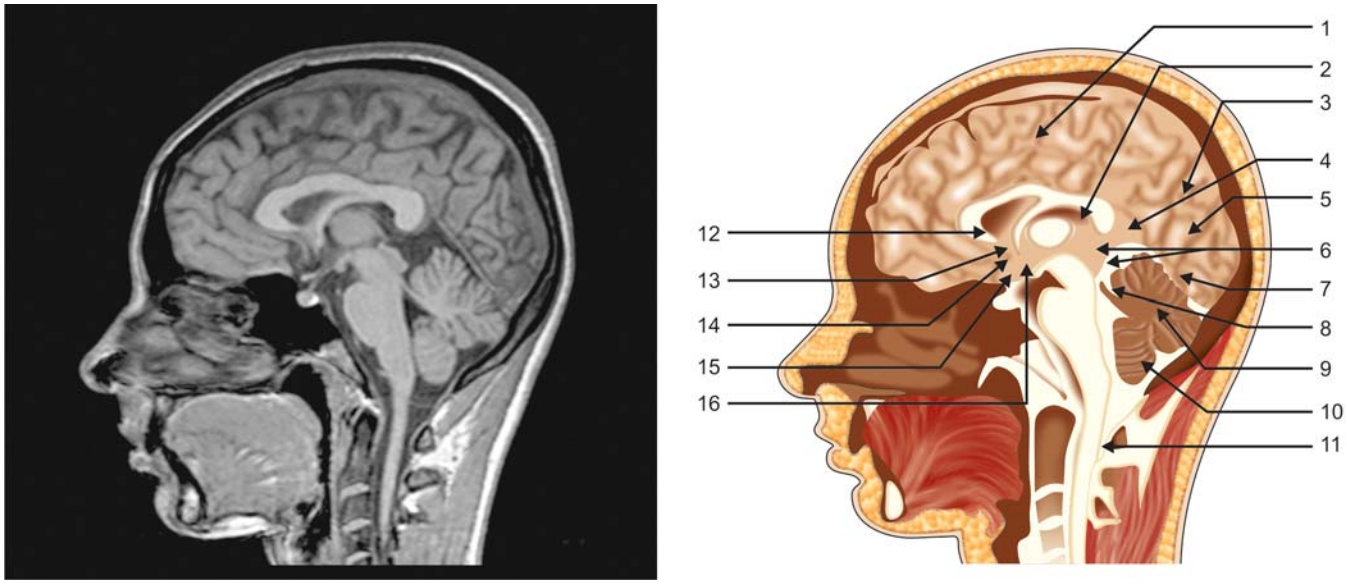

Figure 1.11

1. Cingulate sulcus
2. Internal cerebral vein
3. Parieto-occipital sulcus
4. Superior cerebellar cistern
5. Calcarine sulcus
6. Superior, inferior colliculi
7. Straight sinus
8. Superior medullary velum
9. Vermis
10. Tonsil
11. Spinal cord
12. Rostrum
13. Anterior commissure
14. Lamina terminalis
15. Tuber cinereum
16. Third ventricle chiasmatic, infundibular recesses

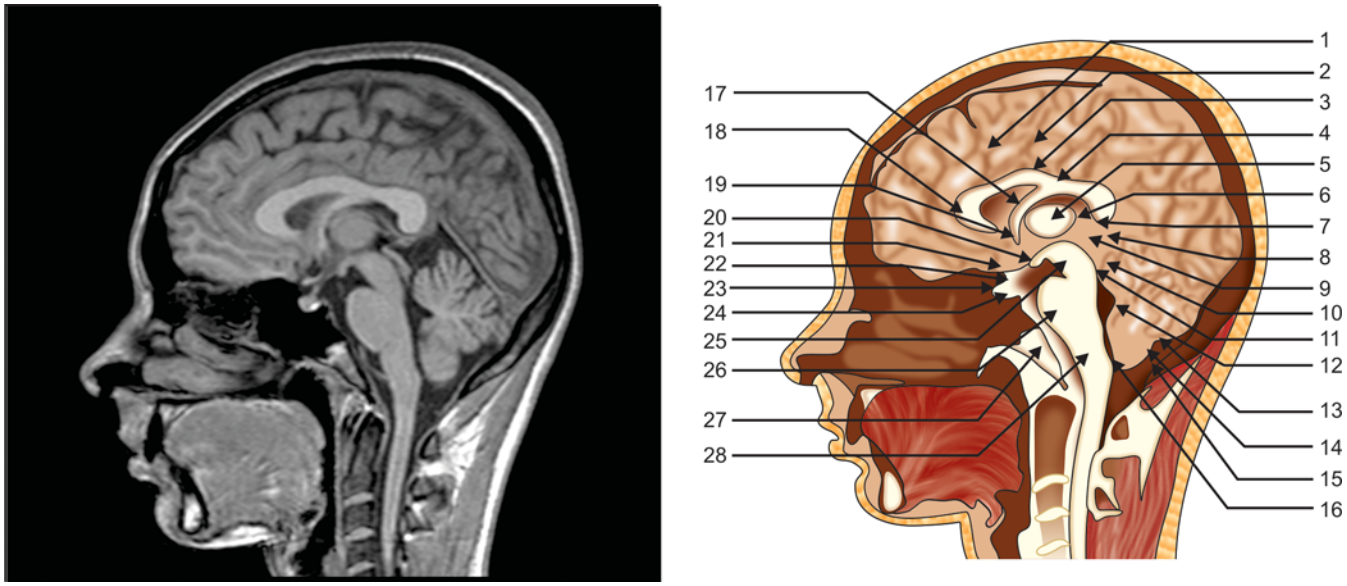

Figure 1.12

1. Cingulate gyrus
2. Cingulate sulcus
3. Pericallosal sulcus
4. Corpus callosum
5. Massa intermedia
6. Stria medullaris thalami
7. Habenular commissure
8. Pineal gland
9. Posterior commissure
10. Tectum-midbrain
11. Aqueduct of sylvius
12. Fourth ventricle
13. Vermis
14. Tonsil
15. Cisterna magna
16. Foramen of Magendie
17. Fornix
18. Genu
19. Anterior commissure
20. Mammillary body
21. Optic chiasm
22. Pituitary stalk
23. Anterior pituitary
24. Posterior pituitary
25. Midbrain
26. Pons
27. Clivus
28. Medulla oblongata

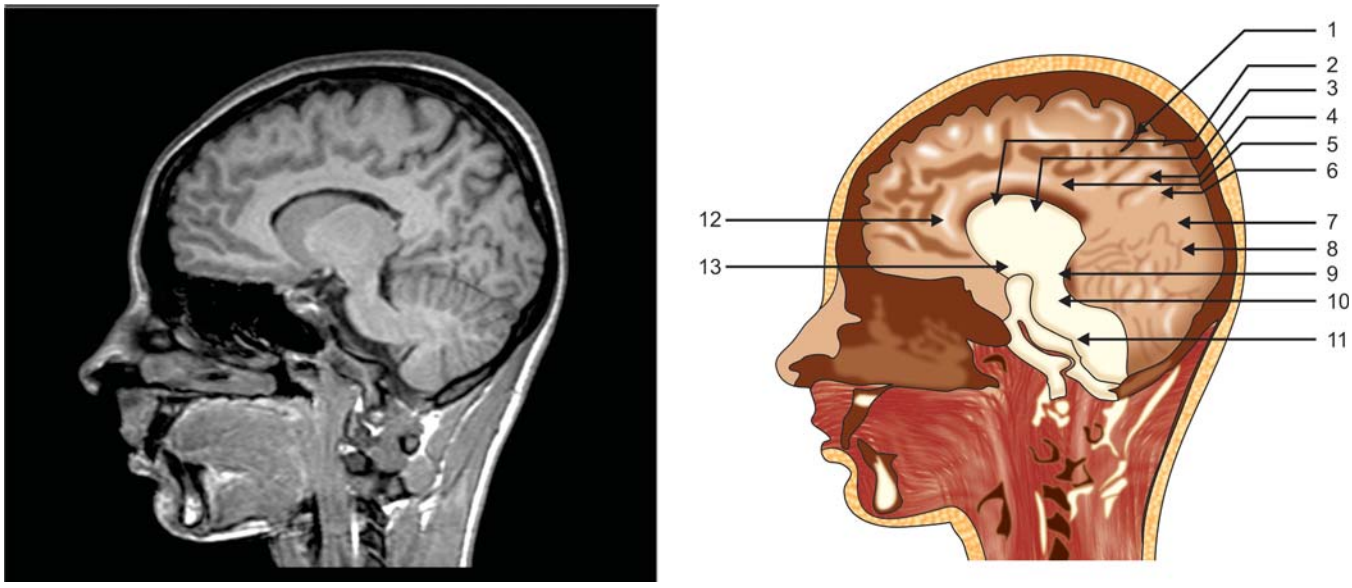

Figure 1.13

1. Cingulate sulcus
2. Caudate nucleus
3. Thalamus
4. Precuneus
5. Lateral ventricle
6. Parieto-occipital sulcus
7. Cuneus
8. Calcarine sulcus
9. Cerebral peduncle
10. Middle cerebellar peduncle
11. Cerebellar hemisphere
12. Genu
13. Optic tract

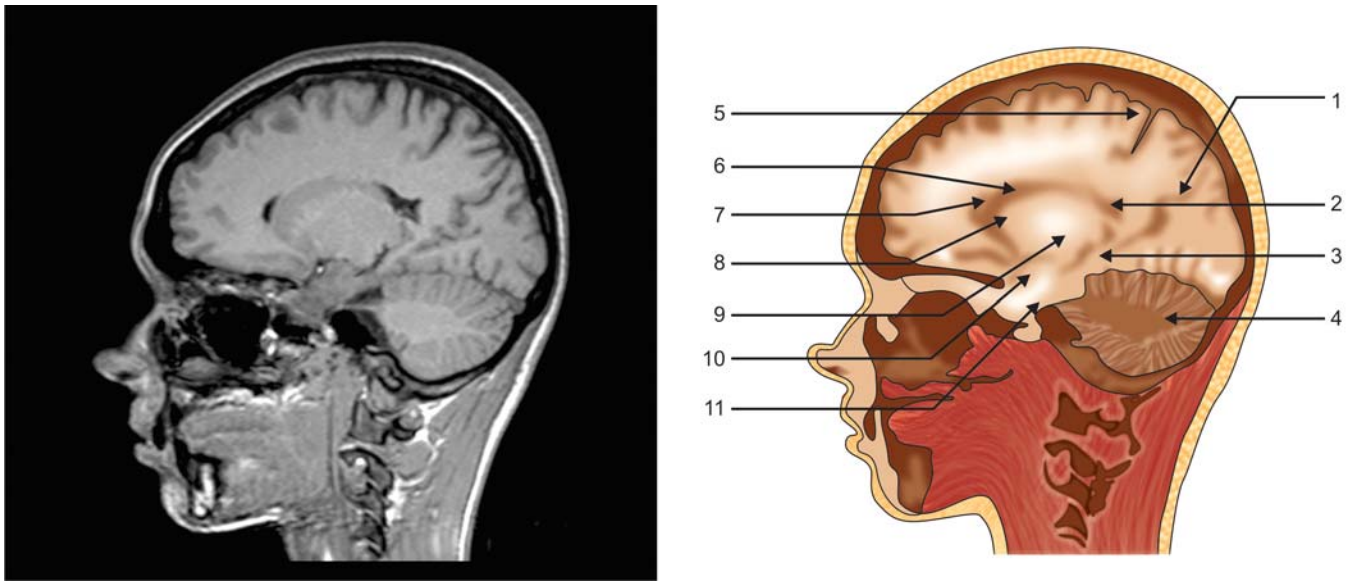

Figure 1.14

1. Parieto-occipital sulcus
2. Atrium of lateral ventricle
3. Parahippocampal gyrus
4. Cerebellar hemisphere
5. Cingulate sulcus, marginal branch
6. Caudate nucleus body
7. Lateral ventricle
8. Internal capsule
9. Thalamus
10. Uncus
11. Trigeminal nerve



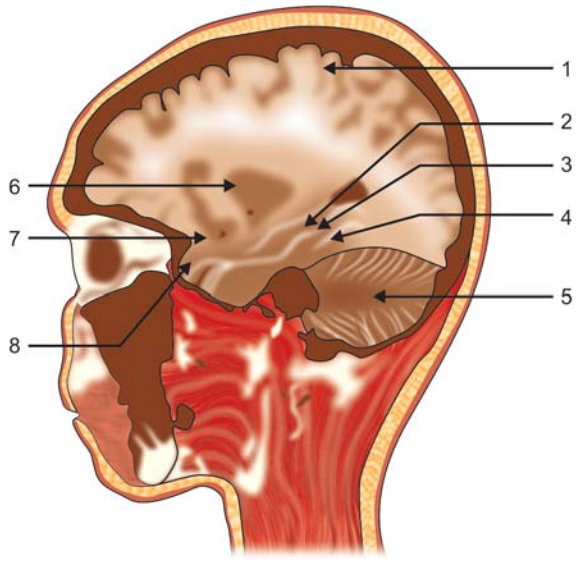

Figure 1.15

1. Central sulcus
2. Hippocampus
3. Parahippocampal gyrus
4. Occipitotemporal gyrus
5. Cerebellar hemisphere
6. Putamen
7. Stem of lateral sulcus
8. Superior temporal gyrus

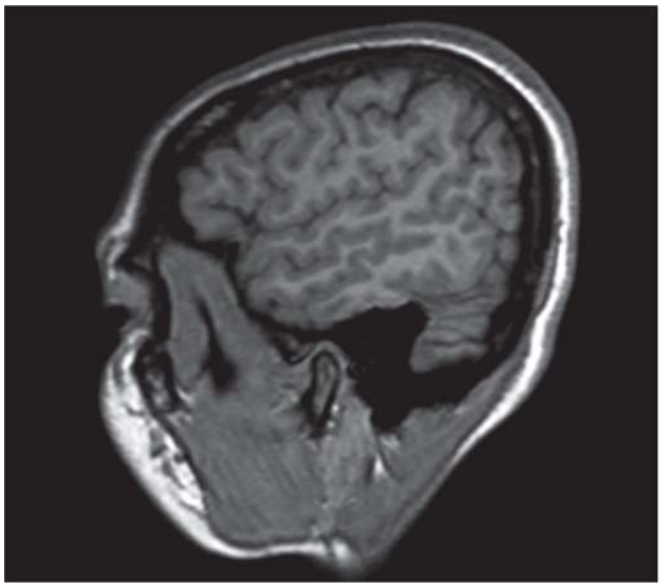

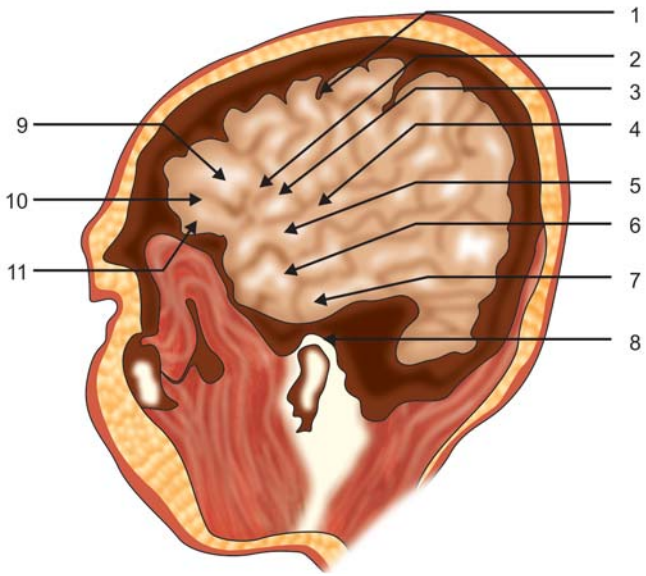

Figure 1.16

1. Central sulcus
2. Ascending ramus-lateral sulcus
3. Pars opercularis
4. Lateral sulcus
5. Superior temporal gyrus
6. Middle temporal gyrus
7. Inferior temporal gyrus
8. TM joint
9. Pars triangularis
10. Anterior ramus-lateral sulcus
11. Pars orbitalis

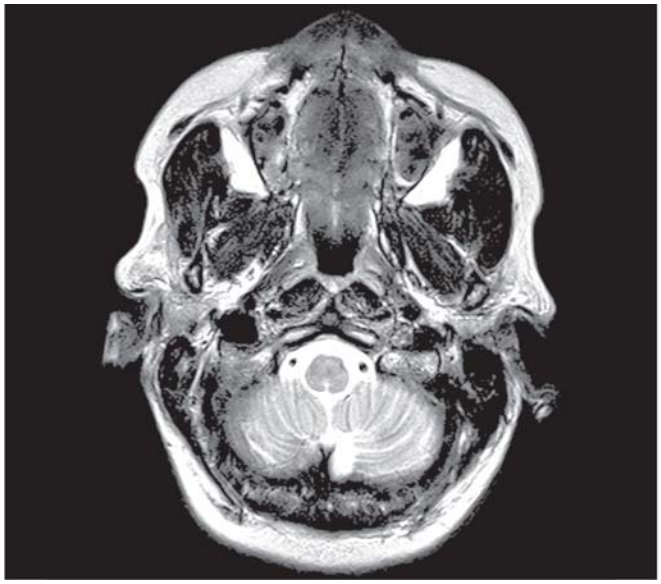

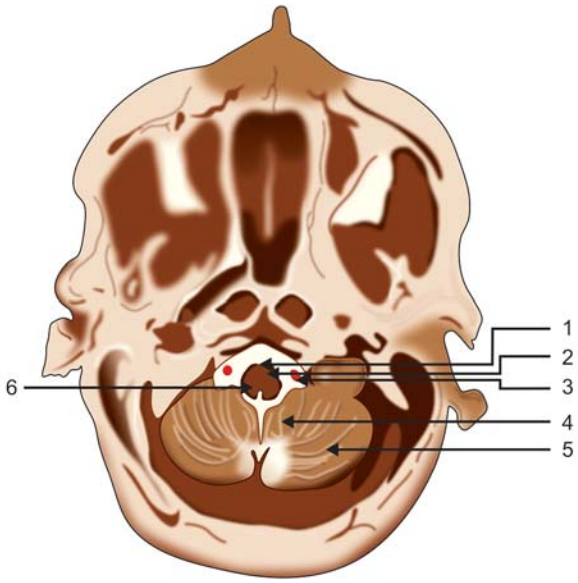

Figure 1.17

1. Median sulcus of medulla
2. Pyramid
3. Vertebral artery
4. Tonsil
5. Cerebellum
6. Medulla

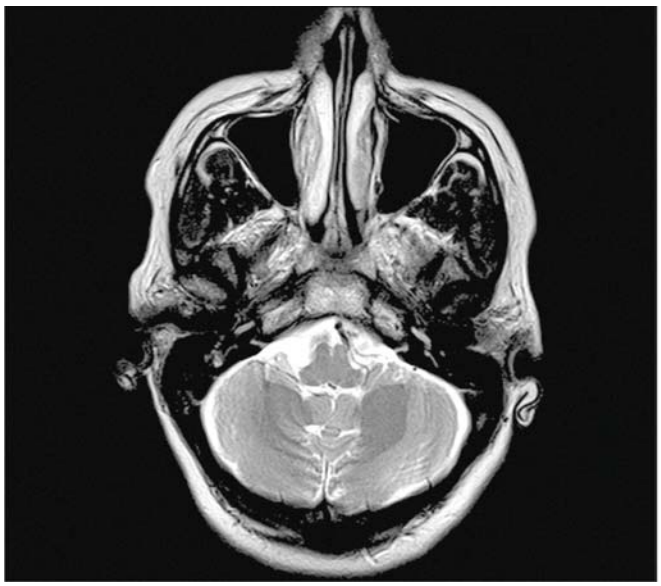

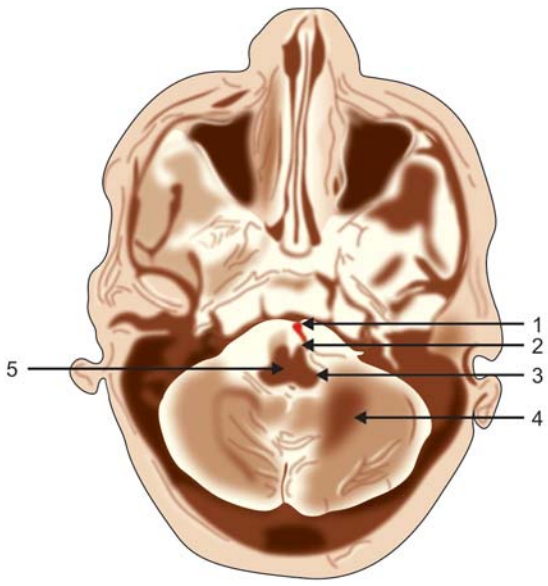

Figure 1.18

1. Basilar artery
2. Pyramid
3. Inferior cerebellar peduncle
4. Cerebellar white matter
5. Medulla

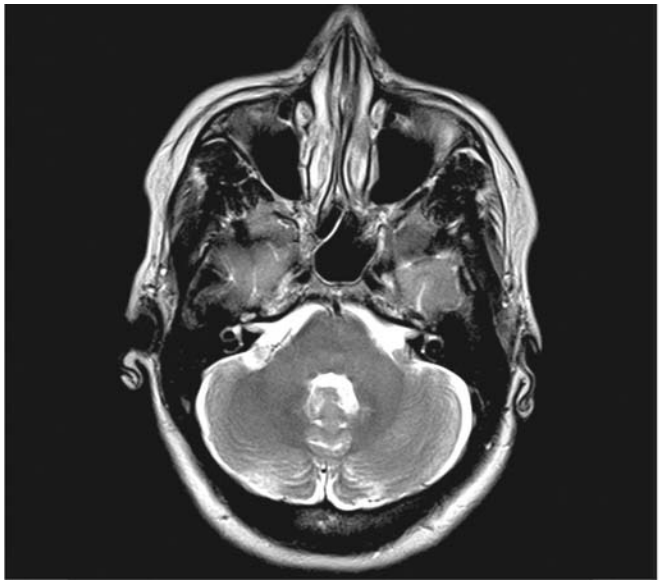

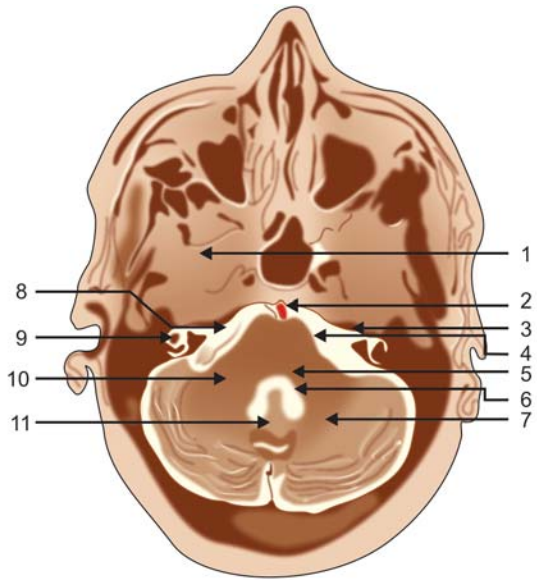

Figure 1.19

1. Temporal lobe
2. Basilar artery
3. Internal auditory canal
4. Pons
5. Medial longitudinal fasciculus
6. Fourth ventricle
7. Cerebellar white matter
8. Cerebellopontine cistern
9. Semicircular canals
10. Middle cerebellar peduncle
11. Vermis

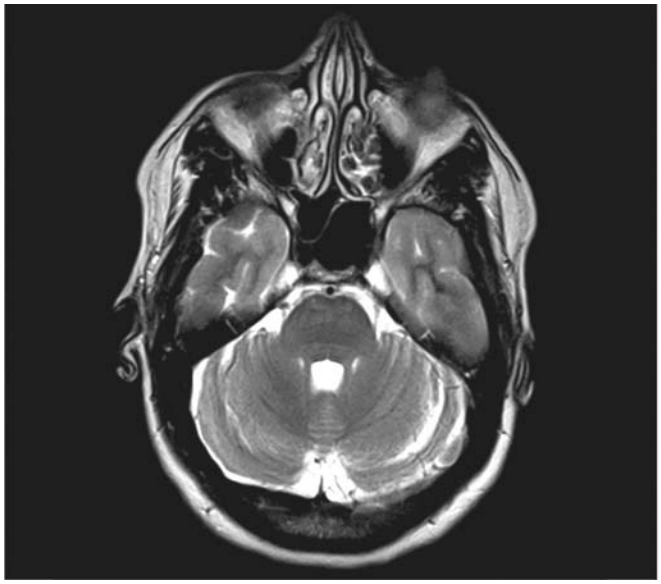

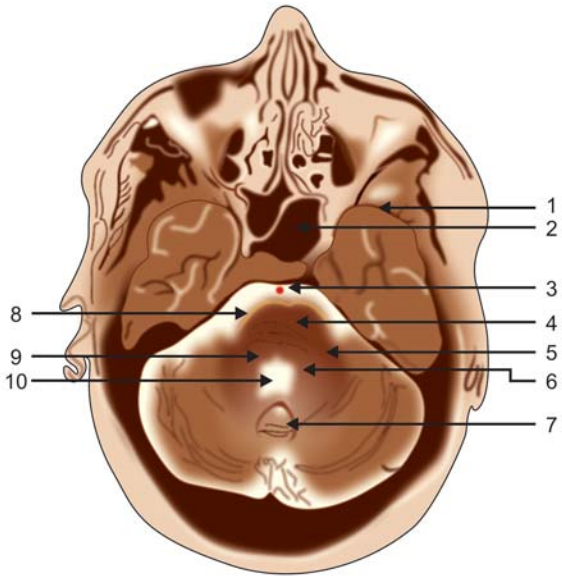

Figure 1.20

1. Temporal pole
2. Sphenoid sinus
3. Basilar artery
4. Pons
5. Middle cerebellar peduncle
6. Superior cerebellar peduncle
7. Cerebellar vermis
8. Trigeminal nerve
9. Medial longitudinal fasciculus
10. Fourth ventricle



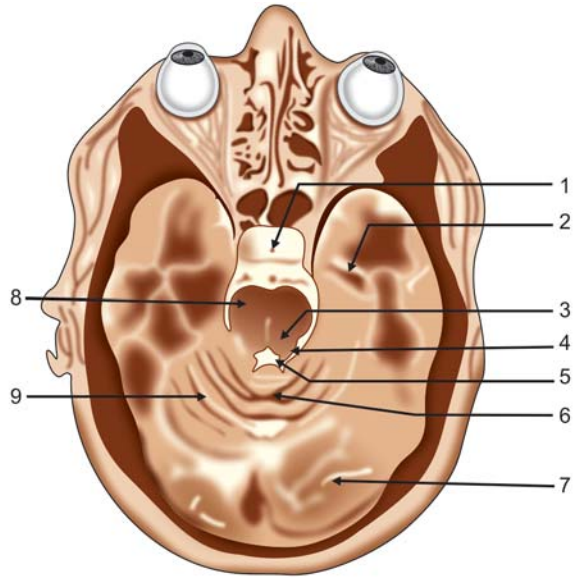

Figure 1.21

1. Pituitary stalk
2. Temporal horn of lateral ventricle
3. Medial longitudinal fasciculus
4. Superior cerebellar peduncle
5. Fourth ventricle
6. Vermis
7. Occipital lobe
8. Pons
9. Cerebellum



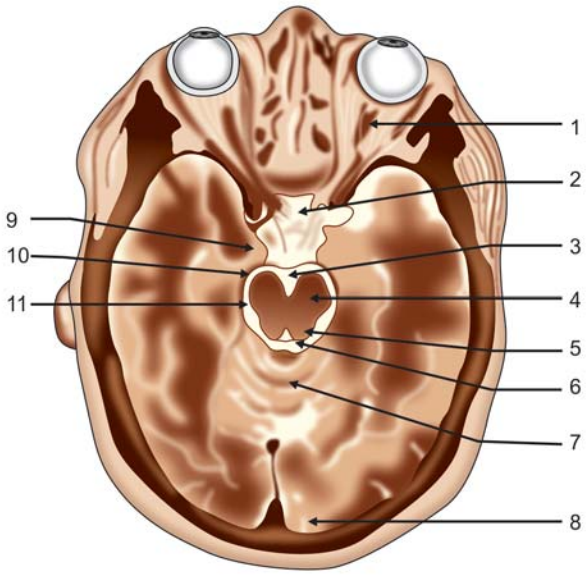

Figure 1.22

1. Optic nerve
2. Suprasellar cistern
3. Interpeduncular fossa
4. Cerebral peduncle
5. Inferior colliculus
6. Quadrigeminal plate cistern
7. Superior vermis
8. Occipital pole
9. Uncus
10. Posterior cerebellar artery
11. Ambient cistern

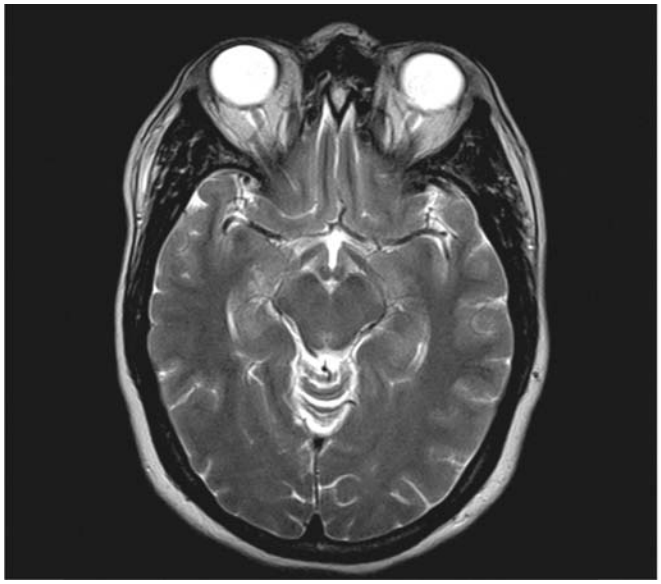

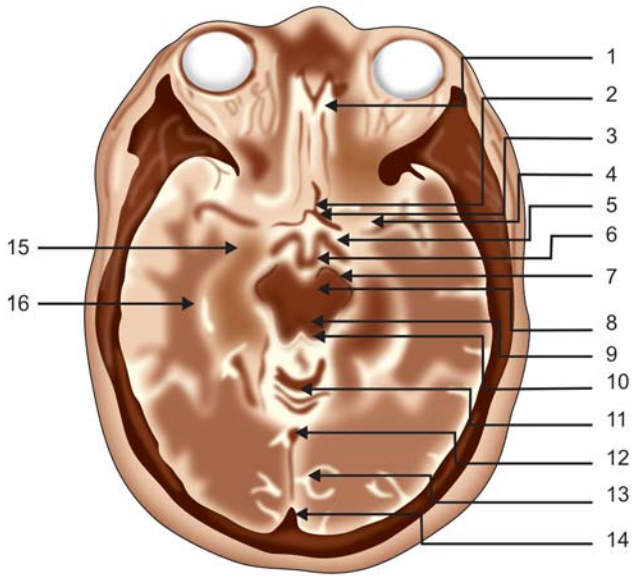

Figure 1.23

1. Gyrus rectus
2. Ant communicating artery
3. Ant cerebral artery
4. Middle cerebral artery
5. Optic tract
6. Mammillary body
7. Crus cerebri
8. Red nucleus
9. Aqueduct of sylvius
10. Superior colliculus
11. Superior vermis
12. Straight sinus
13. Calcarine sulcus
14. Superior sagittal sinus
15. Uncus
16. Temporal horn

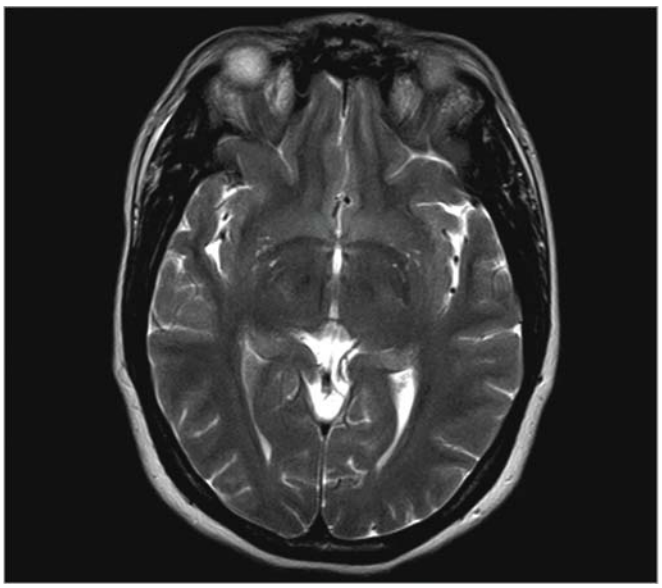

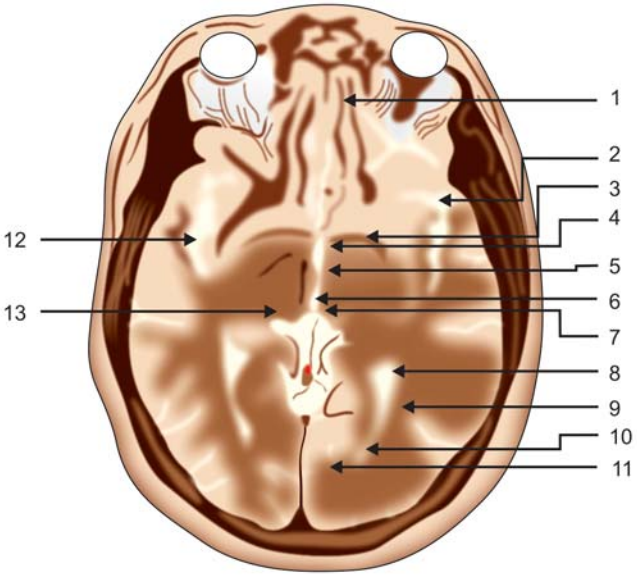

Figure 1.24

1. Gyrus rectus
2. Sylvian (lateral) fissure
3. Anterior commissure
4. Fornix
5. Mammillothalamic tract
6. Third ventricle
7. Posterior commissure
8. Atrium of lateral ventricle
9. Optic radiation
10. Occipital horn
11. Calcarine fissure
12. Insula
13. Pulvinar

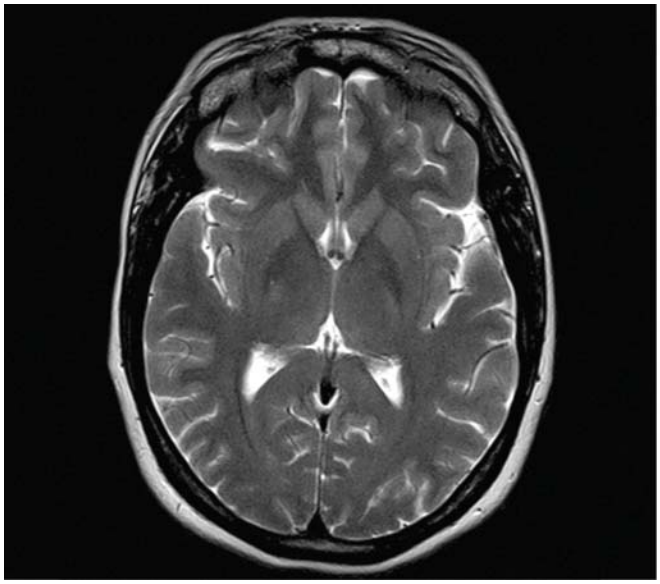

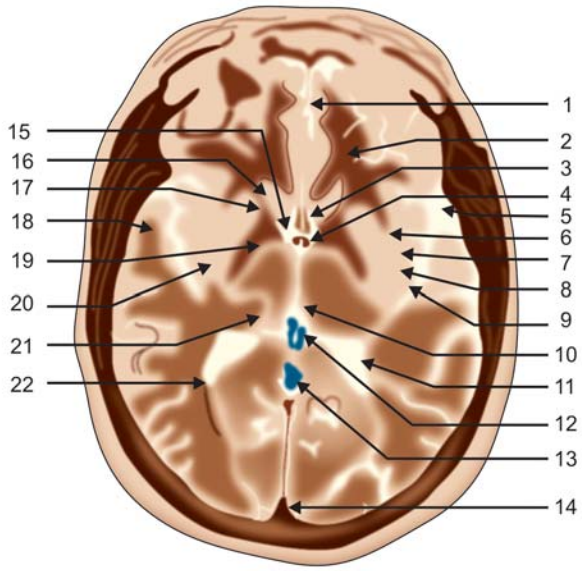

Figure 1.25

1. Anterior interhemispheric fissure
2. Forceps minor
3. Septum pellucidum
4. Fornix
5. Sylvian fissure
6. External capsule
7. Claustrum
8. Extreme capsule
9. Insular cortex
10. Stria medullaris thalami
11. Atrium of lateral ventricle
12. Internal cerebral veins
13. Vein of Galen
14. Superior sagittal sinus
15. Foramen of Monroe
16. Caudate nucleus
17. Internal capsule ant.limb
18. Temporal operculum
19. Globus pallidus
20. Putamen
21. Pulvinar of thalamus
22. Optic radiation

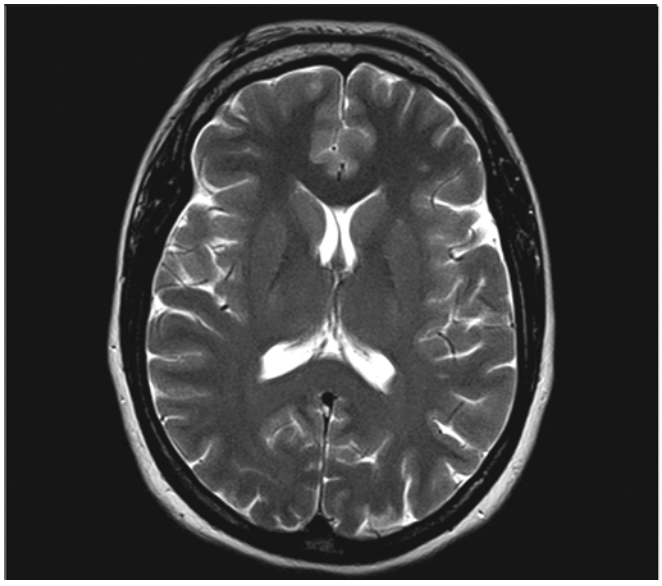

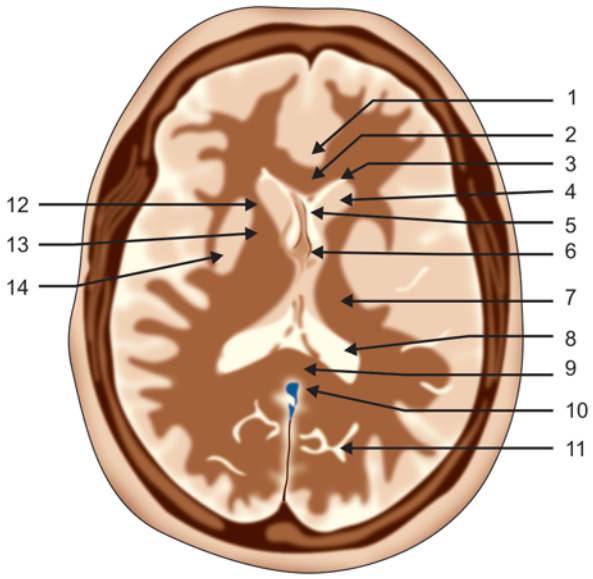

Figure 1.26

1. ACA branches
2. Genu of corpus callosum
3. Frontal horn of lateral ventricle
4. Head of caudate nucleus
5. Septum pellucidum
6. Fornix
7. Thalamus
8. Tail of caudate nucleus
9. Splenium of corpus callosum
10. Vein of Galen
11. Parieto-occipital sulcus
12. Anterior limb of internal capsule
13. Globus pallidus
14. Putamen

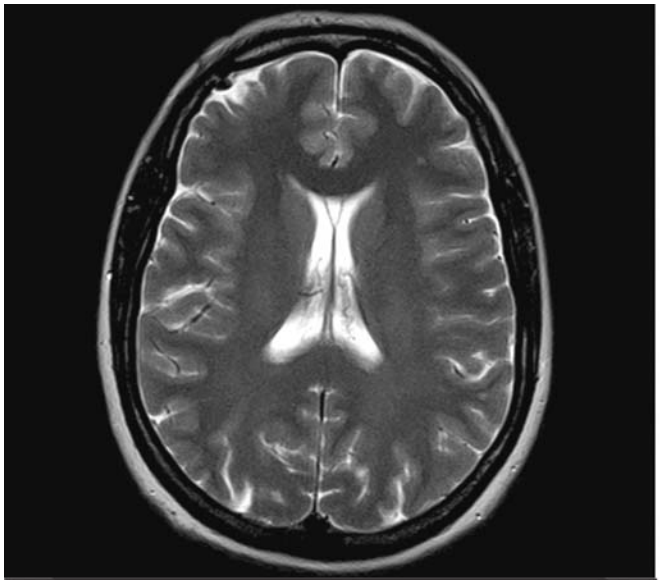

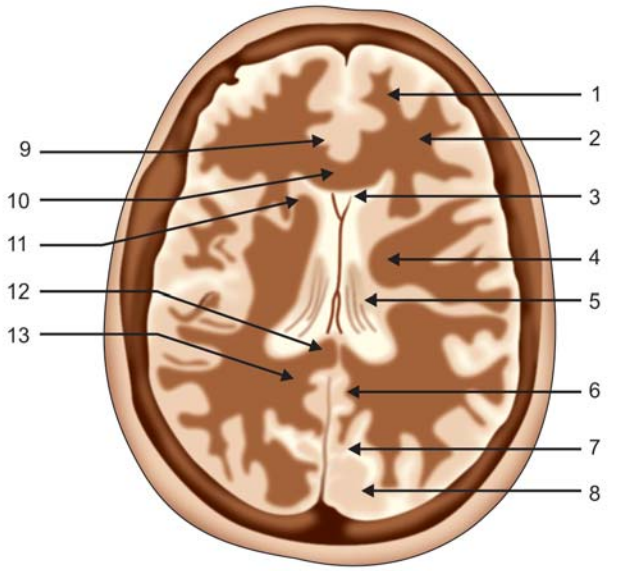

Figure 1.27

1. Superior frontal gyrus
2. Middle frontal gyrus
3. Septum pellucidum
4. Corona radiata
5. Body of lateral ventricle
6. Cingulate gyrus
7. Parieto-occipital sulcus
8. Occipital lobe
9. Cingulate gyrus
10. Genu of corpus callosum
11. Caudate nucleus head
12. Splenium corpus callosum
13. Forceps major

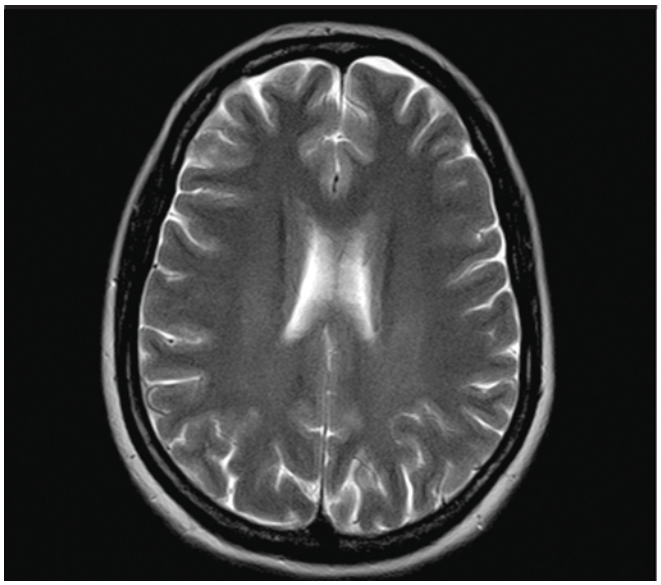

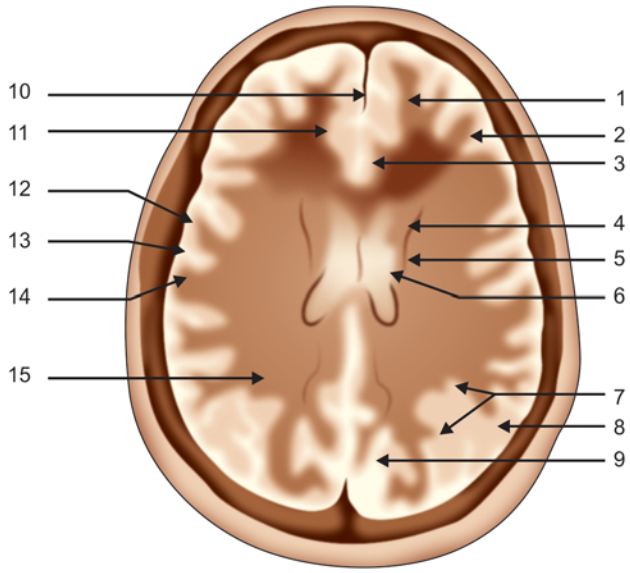

Figure 1.28

1. Superior frontal gyrus
2. Middle frontal gyrus
3. Cingulate gyrus
4. Body of caudate nucleus
5. Corona radiata
6. Lateral ventricle
7. Intraparietal sulcus
8. Inferior parietal lobule
9. Parieto-occipital sulcus
10. Interhemispheric fissure
11. Cingulate sulcus
12. Precentral gyrus
13. Central sulcus
14. Postcentral gyrus
15. Superior parietal lobule

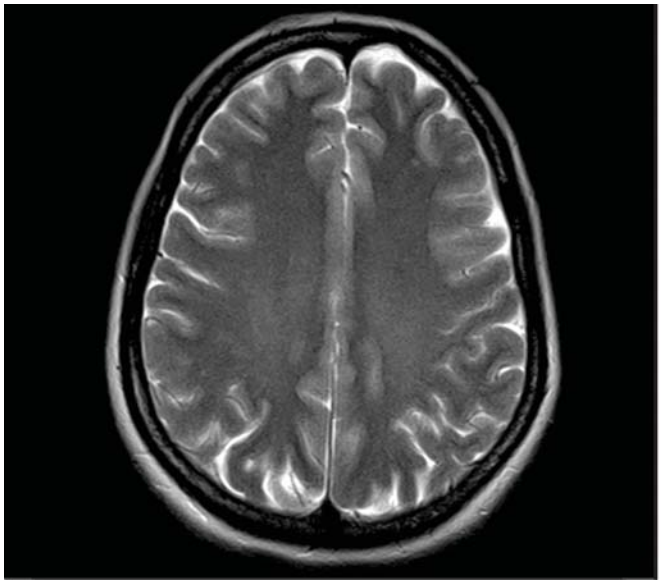

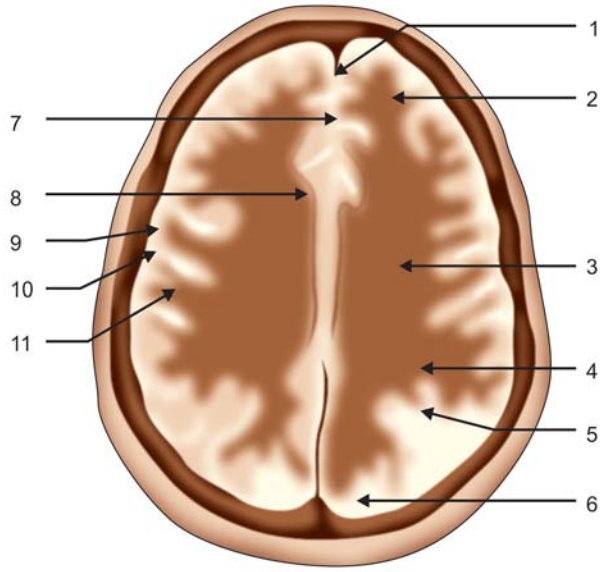

Figure 1.29

1. Interhemispheric fissure
2. Superior frontal gyrus
3. Centrum semiovale
4. Superior parietal lobule
5. Intraparietal sulcus
6. Parieto-occipital sulcus
7. Cingulate sulcus
8. Cingulate gyrus
9. Precentral gyrus
10. Central sulcus
11. Postcentral gyrus

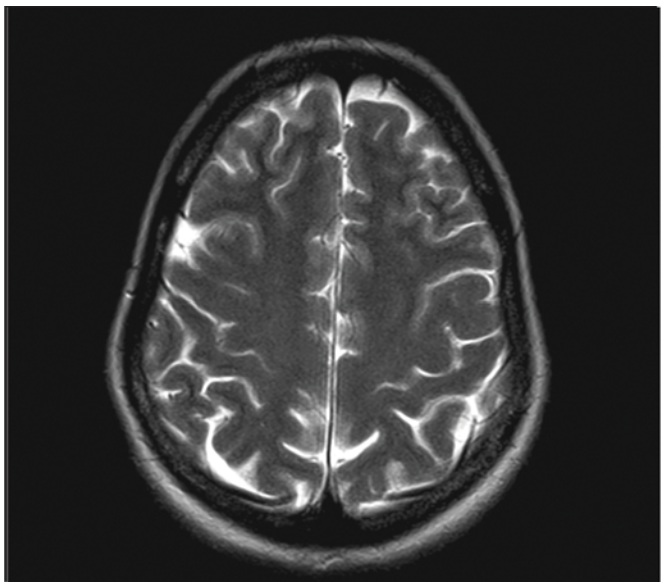

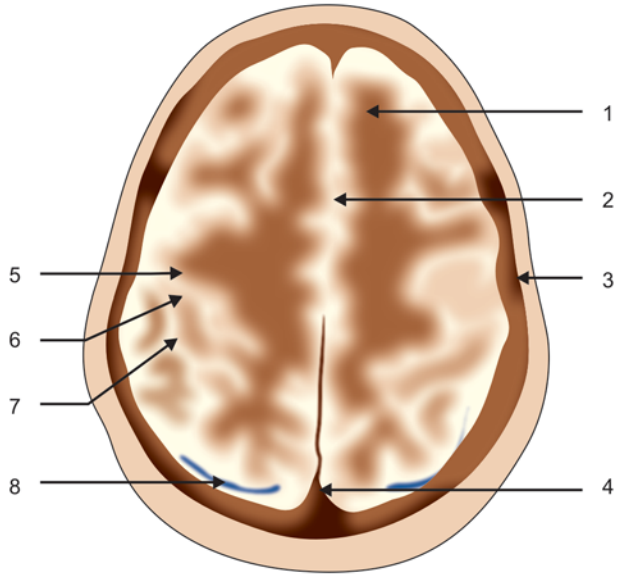

Figure 1.30

1. Superior frontal gyrus
2. Interhemispheric fissure
3. Diploic space
4. Superior sagittal sinus
5. Precentral gyrus
6. Central sulcus
7. Postcentral gyrus
8. Cortical vein

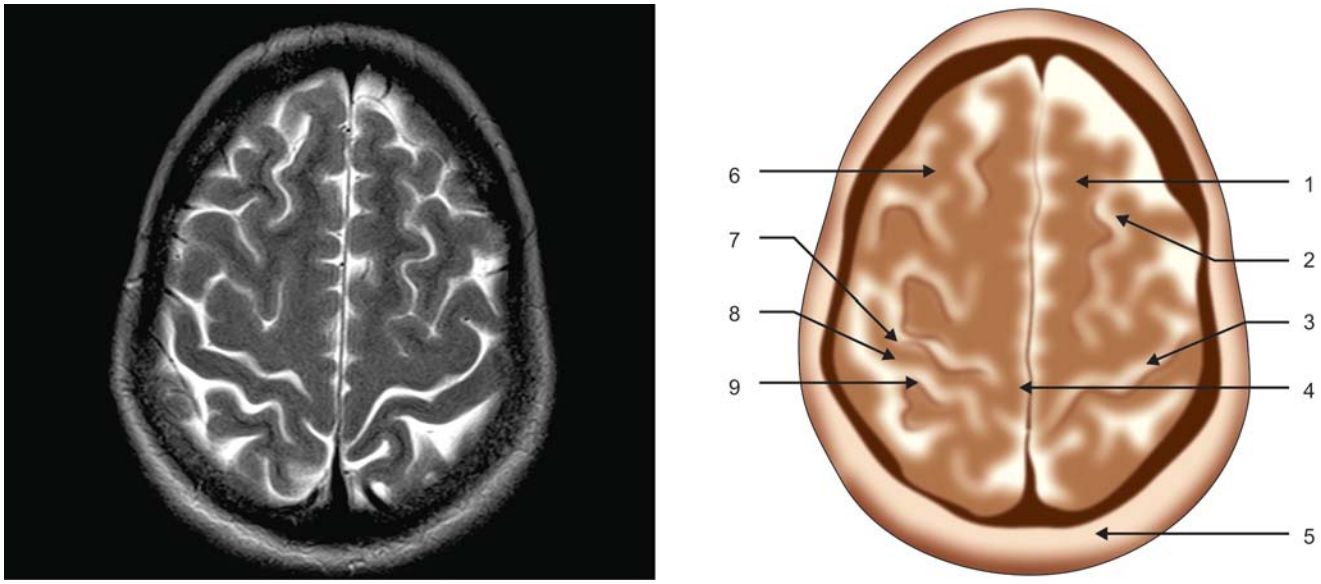

Figure 1.31

1. Superior frontal gyrus
2. Superior frontal sulcus
3. Central sulcus
4. Paracentral lobule
5. Scalp
6. Middle frontal gyrus
7. Central sulcus
8. Postcentral gyrus
9. Postcentral sulcus

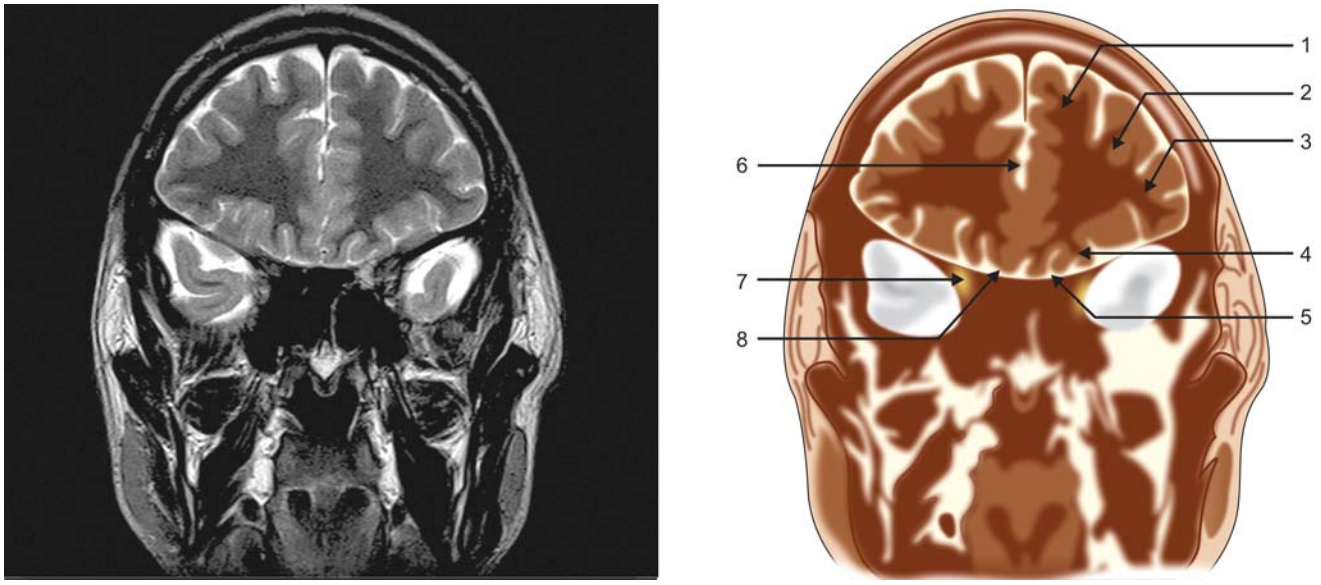

Figure 1.32

1. Superior frontal gyrus
2. Middle frontal gyrus
3. Inferior frontal gyrus
4. Orbital gyri
5. Olfactory sulcus
6. Interhemispheric fissure
7. Optic nerve
8. Gyrus rectus

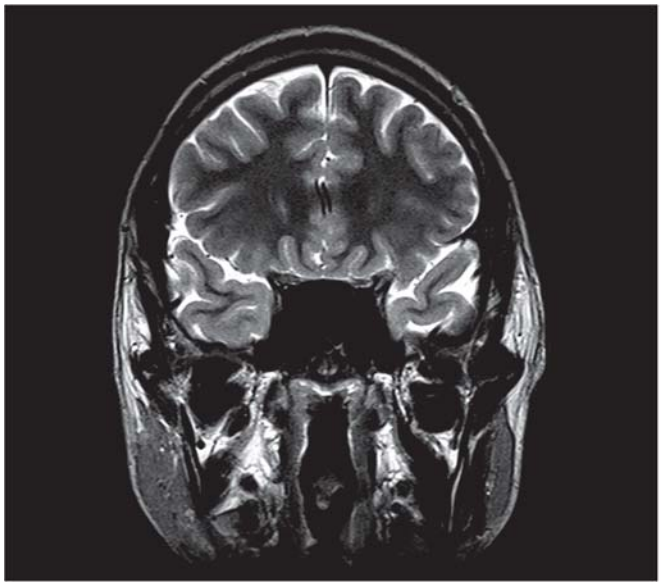

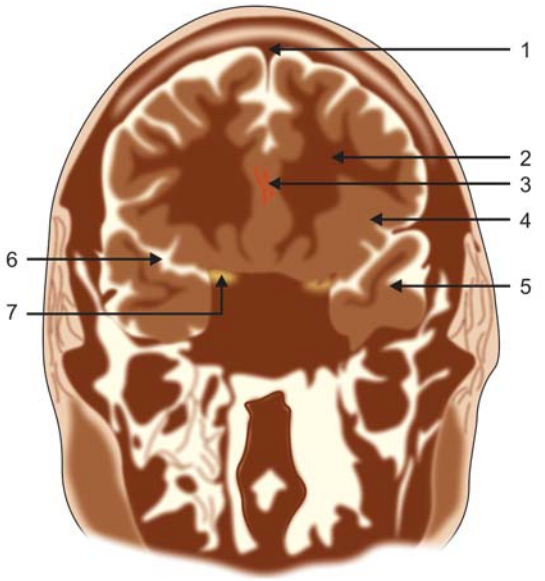

Figure 1.33

1. Superior sagittal sinus
2. Forceps minor
3. Anterior cerebral artery
4. Frontal operculum
5. Temporal lobe
6. Sylvian fissure, stem
7. Optic nerve

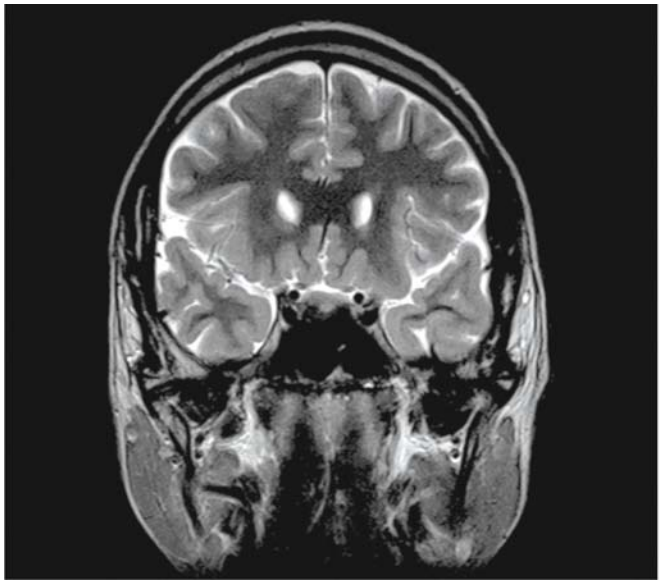

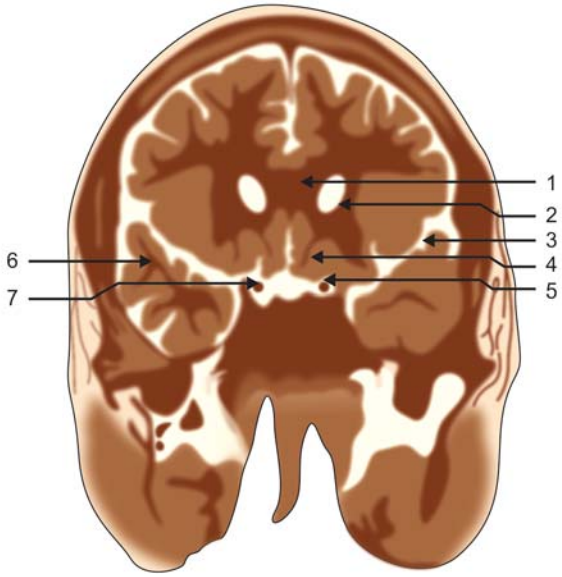

Figure 1.34

1. Genu of corpus callosum
2. Frontal horn of lateral ventricle
3. Sylvian fissure
4. Gyrus rectus
5. Optic nerve
6. Temporal operculum
7. ICA

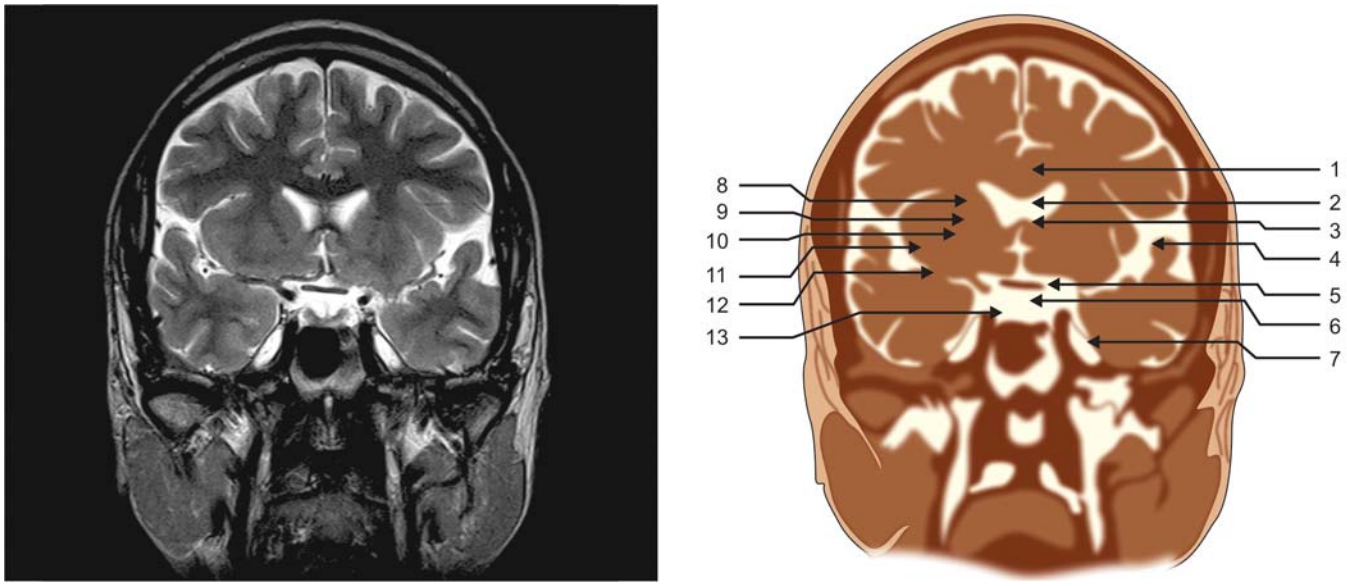

Figure 1.35

1. Pericallosal artery
2. Septum pellucidum
3. Rostrum of corpus callosum
4. Sylvian fissure
5. Optic chiasm
6. Suprasellar cistern
7. Meckel's cave
8. Caudate nucleus head
9. Internal capsule
10. Putamen
11. Insula
12. MCA
13. Pituitary gland

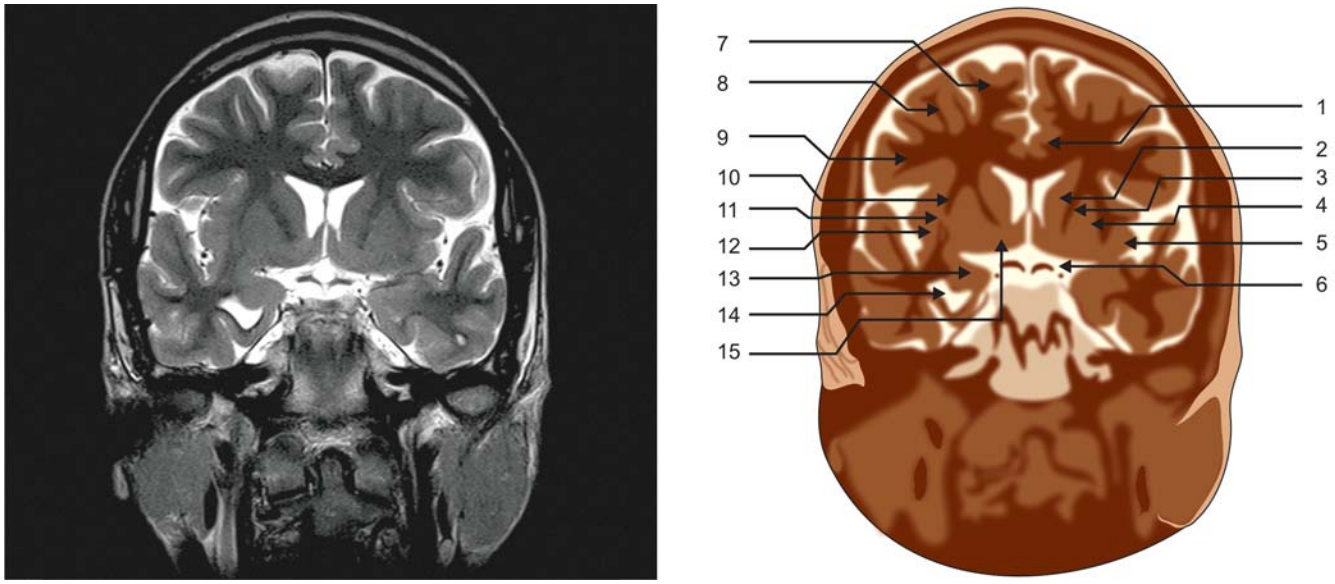

Figure 1.36

1. Cingulate gyrus
2. Caudate nucleus
3. Internal capsule
4. Putamen
5. Insula
6. Optic tract
7. Superior frontal gyrus
8. Middle frontal gyrus
9. Inferior frontal gyrus
10. External capsule
11. Claustrum
12. External capsule
13. Uncus
14. Temporal horn
15. Fundus striati

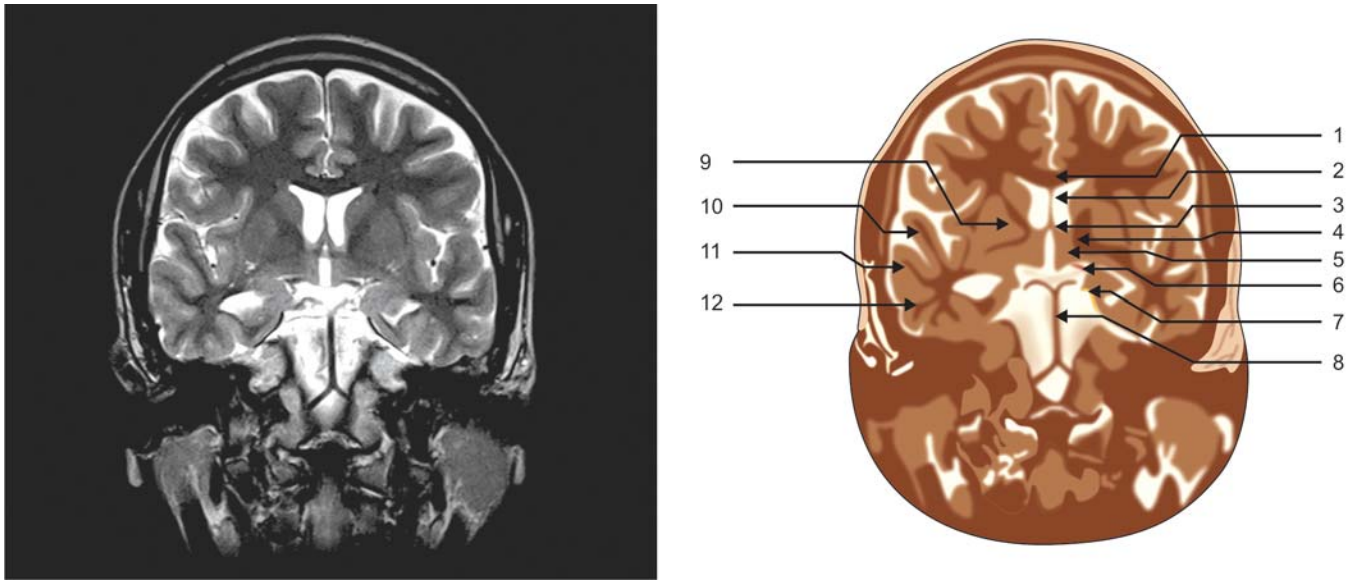

Figure 1.37

1. Corpus callosum body
2. Septum pellucidum
3. Fornix
4. Anterior commissure
5. Innominate substance
6. Optic tract
7. Oculomotor nerve
8. Basilar artery
9. Globus pallidus
10. Superior temporal gyrus
11. Middle temporal gyrus
12. Inferior temporal gyrus

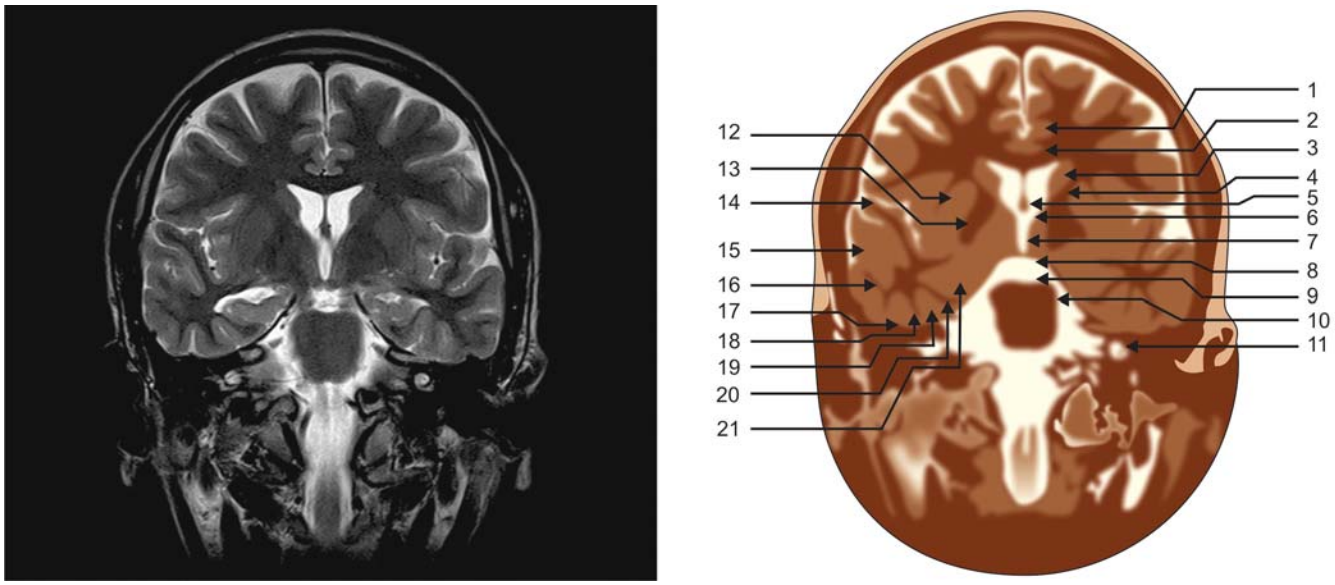

Figure 1.38

1. Cingulate sulcus
2. Pericallosal sulcus
3. Caudate nucleus
4. Internal capsule
5. Fornix
6. Foramen of Monro
7. Third ventricle
8. Mammillary body
9. Interpeduncular cistern
10. Pons
11. Cochlea
12. Putamen
13. Globus pallidus
14. Superior temporal gyrus
15. Middle temporal gyrus
16. Inferior temporal gyrus
17. Occipitotemporal sulcus
18. Occipitotemporal gyrus
19. Collateral sulcus
20. Parahippocampal
21. Hippocampus

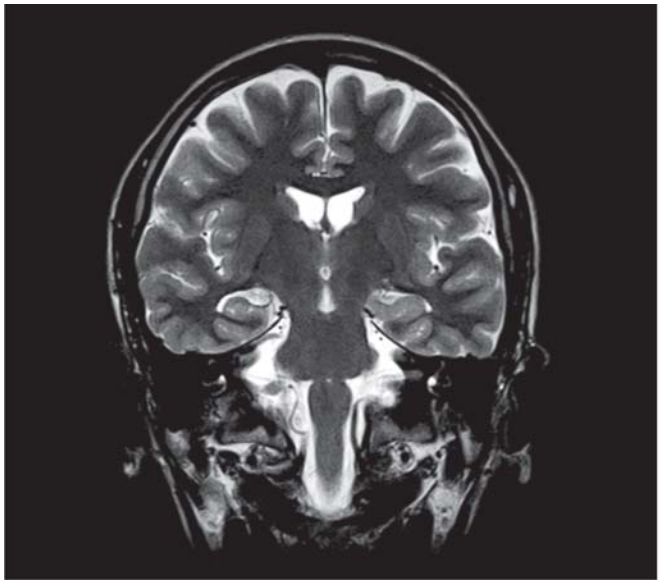

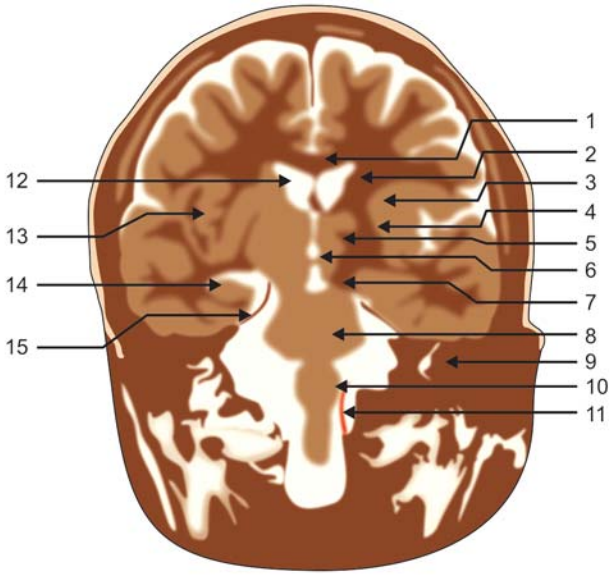

Figure 1.39

1. Corpus callosum
2. Caudate nucleus
3. Putamen
4. Internal capsule
5. Thalamus
6. Third ventricle
7. Cerebral peduncle
8. Pons
9. Vestibule
10. Medulla
11. Vertebral artery
12. Lateral ventricle
13. Insula
14. Hippocampus
15. Tentorium

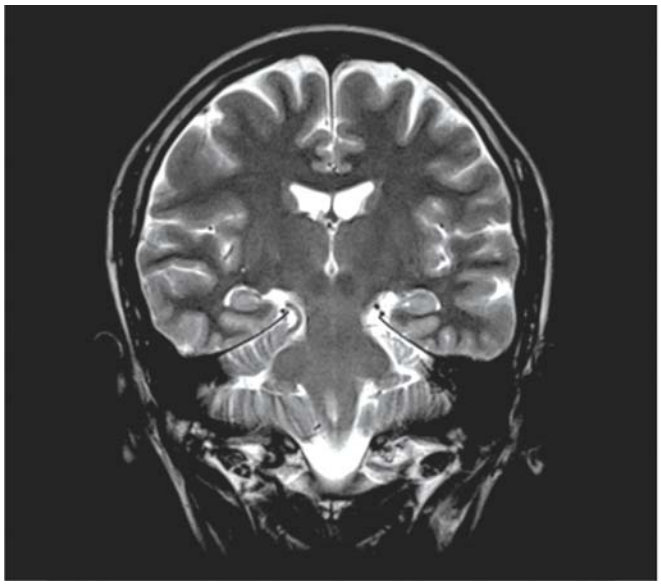

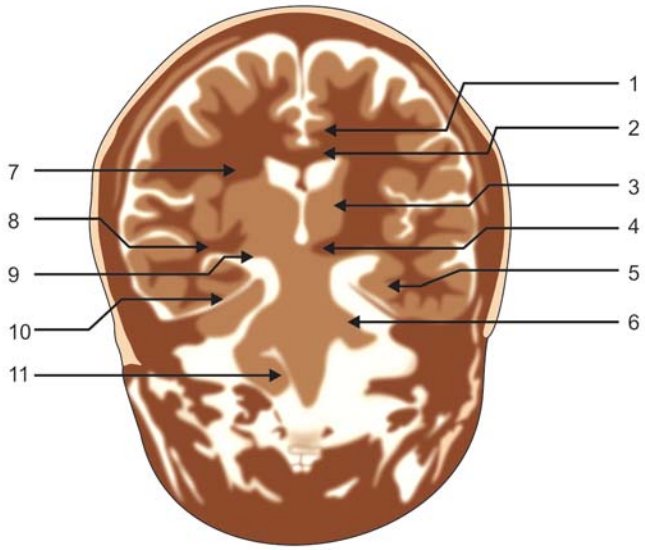

Figure 1.40

1. Cingulate gyrus
2. Corpus callosum
3. Thalamus
4. Red nucleus
5. Parahippocampal gyrus
6. Middle cerebellar peduncle
7. Corona radiata
8. Lateral geniculate body
9. Medial geniculate body
10. Tentorium cerebelli
11. Inferior cerebellar peduncle

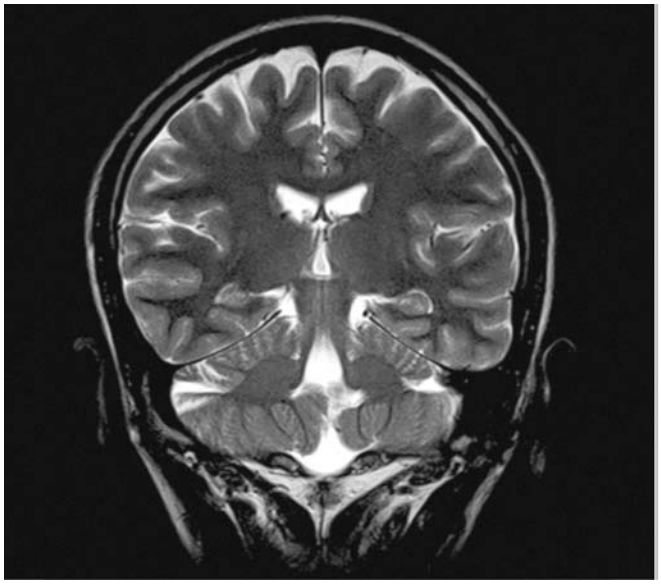

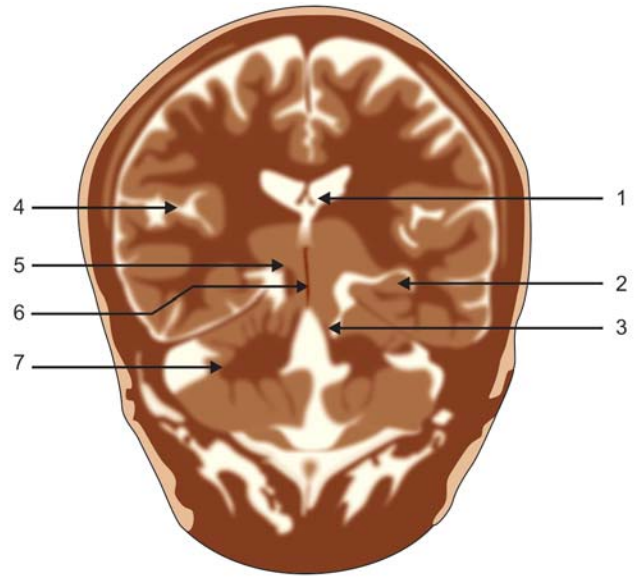

Figure 1.41

1. Fornix
2. Hippocampus body
3. Superior cerebellar peduncle
4. Sylvian fissure
5. Superior colliculus
6. Aqueduct of sylvius
7. Cerebellum

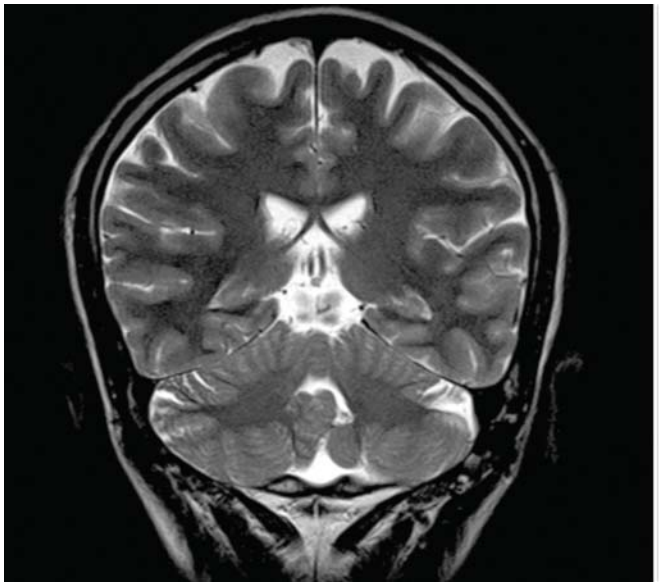

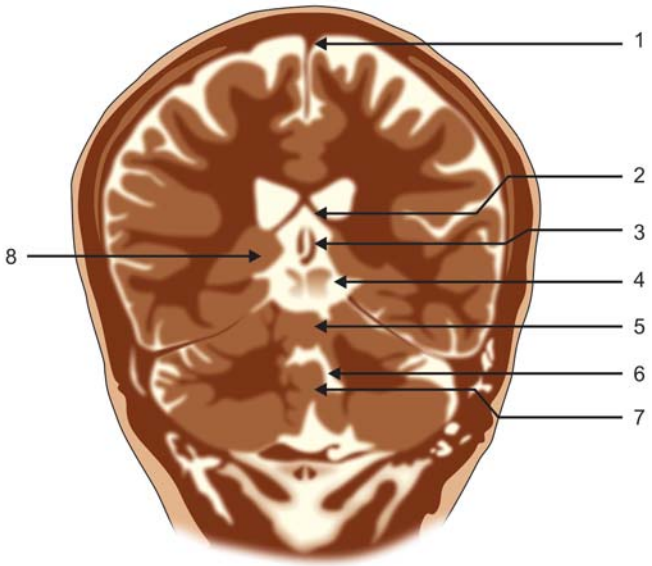

Figure 1.42

1. Superior sagittal sinus
2. Fornix
3. Internal cerebral vein
4. Quadrigeminal plate cistern
5. Vermis
6. Fourth ventricle
7. Nodule of cerebellum
8. Pulvinar of thalamus

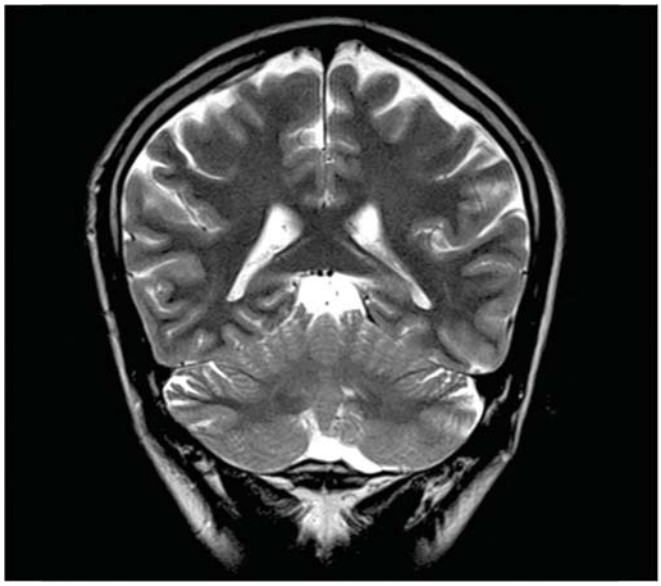

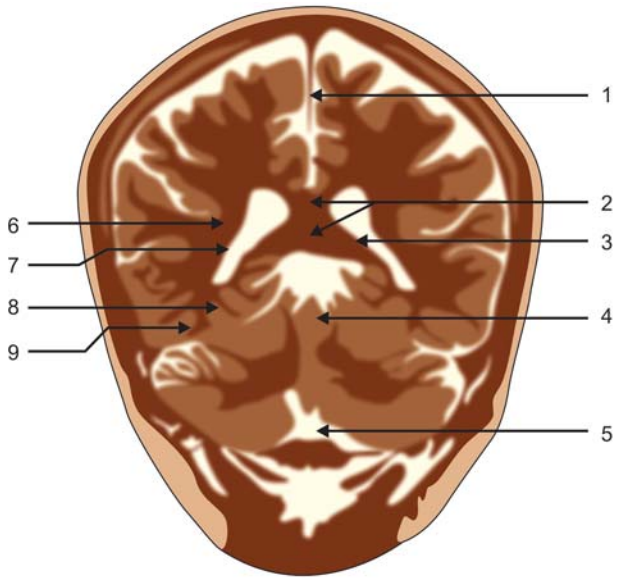

Figure 1.43

1. Interhemispheric fissure
2. Splenium of corpus callosum
3. Fornix
4. Vermis
5. Cisterna magna
6. Optic radiation
7. Atrium of lateral ventricle
8. Lingular gyrus
9. Fusiform gyrus

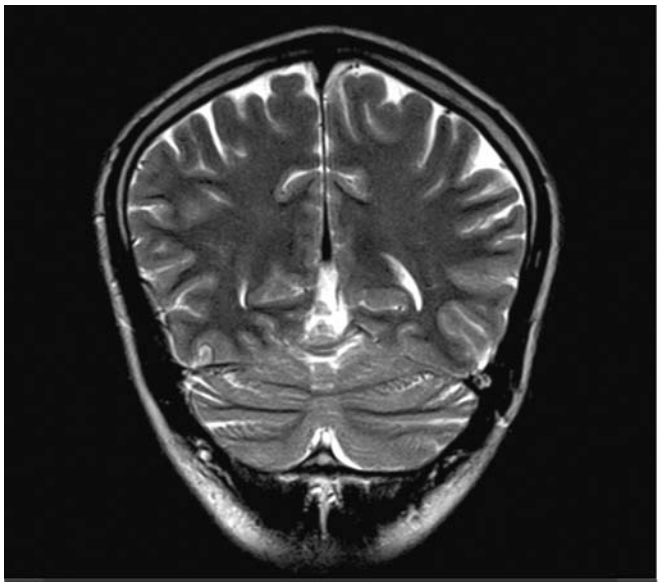

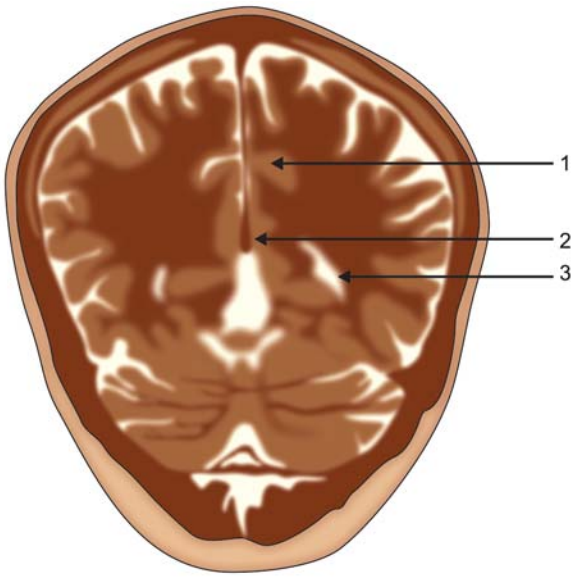

Figure 1.44

1. Cingulate sulcus, marginal branch
2. Straight sinus
3. Occipital horn

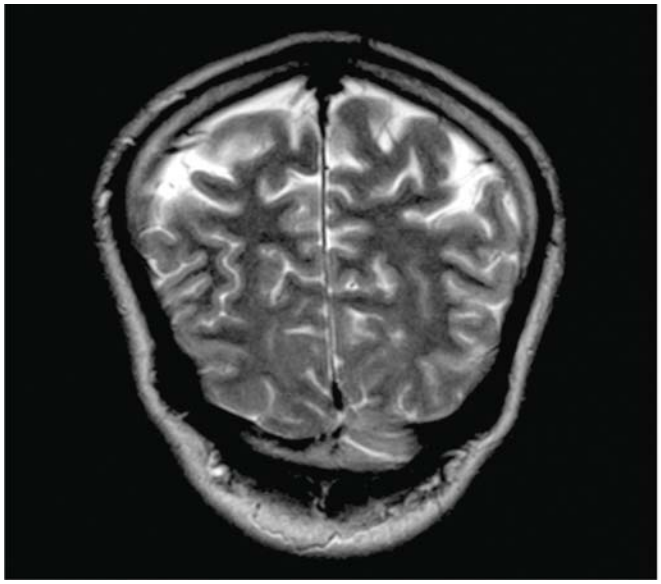

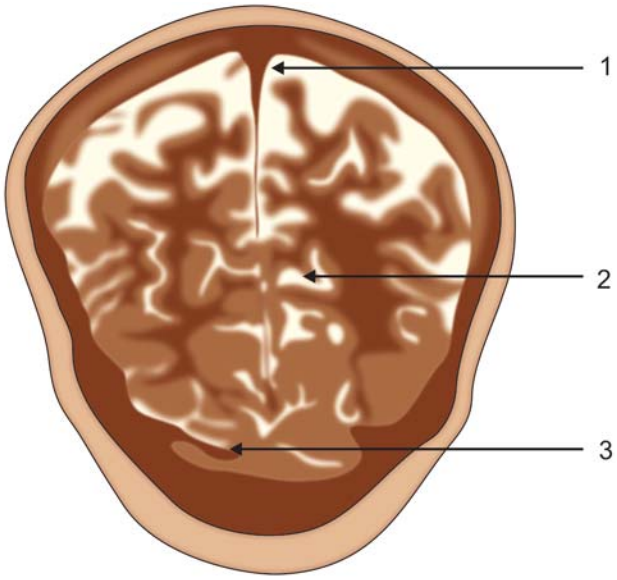

Figure 1.45

1. Superior sagittal sinus
2. Calcarine sulcus
3. Transverse sinus

CHAPTER 2

Orbit

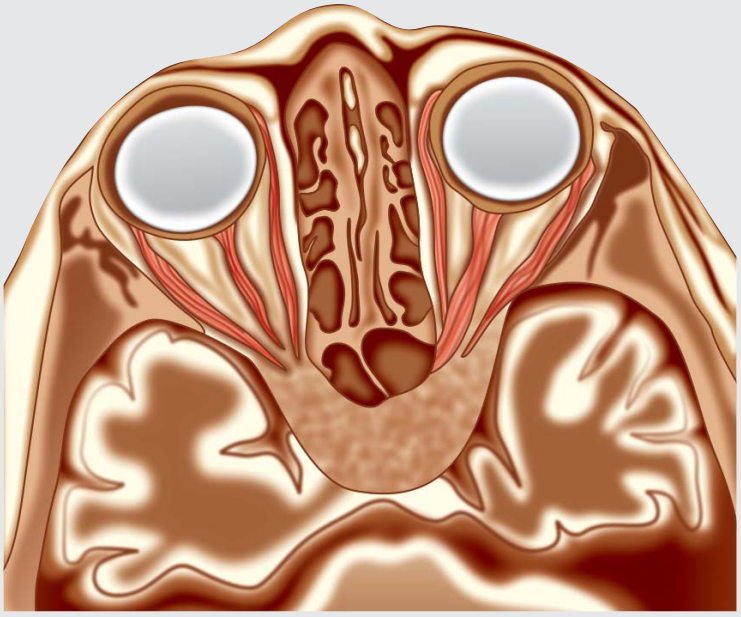

AXIAL IMAGES: INFERIOR TO SUPERIOR

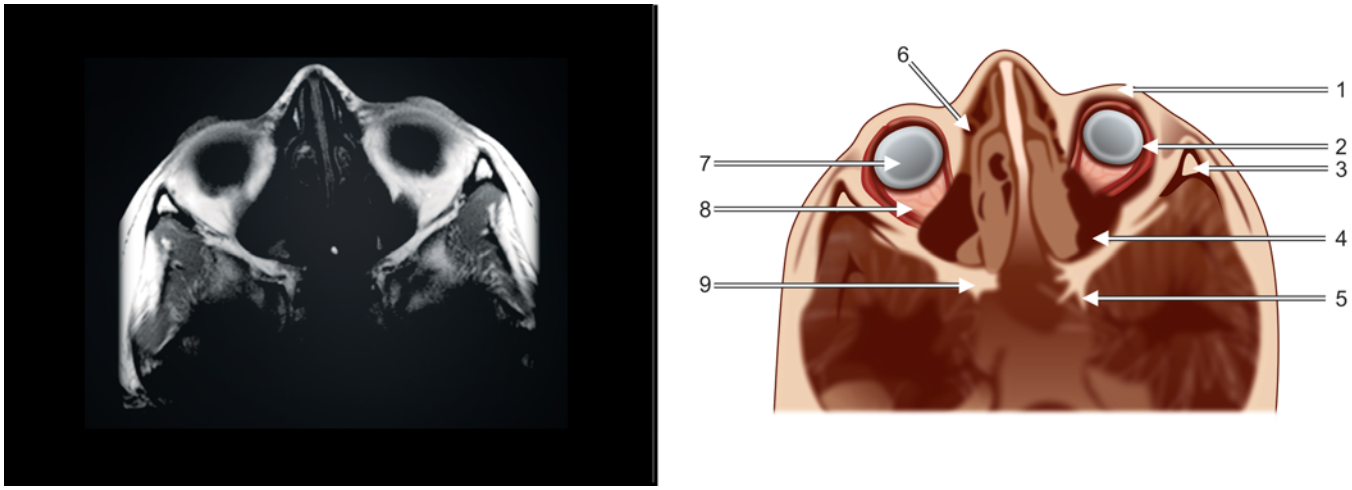

Figure 2.1

1. Lower eyelid
2. Insertion of inferior oblique
3. Zygoma
4. Maxillary sinus
5. Vidian canal
6. Nasolacrimal duct
7. Eyeball
8. Inferior rectus
9. Pterygopalatine fossa

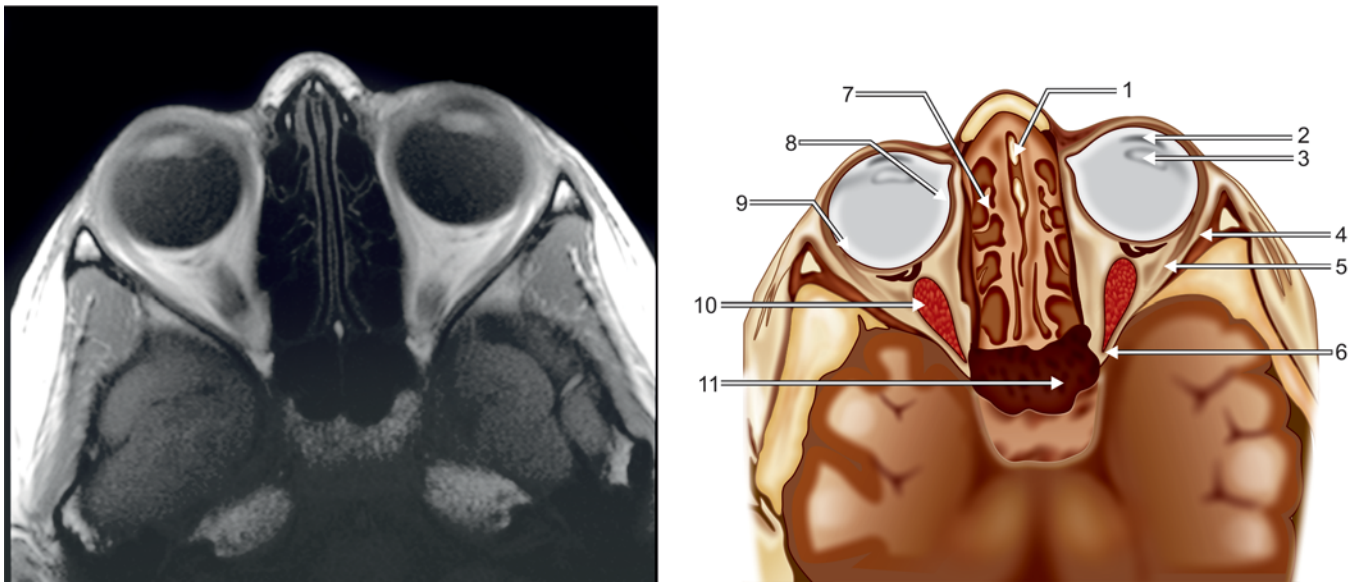

Figure 2.2

1. Nasal septum
2. Anterior chamber
3. Lens
4. Extraconal fat
5. Lateral rectus
6. Superior orbital fissure
7. Ethmoid air cells
8. Medial rectus
9. Sclera
10. Inferior rectus
11. Sphenoid sinus

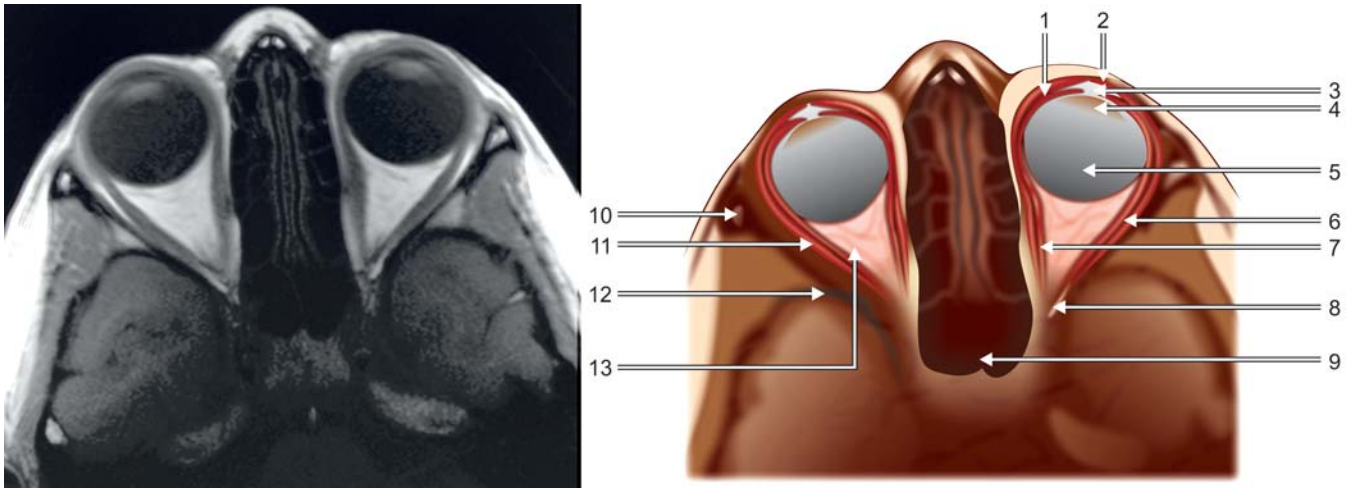

Figure 2.3

1. Ciliary body
2. Cornea
3. Anterior chamber
4. Lens
5. Vitreous
6. Lateral rectus
7. Medial rectus
8. Superior orbit fissure
9. Sphenoid sinus
10. Zygoma
11. Extraconal fat
12. Greater wing of sphenoid
13. Intraconal fat

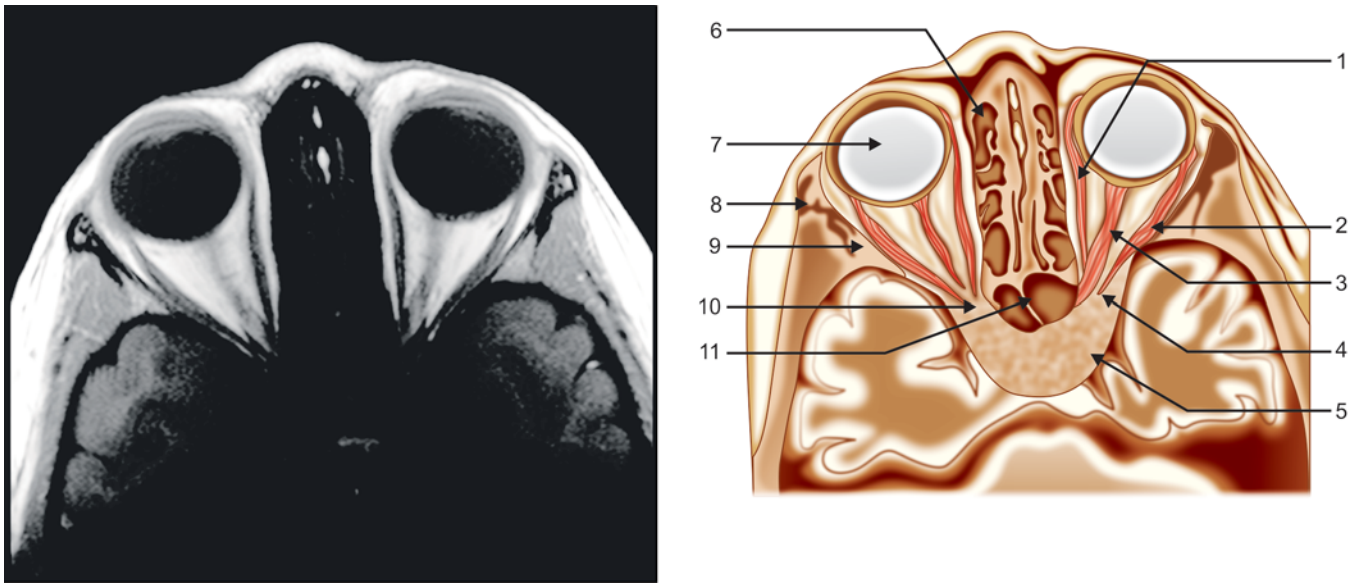

Figure 2.4

1. Medial rectus
2. Lateral rectus
3. Optic nerve
4. Superior orbit fissure
5. Internal carotid artery
6. Ethmoid air cells
7. Vitreous
8. Zygomatic bone
9. Lateral wall, orbit
10. Optic canal
11. Sphenoid sinus

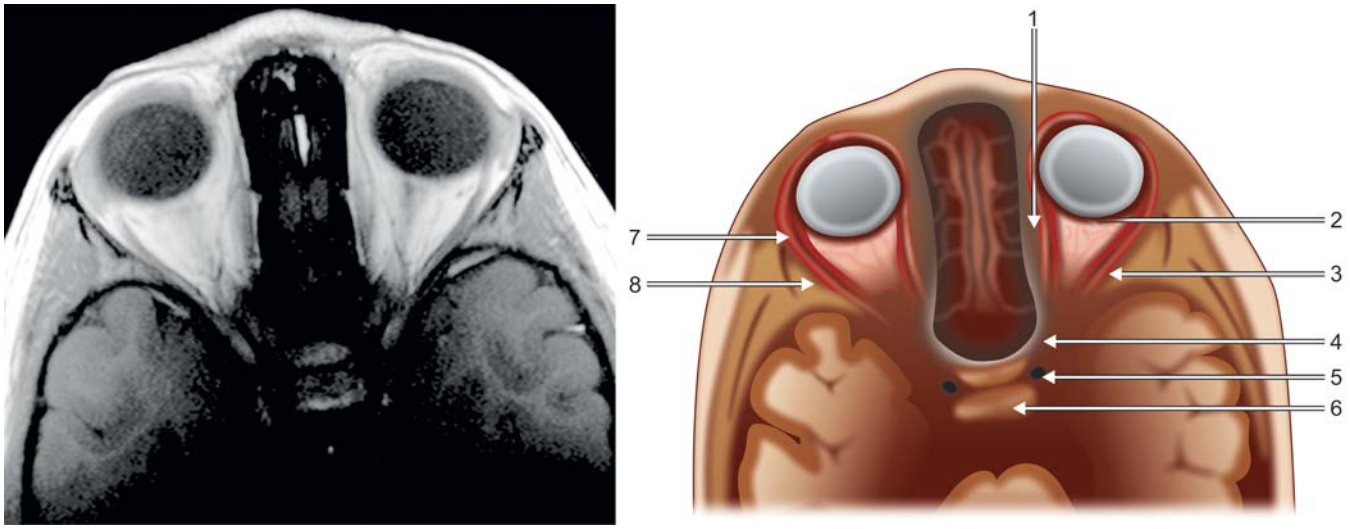

Figure 2.5

1. Superior rectus
2. Optic disk
3. Lateral rectus
4. Optic nerve
5. ICA
6. Sella
7. Lacrimal gland
8. Lateral wall, orbit

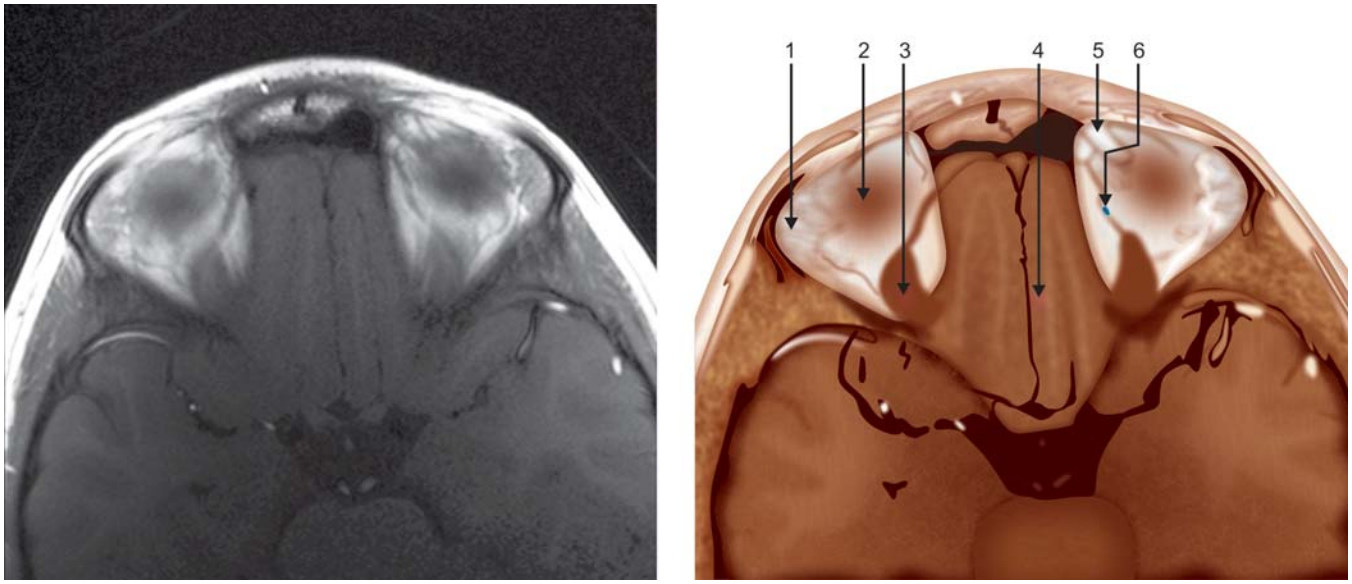

Figure 2.6

1. Lacrimal gland
2. Globe, superior part
3. Superior rectus
4. Gyrus rectus
5. Reflected tendon of superior oblique
6. Superior ophthalmic vein

CORONAL IMAGES: POSTERIOR TO ANTERIOR

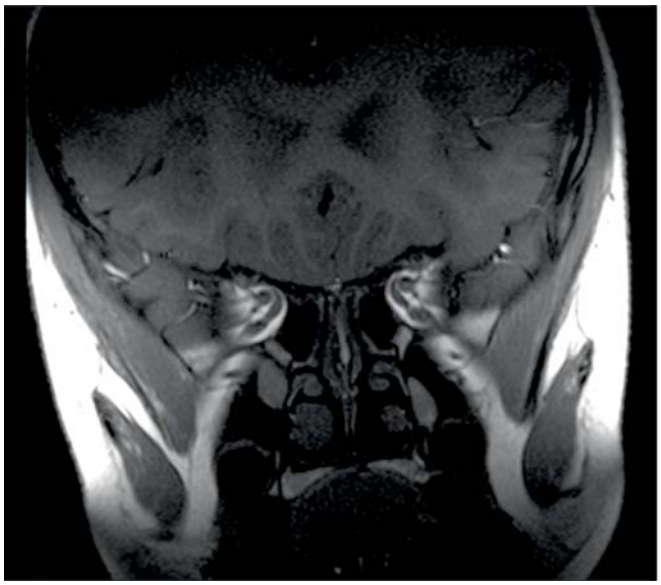

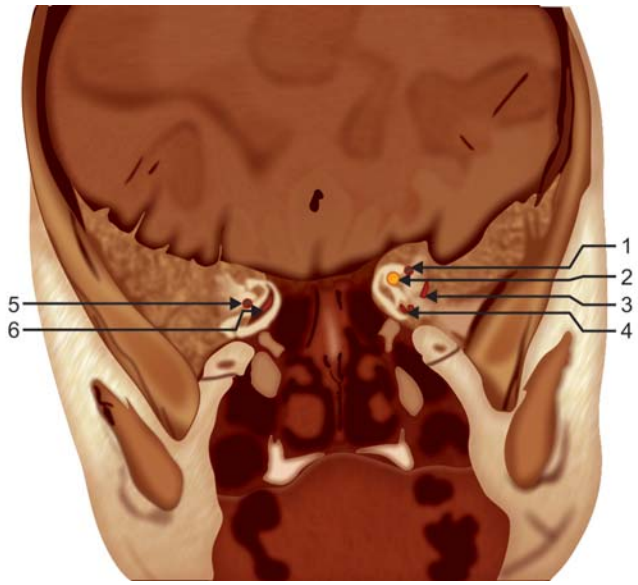

Figure 2.7

1. Long posterior ciliary artery
2. Optic nerve
3. Lateral rectus
4. Inferior rectus
5. Ophthalmic artery
6. Medial rectus



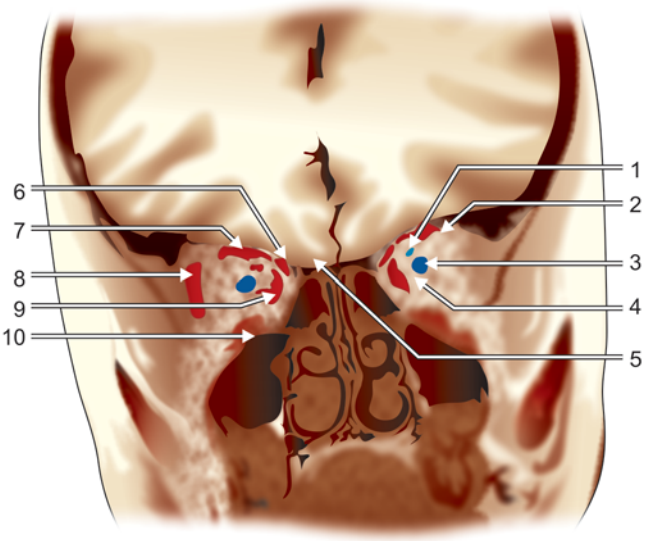

Figure 2.8

1. Long posterior ciliary artery
2. Superior Ophthalmic vein
3. Optic nerve
4. Ophthalmic artery
5. Gyrus rectus
6. Superior oblique
7. Superior rectus
8. Lateral rectus
9. Medial rectus
10. Inferior rectus

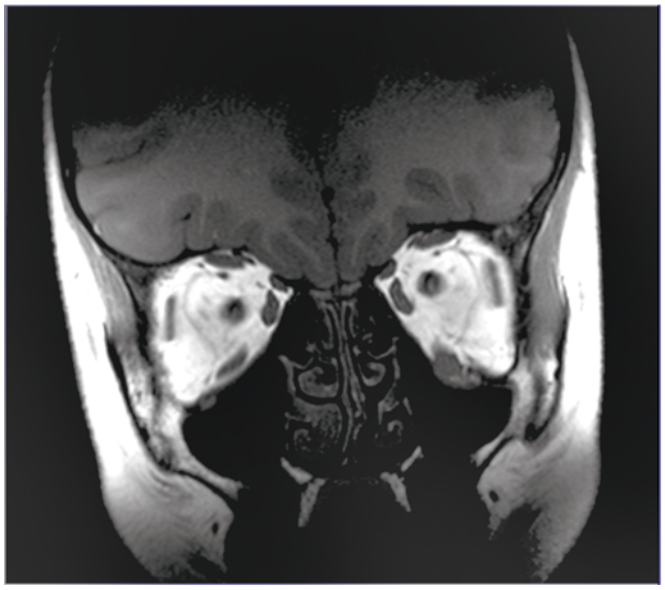

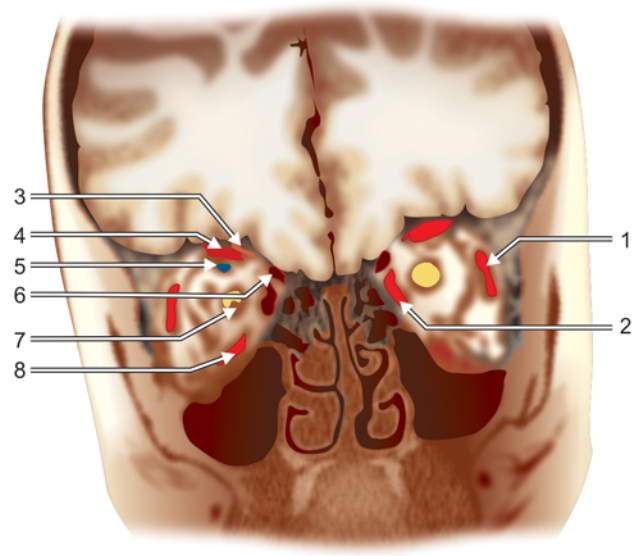

Figure 2.9

1. Lateral rectus
2. Medial rectus
3. Levator palpebrae superioris muscle
4. Superior rectus
5. Superior ophthalmic vein
6. Superior oblique
7. Optic nerve
8. Inferior rectus



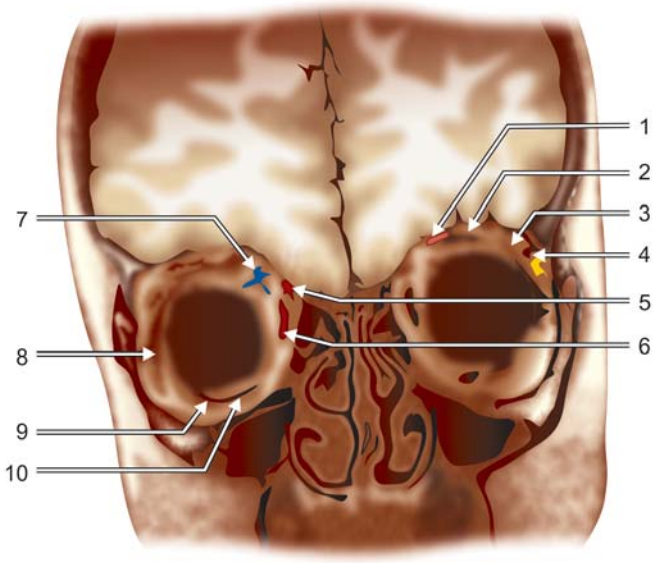

Figure 2.10

1. Levator palpebrae superioris muscle
2. Superior rectus
3. Intermuscular septum
4. Lacrimal gland
5. Superior oblique
6. Medial rectus
7. Superior ophthalmic vein
8. Lateral rectus
9. Inferior oblique
10. Inferior rectus

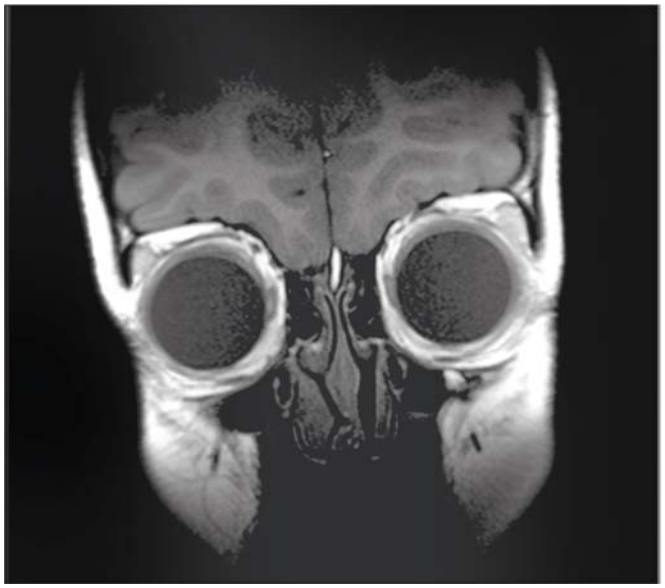

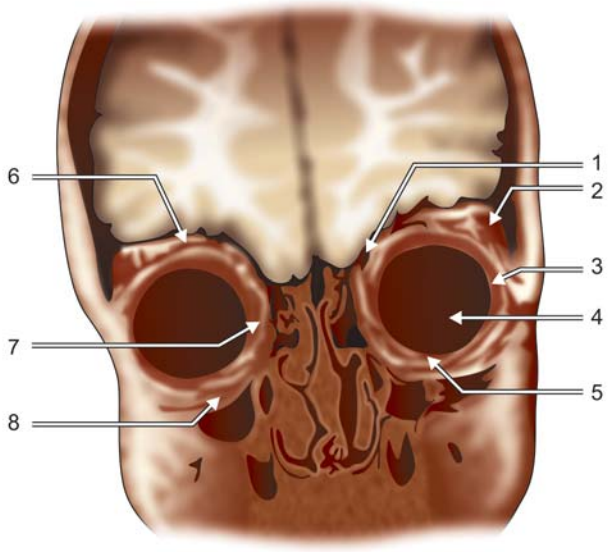

Figure 2.11

1. Superior oblique
2. Lacrimal gland
3. Sclera
4. Vitreous
5. Inferior rectus
6. Superior rectus and levator palpebrae muscles
7. Medial rectus
8. Inferior oblique

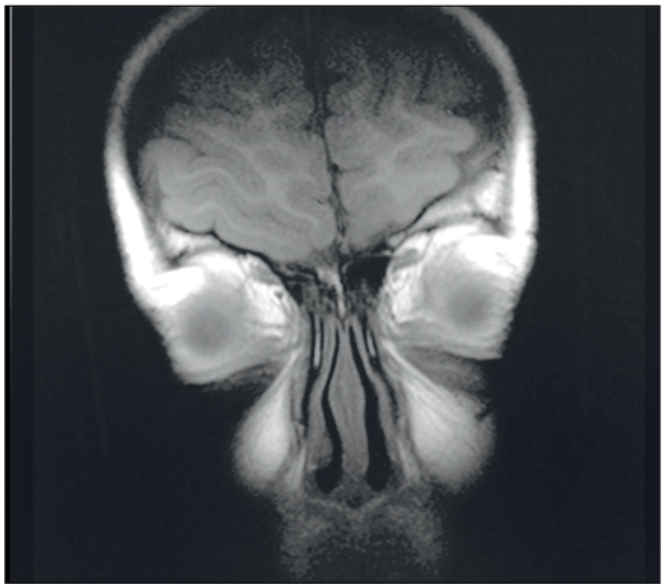

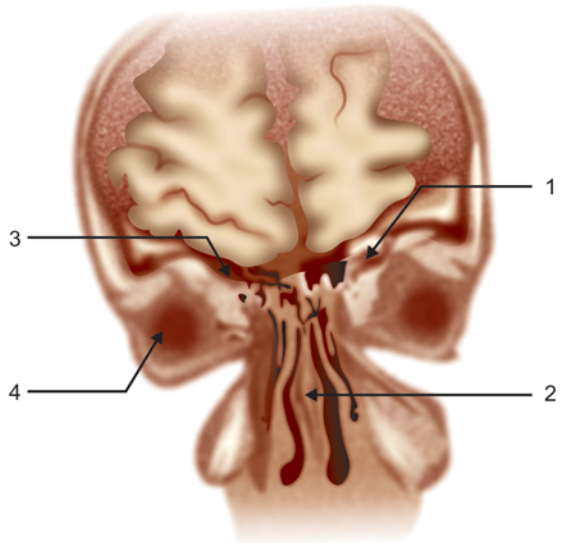

Figure 2.12

1. Reflected tendon of superior oblique
2. Nasal septum
3. Trochlea
4. Globe

CHAPTER 3

PNS and Skull Base

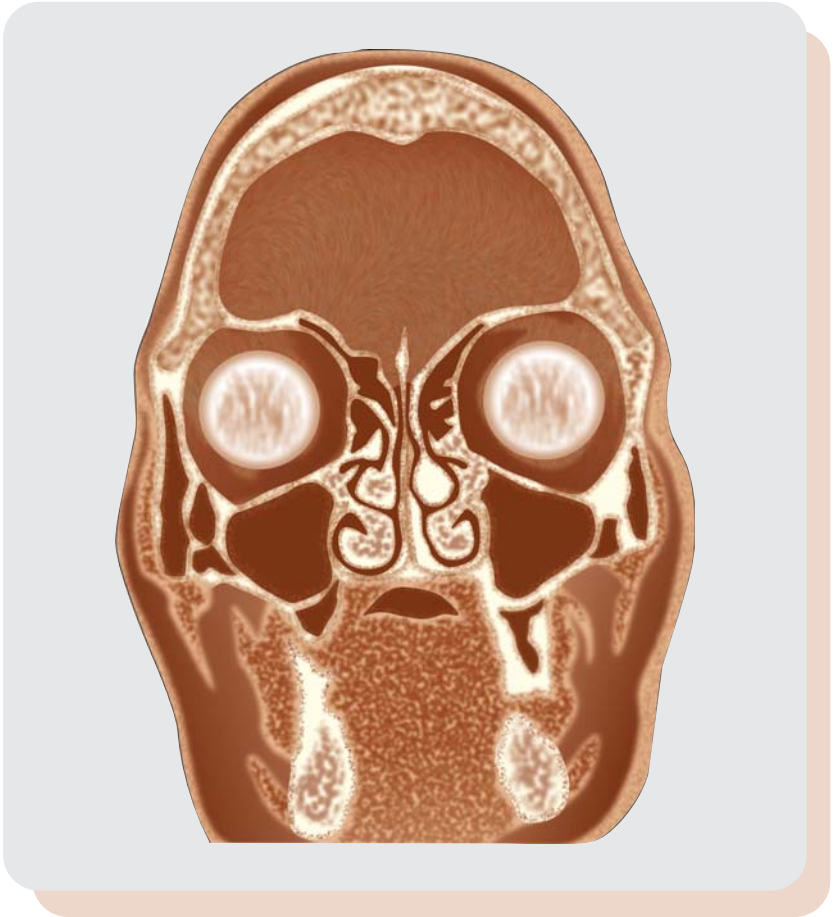

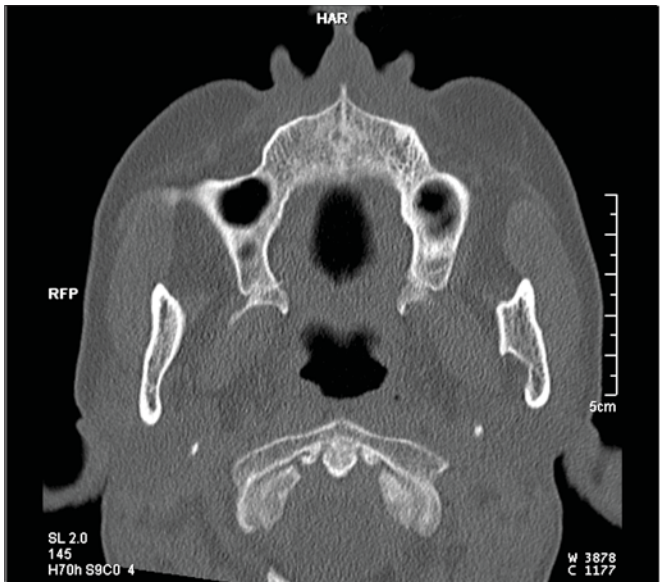

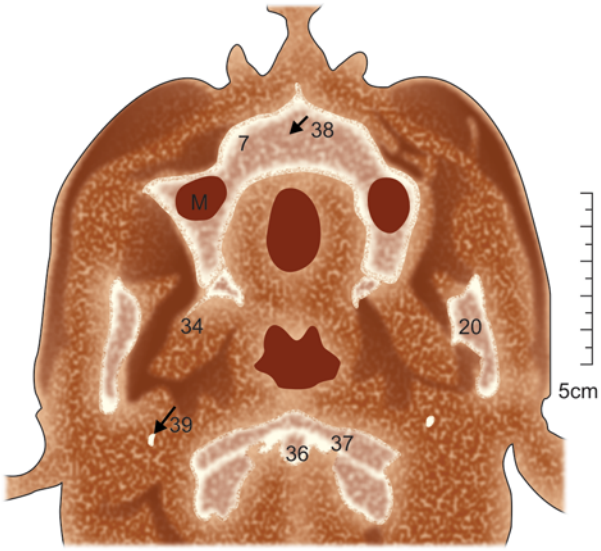

Figure 3.1: 38; Incisive canal, 7; Alveolar margin of maxilla, M; Maxillary sinus, 34; Lateral pterygoid plate, 39; Styloid process, 36; Dens of axis, 37; Anterior arch of atlas, 20; Mandible

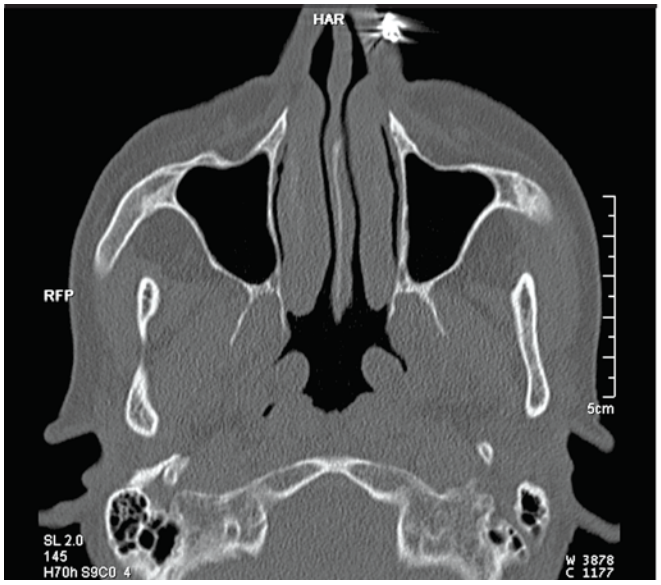

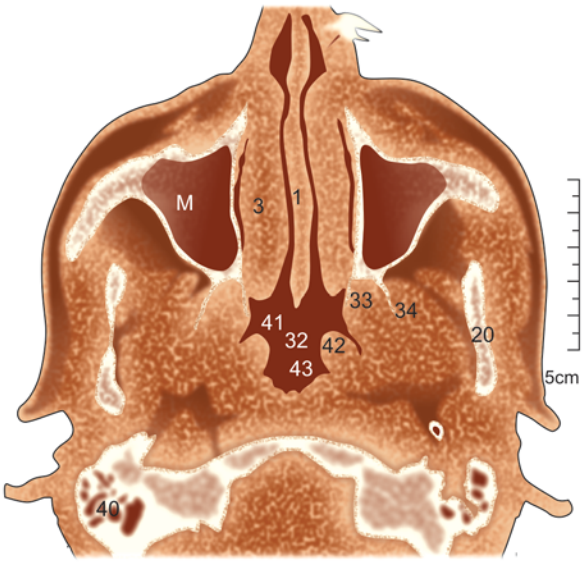

Figure 3.2: 1; Nasal septum, 3; Inferior turbinate, M; Maxillary sinus, 20; Mandible 32; Nasopharynx 33; Medial pterygoid plate 34; Lateral pterygoid plate, 41; Eustachian tube opening 42; Torus tubrius 43; Fossa of Rosenmuller

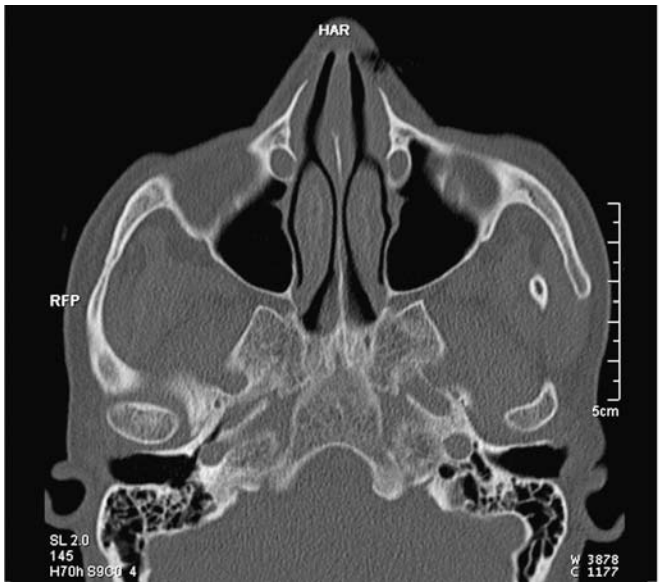

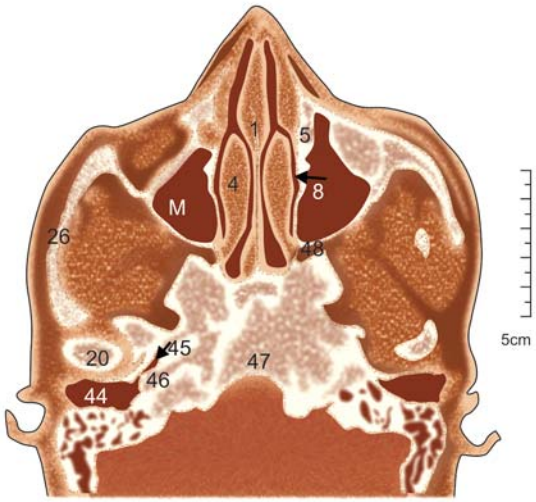

Figure 3.3: 1; Nasal septum, 4; Middle turbinate, 8; Middle meatus, M; Maxillary sinus, 48; Pterygopalatine fossa, 45; Eustachian tube 46; Internal carotid artery, 47; Basi-occiput 44; External auditory canal, 20; Mandible, 26; Zygomatic arch

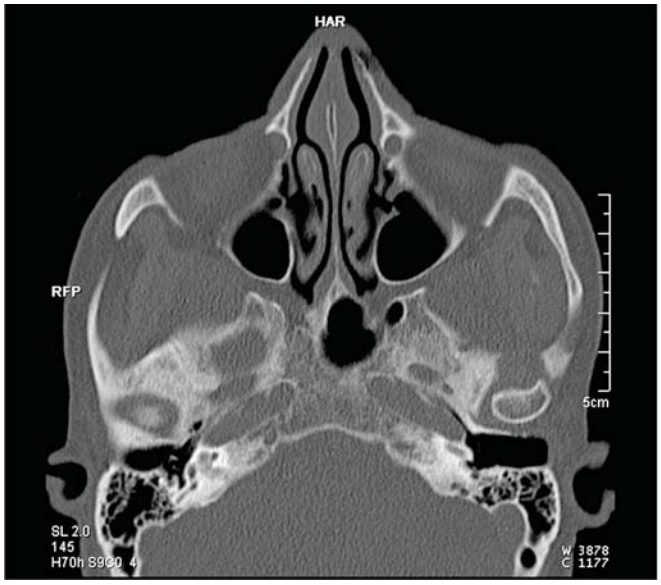

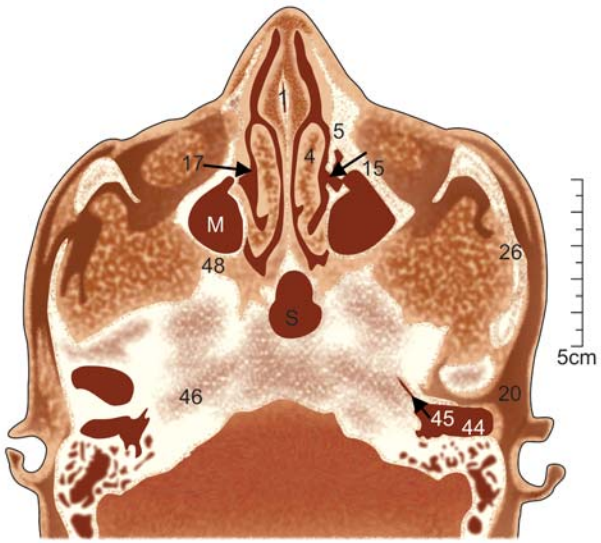

Figure 3.4: 1; Nasal septum, 4; Middle turbinate, 5; Nasolacrimal duct 15; Hiatus semilunaris, M; maxillary sinus; S; sphenoid sinus 48; Pterygopalatine fossa, 20; Mandible, 44; External auditory meatus 45; Eustachian tube 46; Internal carotid artery, 26; Zygomatic arch



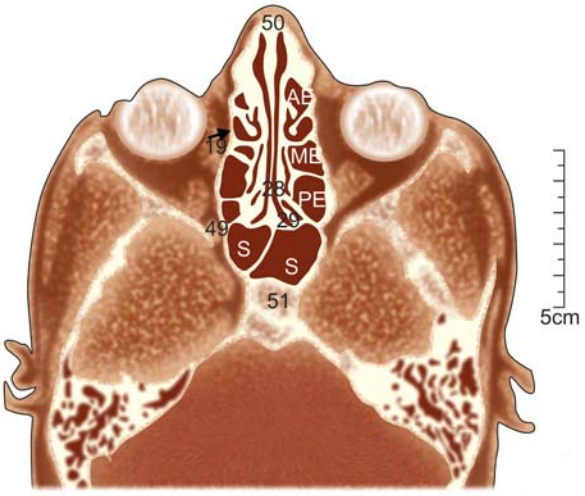

Figure 3.5: 50; Nasal bone; S; Sphenoid sinus, AE; Anterior ethmoid cells, ME; Middle ethmoid cells, PE; Posterior ethmoid cells, 28; Perpendicular plate of ethmoid, 29; Spheno-ethmoidal recess, 49; Superior orbital fissure, 51; Pituitary fossa



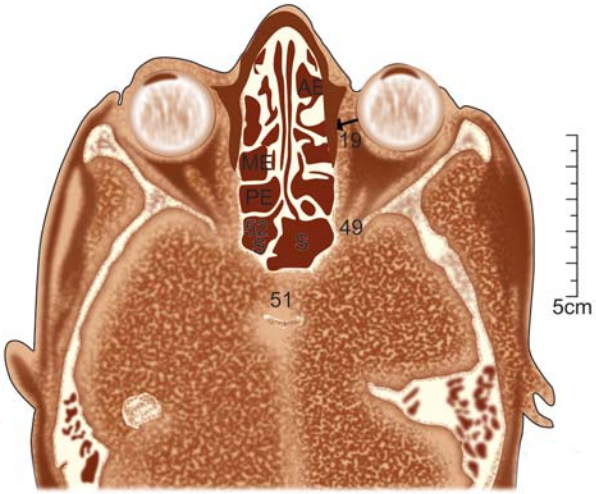

Figure 3.6: AE; Anterior ethmoid cells, ME; Middle ethmoid cells, PE; Posterior ethmoid cells, 49; Superior orbital fissure 51; Pituitary fossa, 52; Sphenoid ostium

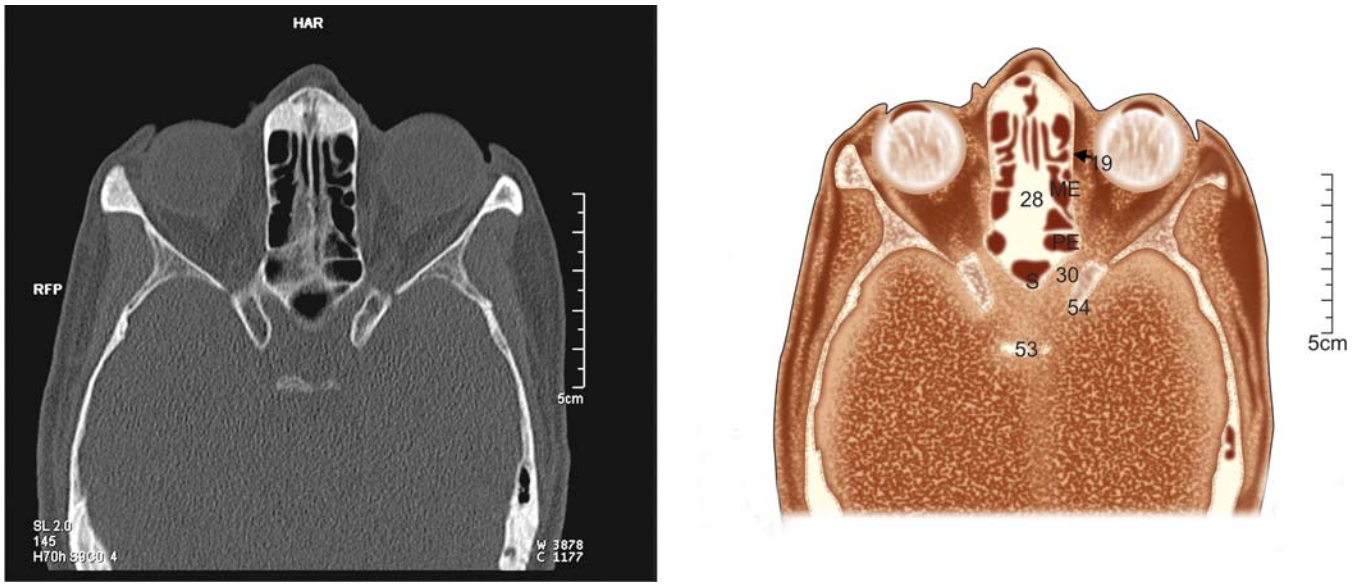

Figure 3.7: ME; Middle ethmoid cells, PE; Posterior ethmoid cells, S; Sphenoid sinus, 19; Lamina papyracea 28; Perpendicular plate of ethmoid, 30; Optic canal, 54; Anterior clinoid, 53; Dorsum sella

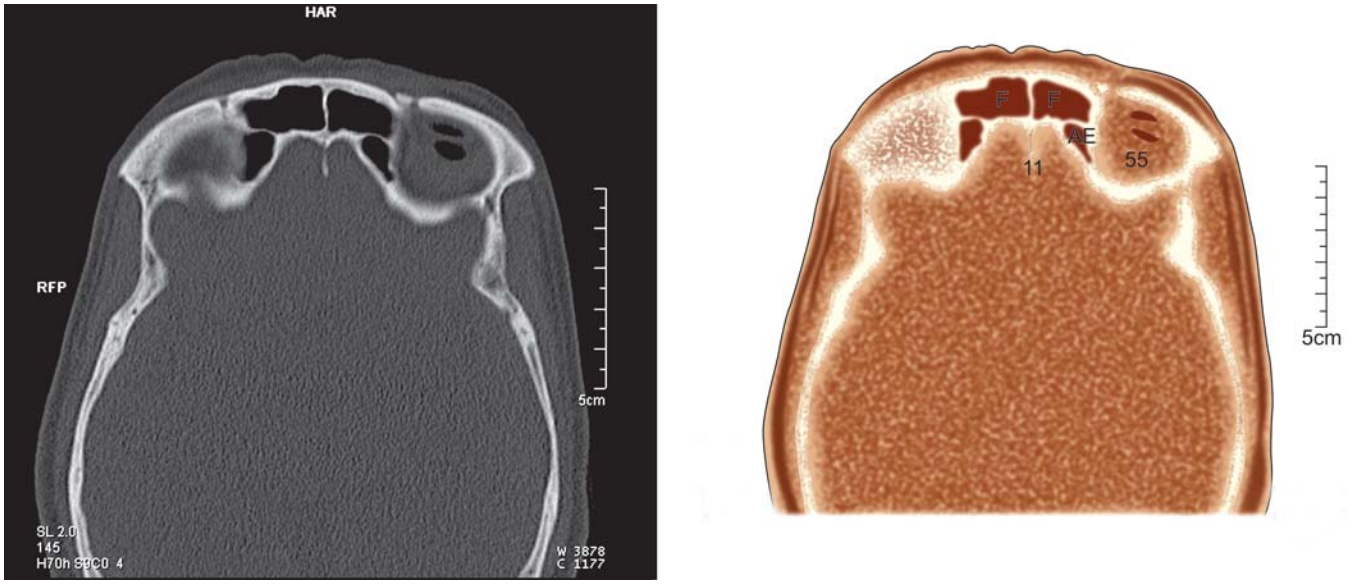

Figure 3.8: F; Frontal sinus, AE; Anterior ethmoid cells 11; Crista galli, 55; Orbit

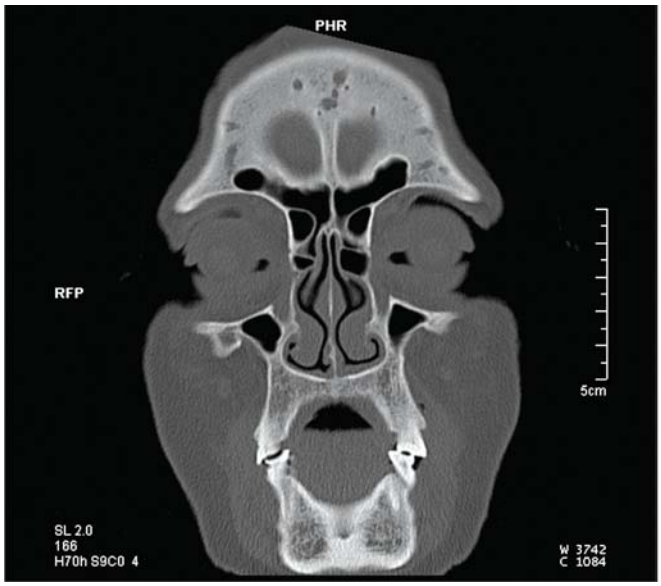



Figure 3.9: F; Frontal sinus, M; Maxillary sinus, 1; Nasal septum 2; Agger nasi cells, 3; Inferior turbinate, 4; Middle turbinate 5; Nasolacrimal duct, 6; Frontal recess, 7; Alveolar margin of maxilla

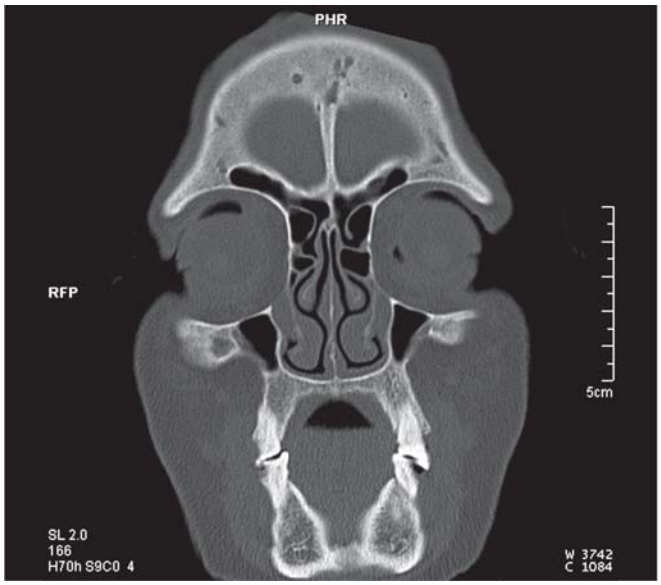

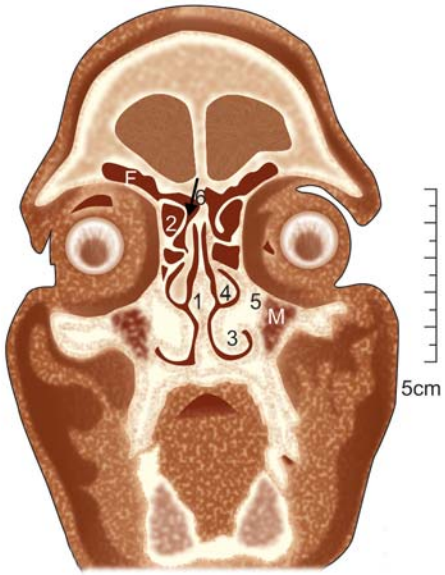

Figure 3.10: F; Frontal sinus, M; maxillary sinus, 1; Nasal septum 2; Agger nasi cells 3; Inferior turbinate 4; Middle turbinate 5; Nasolacrimal duct 6; Frontal recess

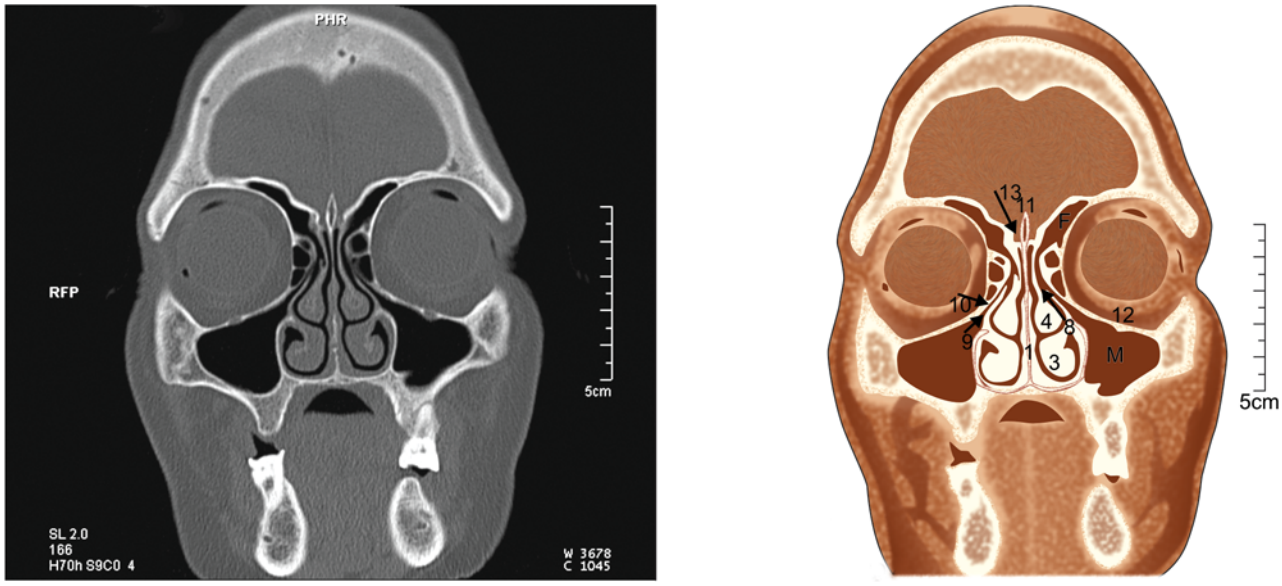

Figure 3.11. F; Frontal sinus, M; Maxillary sinus, 1; Nasal septum, 3; Inferior turbinate 4; Middle turbinate, 8; Middle meatus, 9; Primary ostium of maxillary antrum 10. Infundibulum 11. Crista galli, 12; Infraorbital foramen, 13; Cribriform plate



Figure 3.12: M; maxillary sinus, 8; Middle meatus, 11; Crista galli 10; Infundibulum 14; Bulla ethmoidalis, 15; Hiatus semilunaris 16; Hard palate, 17; Uncinate process

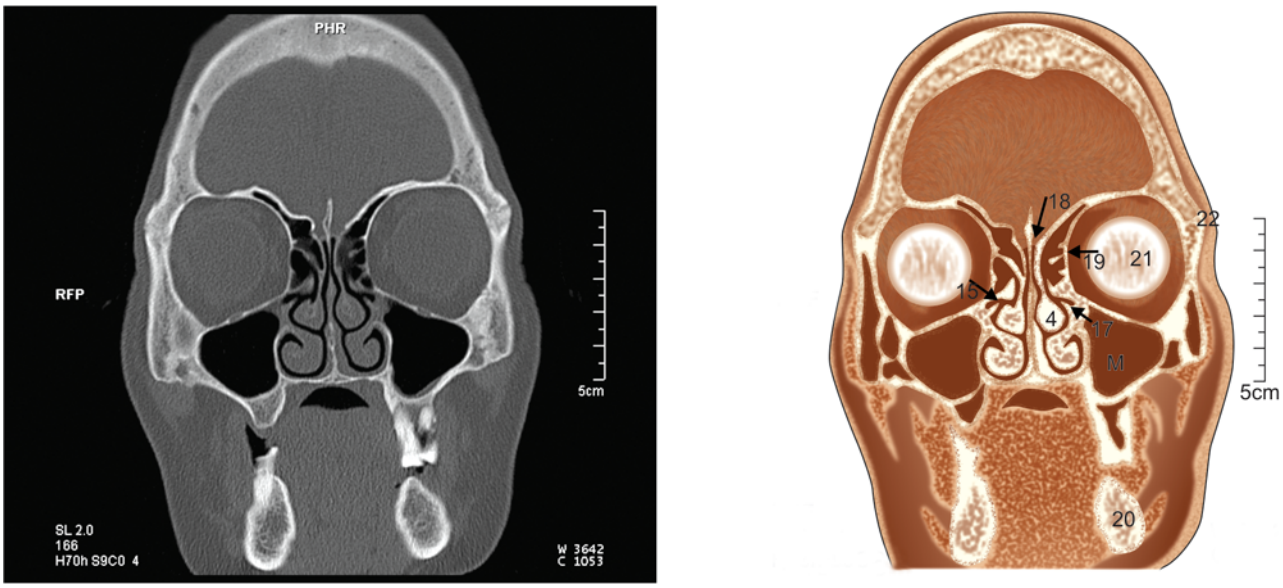

Figure 3.13: M; Maxillary sinus, 4; Middle turbinate 15; Hiatus semilunaris 17; Uncinate process 18; Fovea ethmoidalis 19; Lamina papyracea, 20; Mandible, 21; Globe

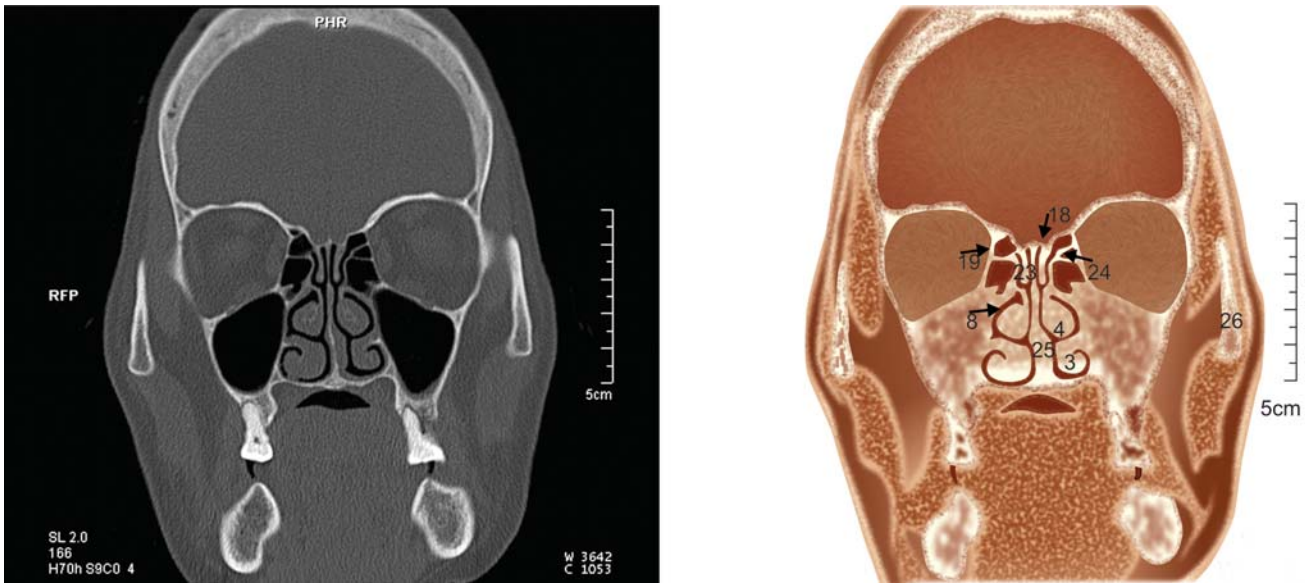

Figure 3.14: 3; Inferior turbinate, 4; Middle turbinate, 8; Middle meatus 18; Fovea ethmoidalis, 19; Lamina papyracea, 23; superior turbinate 24; Basal lamina, 25; Vomer bone, 26; Zygomatic arch

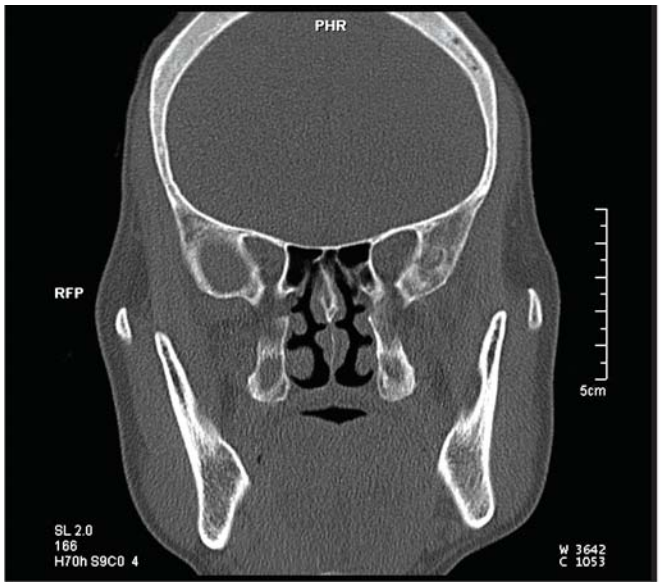

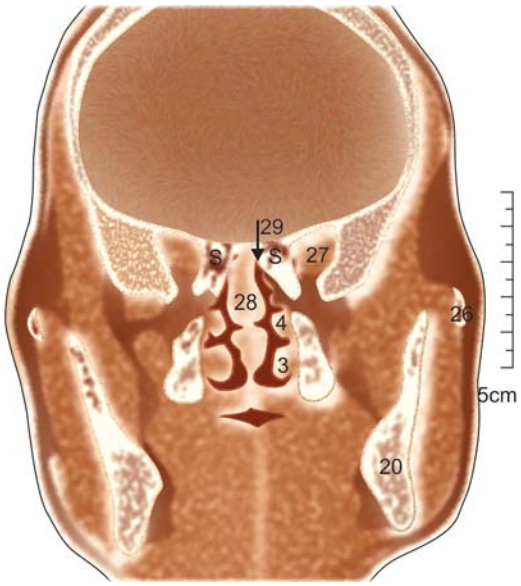

Figure 3.15: S; Sphenoid sinus, 3; Inferior turbinate, 4; Middle turbinate, 20; Mandible, 26; Zygomatic arch, 27; Orbital apex 28; Perpendicular plate of ethmoid, 29; Spheno-ethmoidal recess

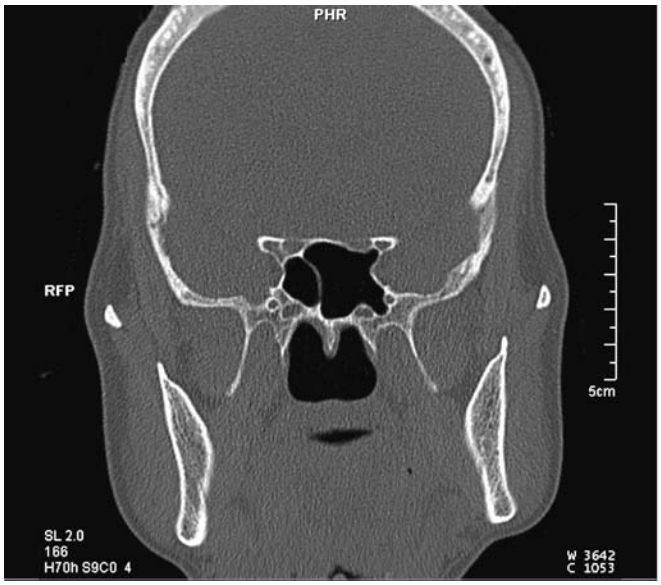

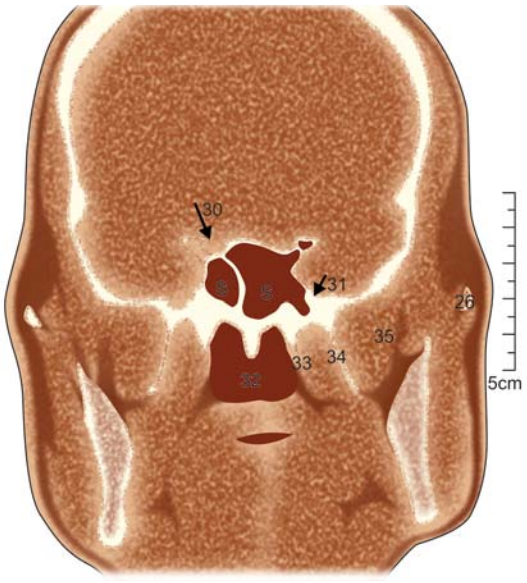

Figure 3.16: S; Sphenoid sinus, 28; Perpendicular plate of ethmoid, 30; Optic canal, 31; Foramen rotundum, 32; Nasopharynx, 33; Medial pterygoid plate, 34; Lateral pterygoid plate, 35; Infratemporal fossa

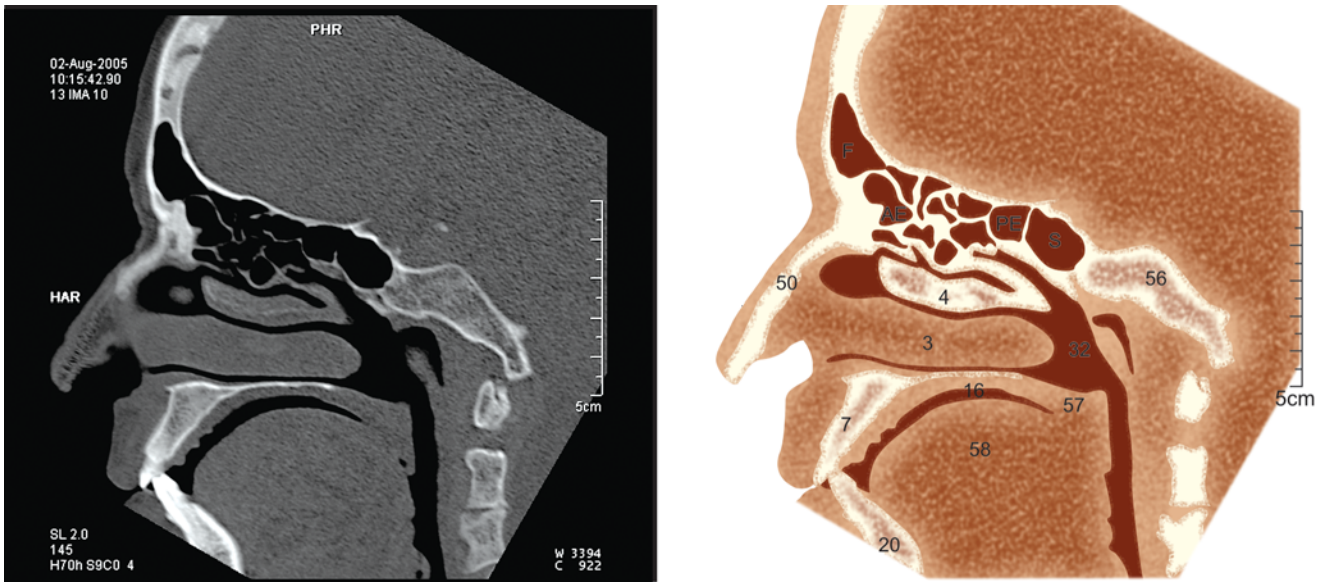

Figure 3.17: AE; Anterior ethmoid cells, PE; Posterior ethmoidal cells 3; Inferior turbinate, 4; Middle turbinate, 32; nasopharynx, 50; Nasal bone 56; Clivus, 57; Soft palate, 58; Tongue, 20; Mandible, F; Frontal sinus, S; Sphenoid sinus

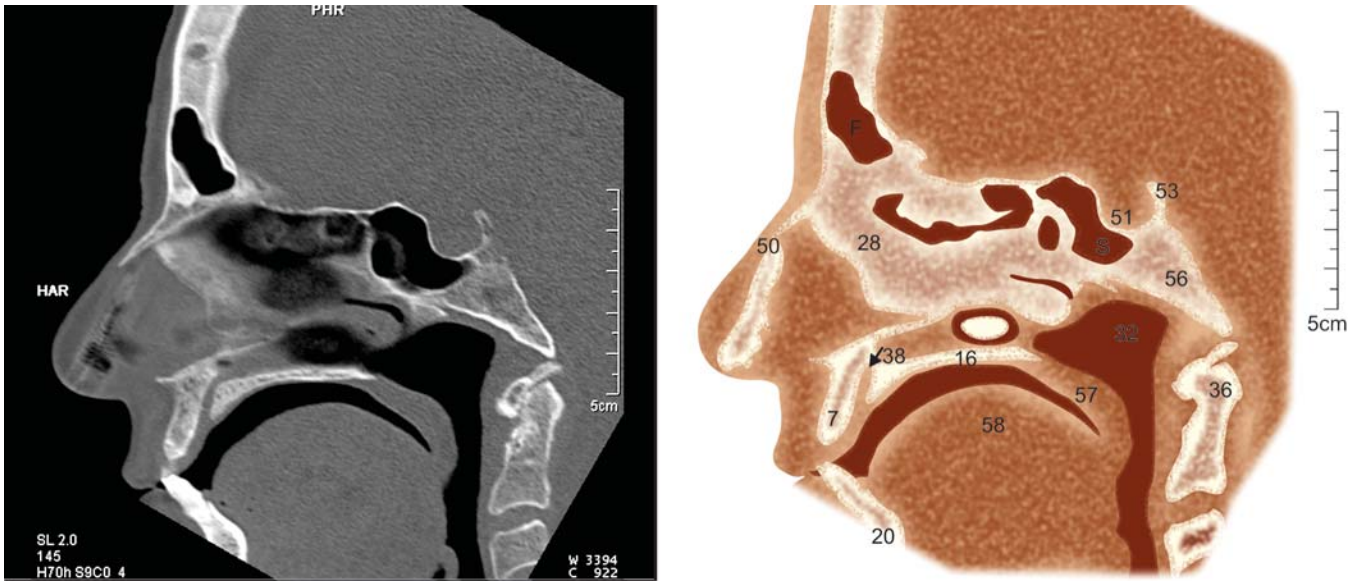

Figure 3.18: F; Frontal sinus, S; Sphenoid sinus, 7; Alveolar margin of Maxilla 16; Hard palate, 28; Perpendicular plate of ethmoid, 32; Nasopharynx, 36; Dens of axis, 38; Incisive canal, 51; Pituitary fossa, 53; Dorsum sella, 56; Clivus, 57; Soft palate, 58; Tongue, 50; Nasal bone, 20; Mandible

KEYS: PNS

1. Nasal septum
2. Agger nasi cells
3. Inferior turbinate
4. Middle turbinate
5. Nasolacrimal duct
6. Frontal recess
7. Alveolar margin of maxilla
8. Middle meatus
9. Primary ostium of maxillary antrum
10. Infundibulum
11. Crista galli
12. Infraorbital foramen
13. Cribriform plate
14. Bulla ethmoidalis
15. Hiatus semilunaris
16. Hard palate
17. Uncinate process
18. Fovea ethmoidalis
19. Lamina papyracea
20. Mandible
21. Globe
22. Zygomatico-frontal suture
23. Superior turbinate
24. Basal lamina
25. Vomer
26. Zygomatic arch
27. Orbital apex
28. Perpendicular plate of ethmoid
29. Spheno-ethmoidal recess
30. Optic canal
31. Foramen rotundum
32. Nasopharynx
33. Medial pterygoid plate
34. Lateral pterygoid plate
35. Infratemporal fossa
36. Dens of axis
37. Anterior arch of atlas
38. Incisive canal
39. Styloid process
40. Mastoid sinus
41. Eustachian tube opening
42. Torus tubarius
43. Fossa of Rosenmuller
44. External auditory meatus
45. Eustachian tube
46. Internal carotid artery
47. Basi-occiput
48. Pterygopalatine fossa
49. Superior orbital fissure
50. Nasal bone
51. Pituitary fossa
52. Sphenoid ostium
53. Dorsum sella
54. Anterior clinoid
55. Orbit
56. Clivus
57. Soft palate
58. Tongue

M= Maxillary sinus

S= Sphenoid sinus

F= Frontal sinus

AE= Anterior Ethmoid cells

ME= Middle Ethmoid cells

PE= Posterior Ethmoid cells

CHAPTER 4

Temporal Bones and TM Joint

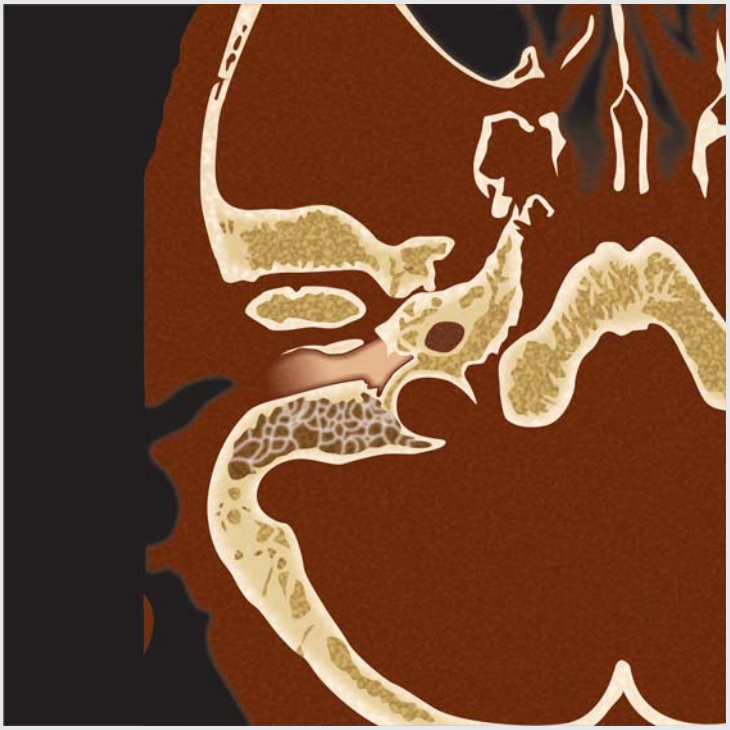

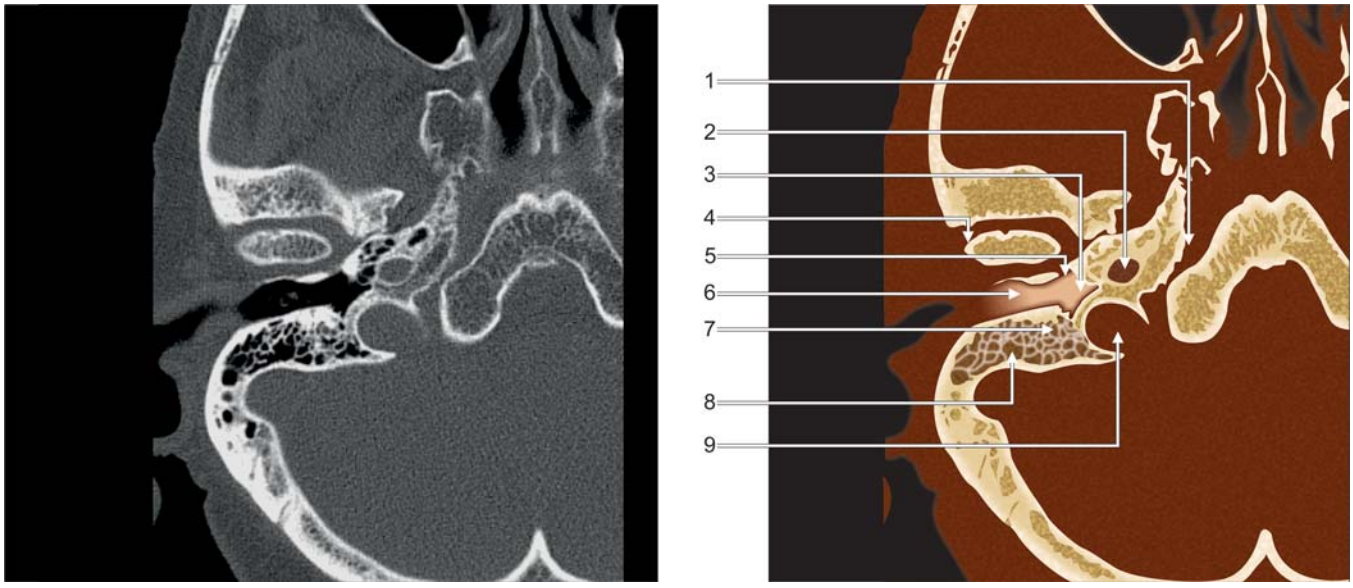

Figure 4.1

1. Petro-occipital fissure
2. Carotid canal
3. Hypotympanum
4. TM joint
5. Limbus
6. External auditory canal
7. Facial nerve canal
8. Mastoid sinus
9. Jugular fossa

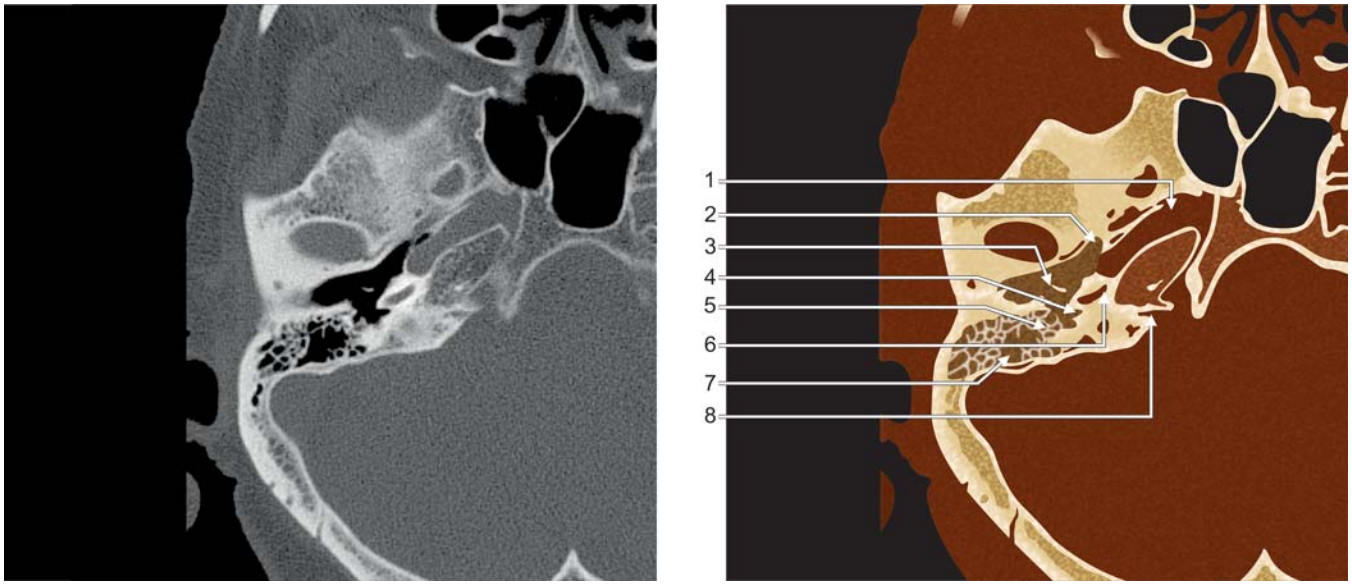

Figure 4.2

1. Carotid canal
2. Eustachian tube
3. Malleous, long process
4. Round window
5. Facial nerve
6. Basal turn of cochlea
7. Mastoid sinus
8. Cochlear aqueduct

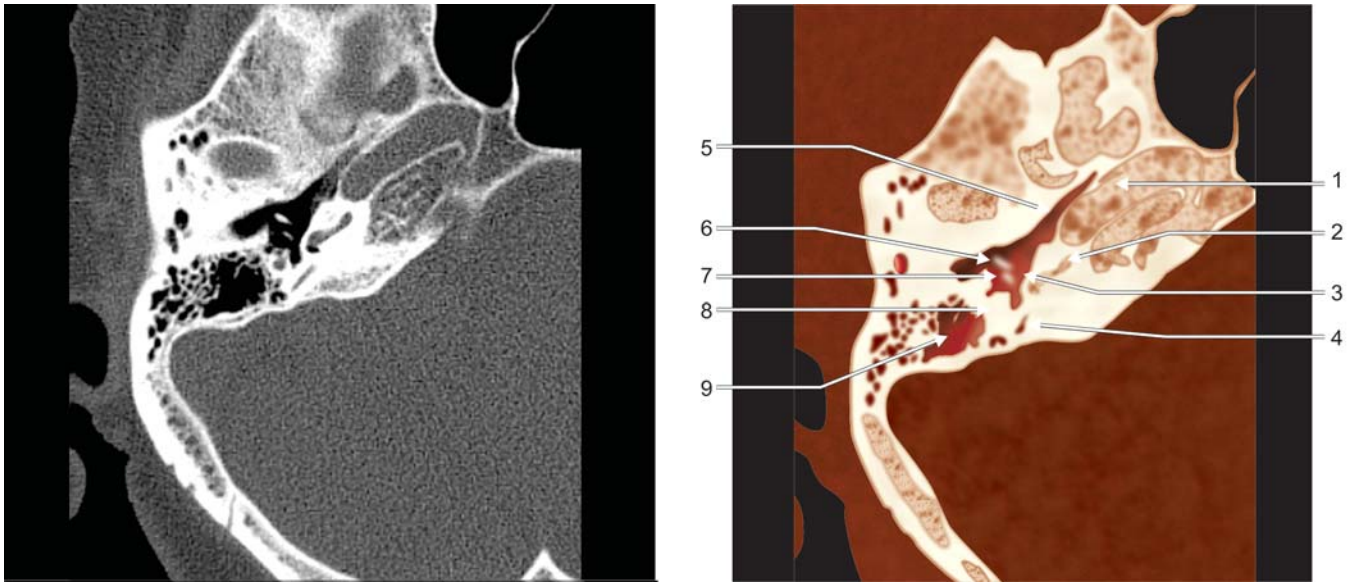

Figure 4.3

1. Carotid canal
2. Basal turn of cochlea
3. Middle ear
4. Posterior semicircular canal
5. Tensor tympani
6. Malleus, manubrium
7. Incus, long process
8. Facial nerve
9. Mastoid

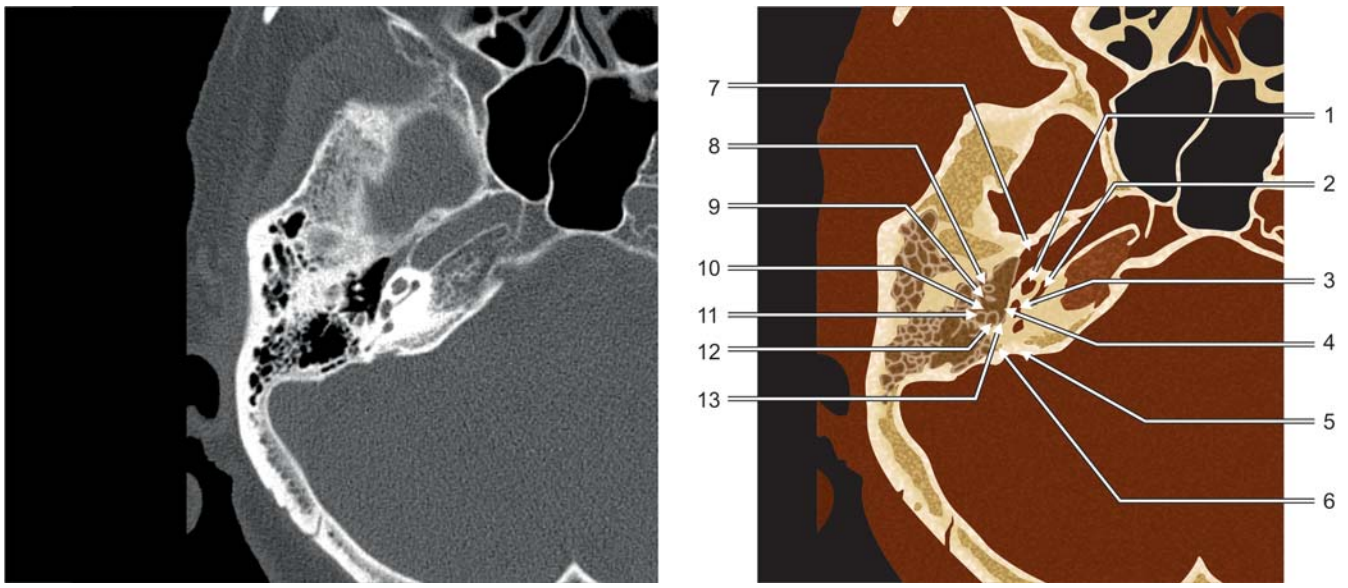

Figure 4.4

1. Apical turn, cochlea
2. Basal turn of cochlea
3. Vestibule
4. Stapes bone
5. Vestibular aqueduct
6. Posterior semicircular canal
7. Tensor tympani muscle
8. Malleus
9. Incus
10. Pyramidal eminence
11. Facial recess
12. Facial nerve
13. Sinus tympani

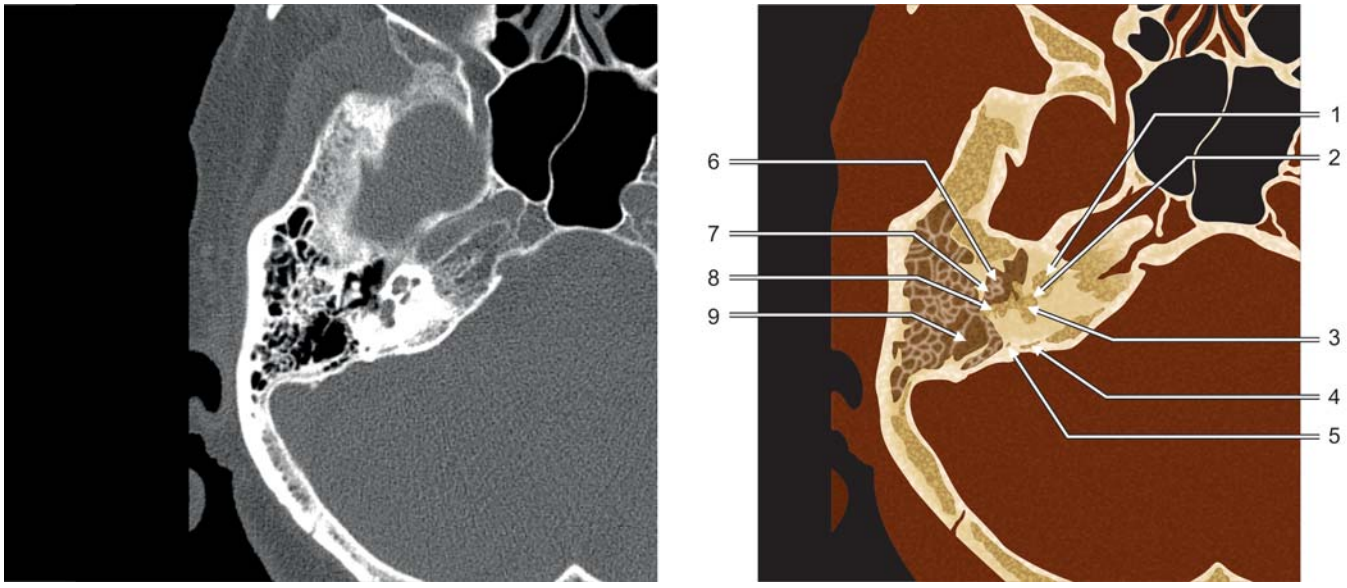

Figure 4.5

1. Cochlea
2. Vestibule
3. Oval window
4. Vestibular aqueduct
5. Posterior semicircular canal
6. Malleus
7. Incus
8. Facial nerve
9. Mastoid

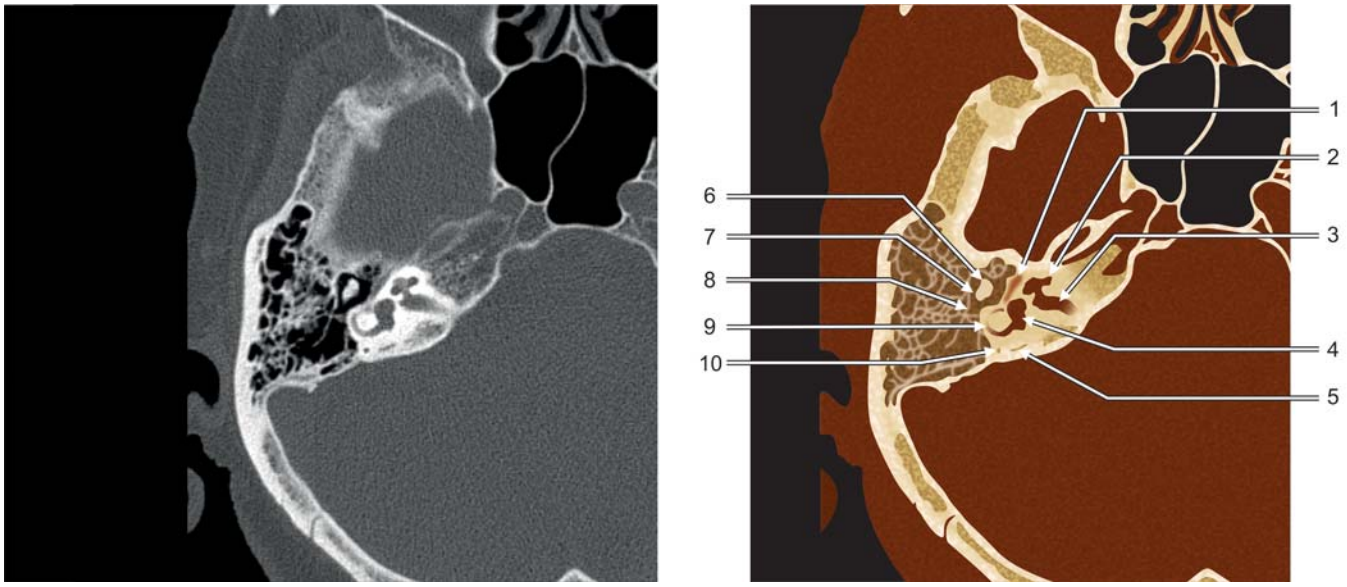

Figure 4.6

1. Facial nerve
2. Cochlea
3. Internal auditory canal
4. Vestibule
5. Vestibular aqueduct
6. Malleus
7. Incus
8. Aditus ad antrum
9. Lateral semicircular canal
10. Posterior semicircular canal

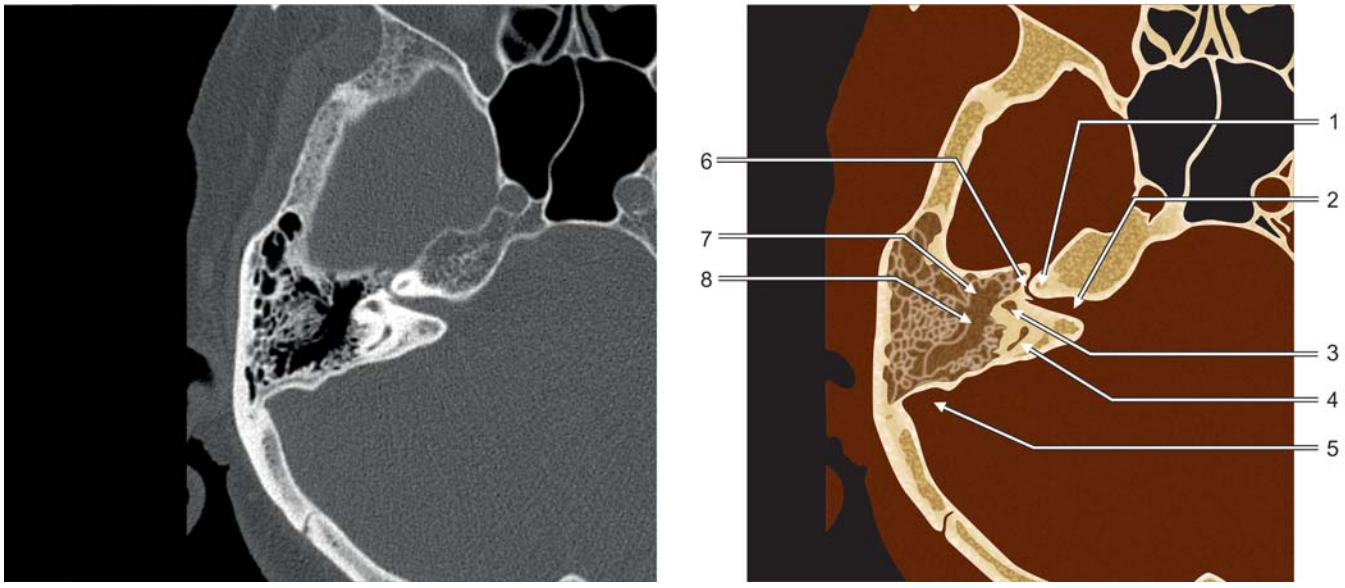

Figure 4.7

1. Cochlea
2. Internal auditory canal
3. Vestibule
4. Posterior semicircular canal
5. Sigmoid groove
6. Facial nerve
7. Epitympanum
8. Aditus ad antrum

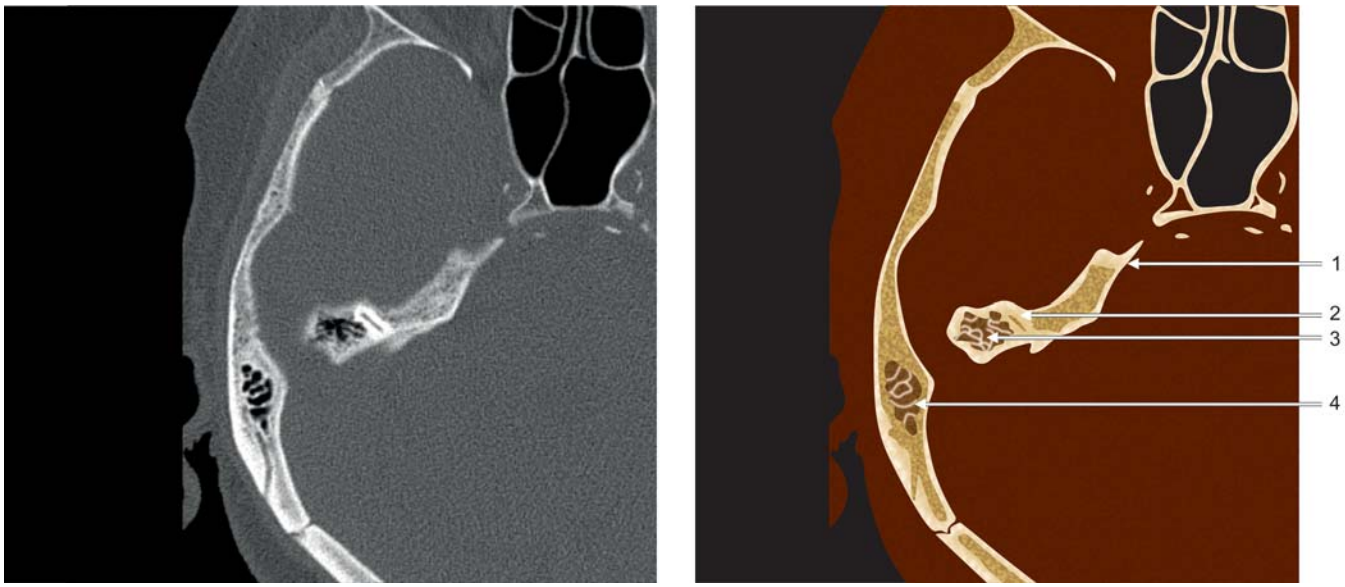

Figure 4.8

1. Petrous apex
2. Superior semicircular canal
3. Epitympanum
4. Mastoid

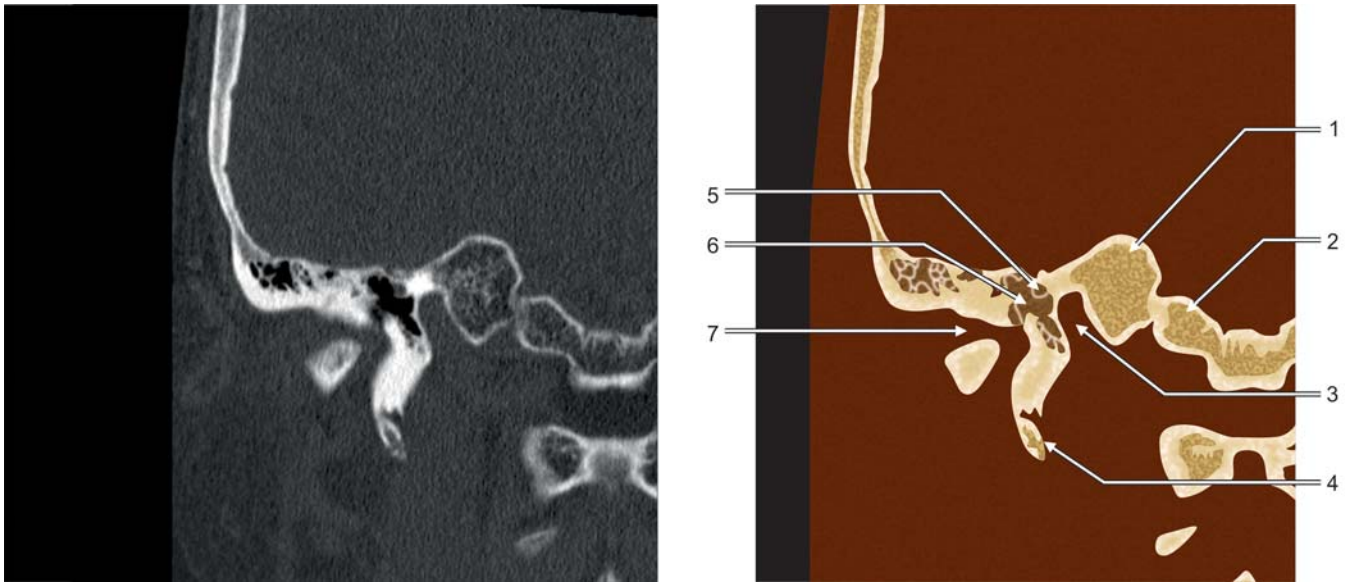

Figure 4.9

1. Petrous bone
2. Basi-occiput
3. Carotid canal
4. Styloid process
5. Tensor tympani muscle
6. Eustachian tube
7. TM joint

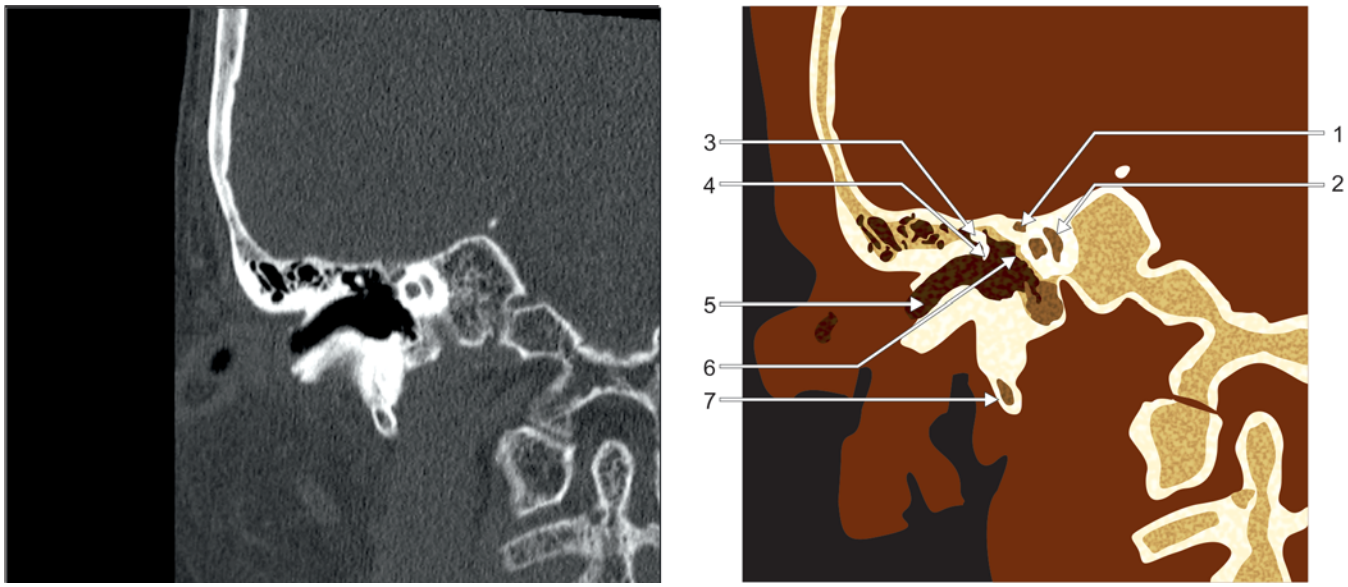

Figure 4.10

1. Facial nerve, anterior genu
2. Cochlea
3. Malleus
4. Incus
5. External auditory canal
6. Tensor tympani
7. Styloid process

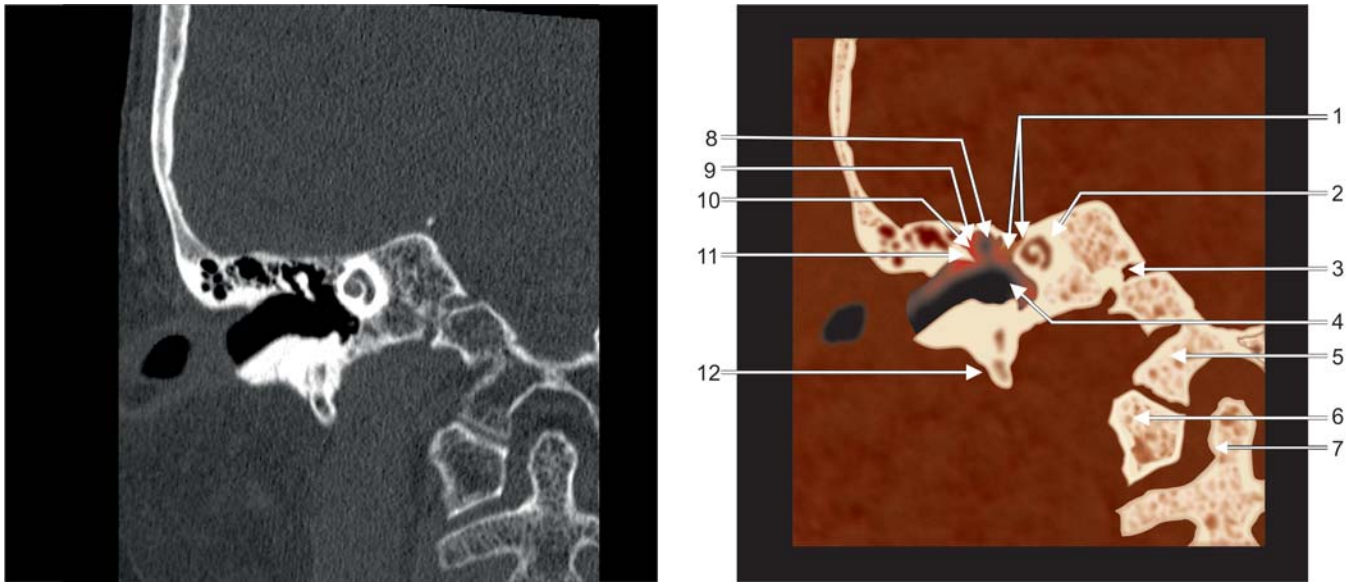

Figure 4.11

1. Facial nerve
2. Cochlea
3. Petro-occipital fissure
4. Middle ear
5. Occipital condyle
6. Lateral mass, atlas
7. Dens
8. Epitympanum
9. Malleus
10. Prussak's space
11. Scutum
12. Styloid process

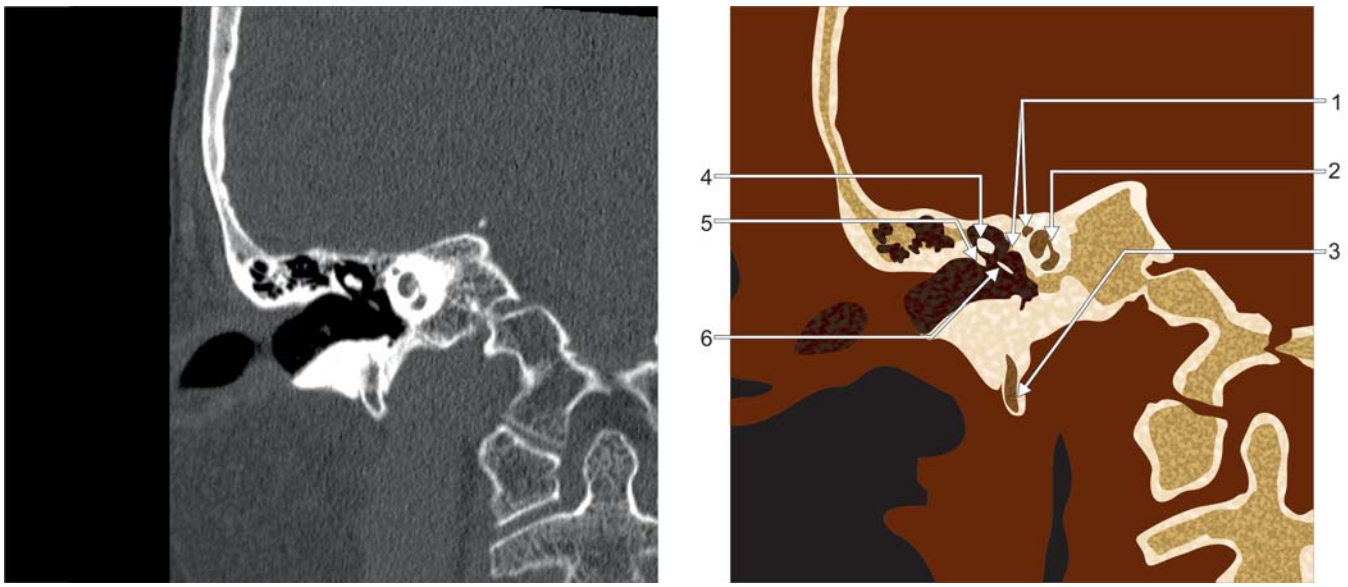

Figure 4.12

1. Facial nerve
2. Cochlea
3. Styloid process
4. Malleus
5. Scutum
6. Incus



Figure 4.13

1. Tegmen tympanum
2. Facial nerve
3. Cochlea, middle turn
4. Cochlea, basal turn
5. Hypotympanum
6. Styloid process

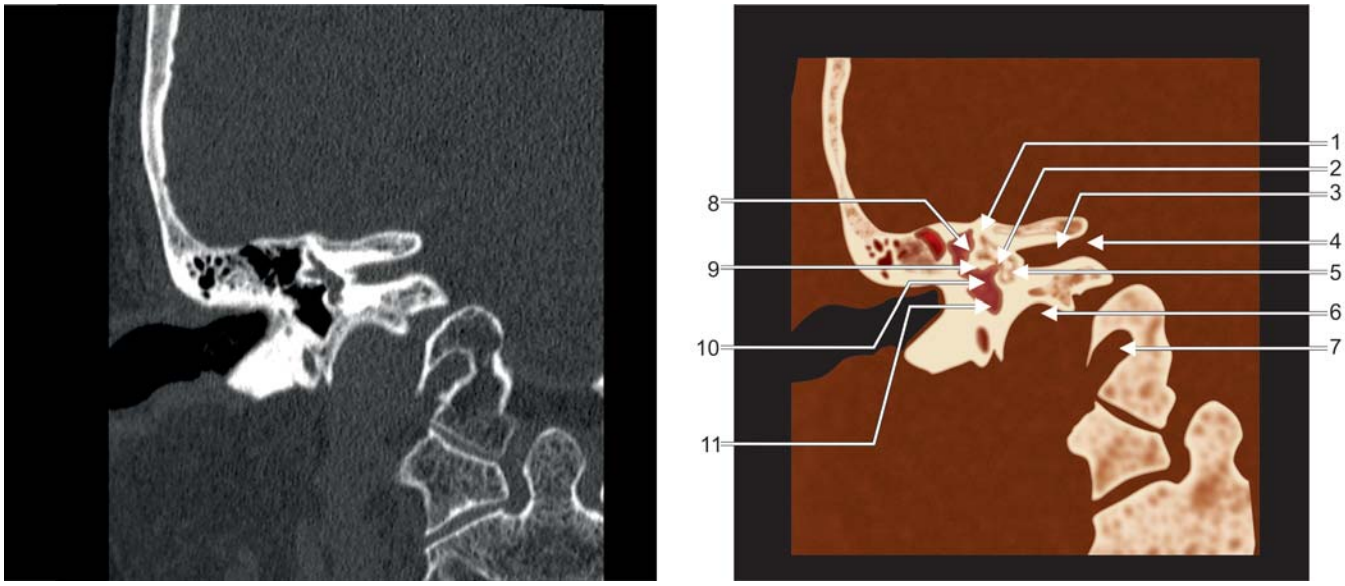

Figure 4.14

1. Superior semicircular canal
2. Oval window
3. Internal auditory canal
4. Porus acusticus
5. Vestibule
6. Jugular fossa
7. Hypoglossal cana
8. Lateral semicircular canal
9. Facial nerve
10. Stapes
11. Hypotympanum

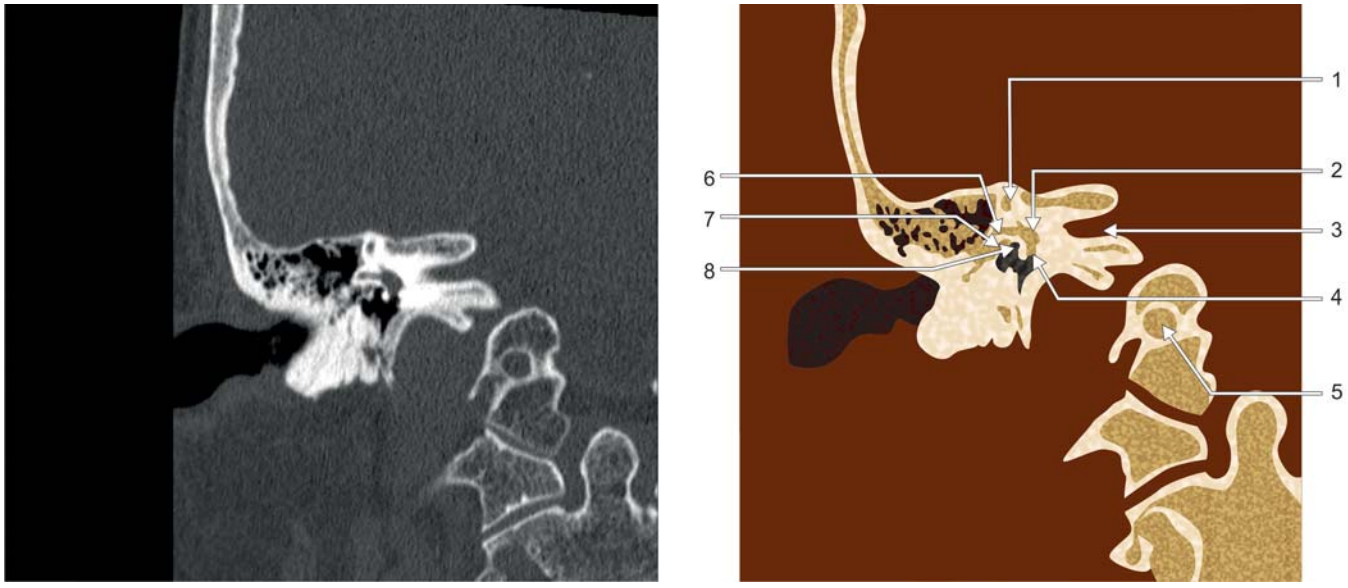

Figure 4.15

1. Superior semicircular canal
2. Vestibule
3. Internal auditory canal
4. Round window
5. Hypoglossal canal
6. Lateral semicircular canal
7. Facial nerve
8. Sinus tympani

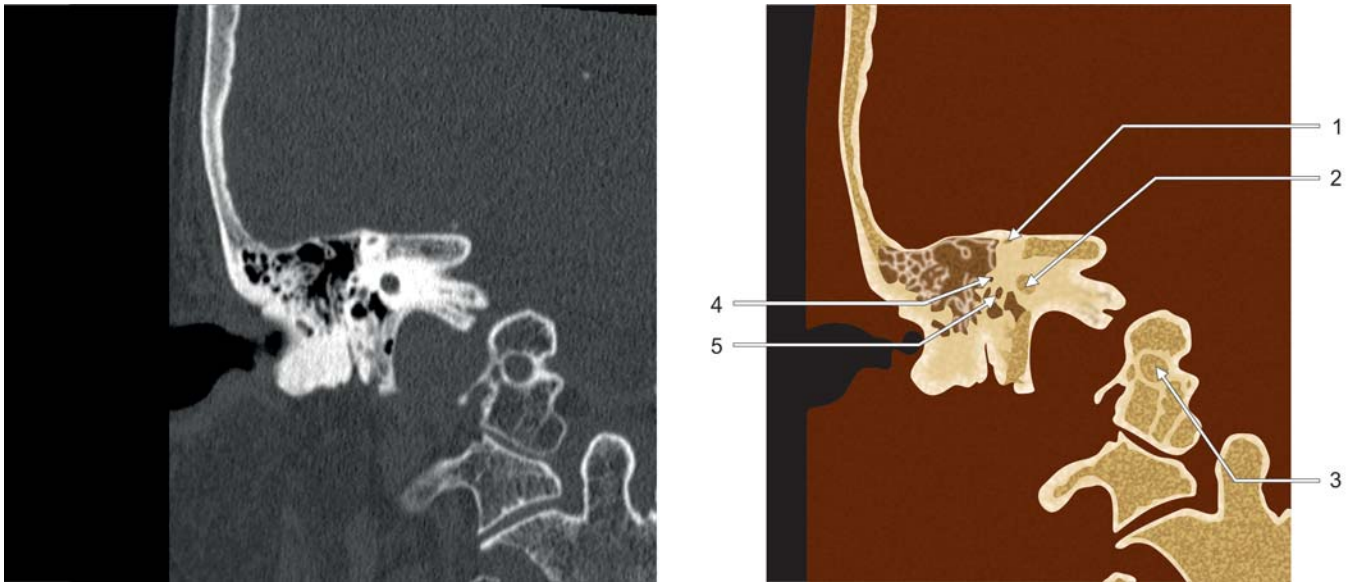

Figure 4.16

1. Superior semicircular canal
2. Vestibule
3. Hypoglossal canal
4. Lateral semicircular canal
5. Facial nerve

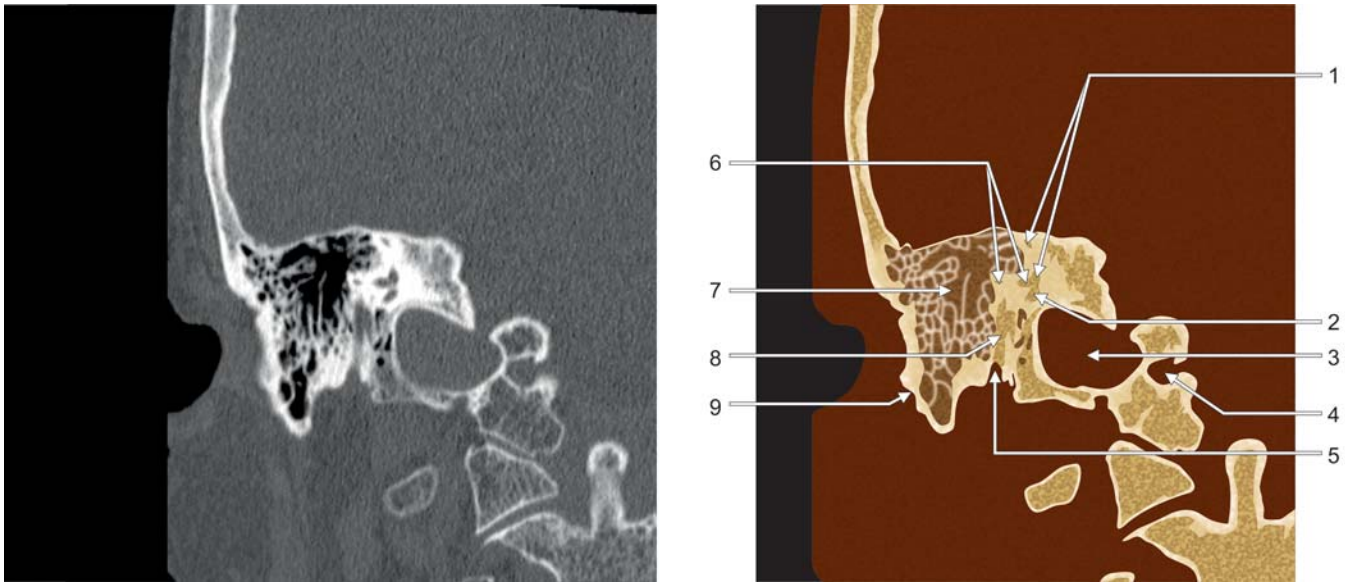

Figure 4.17

1. Superior semicircular canal
2. Posterior semicircular canal
3. Jugular fossa
4. Hypoglossal canal
5. Stylomastoid foramen
6. Lateral semicircular canal
7. Mastoid sinus
8. Facial nerve
9. Mastoid process

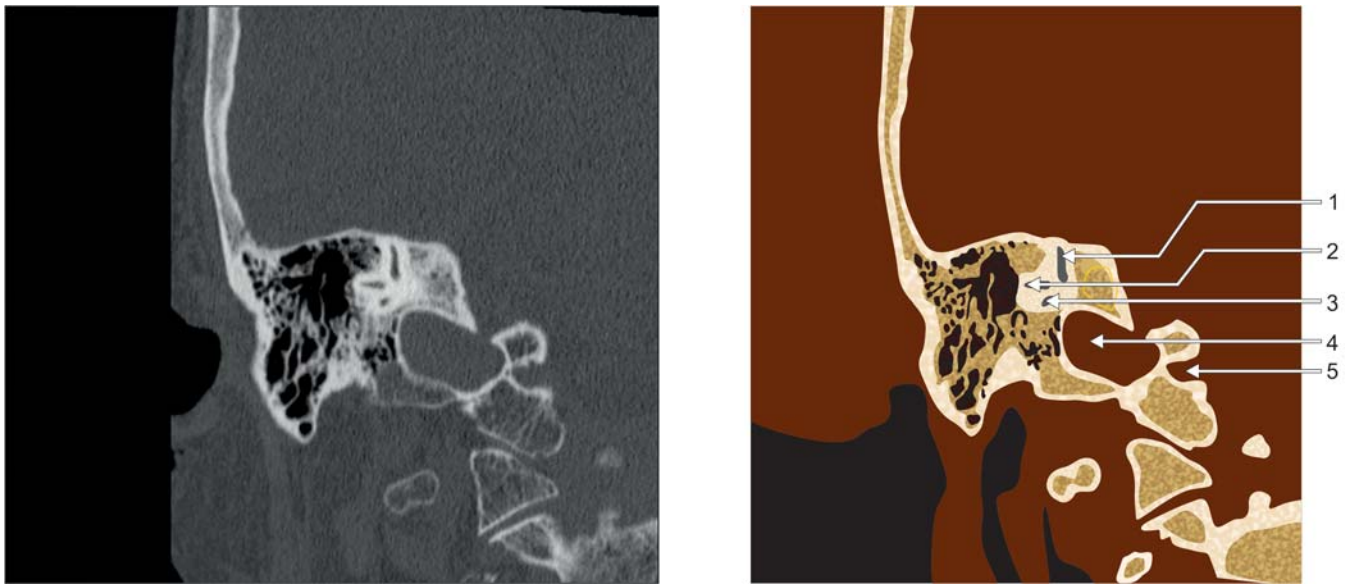

Figure 4.18

1. Superior semicircular canal
2. Lateral semicircular canal
3. Posterior semicircular canal
4. Jugular fossa
5. Hypoglossal canal

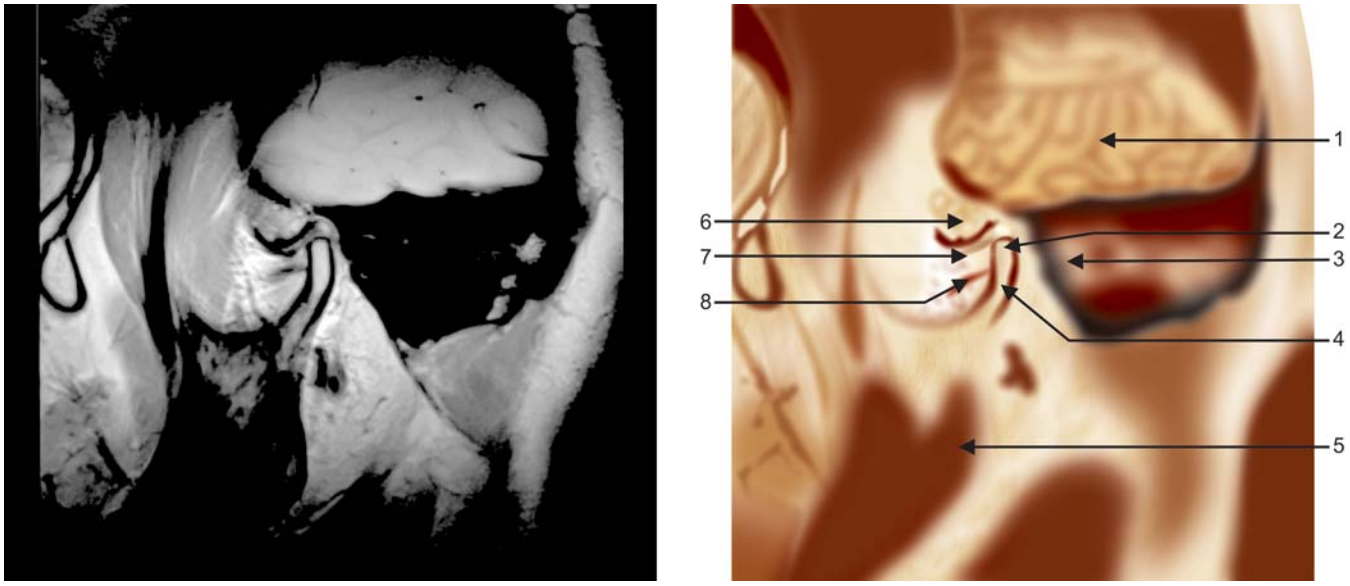

Figure 4.19

1. Temporal lobe, brain
2. Head of the mandible
3. External auditory canal
4. Neck of the mandible
5. Ramus of the mandible
6. Articular tubercle of temporal bone
7. Articular disk
8. Lateral pterygoid muscle

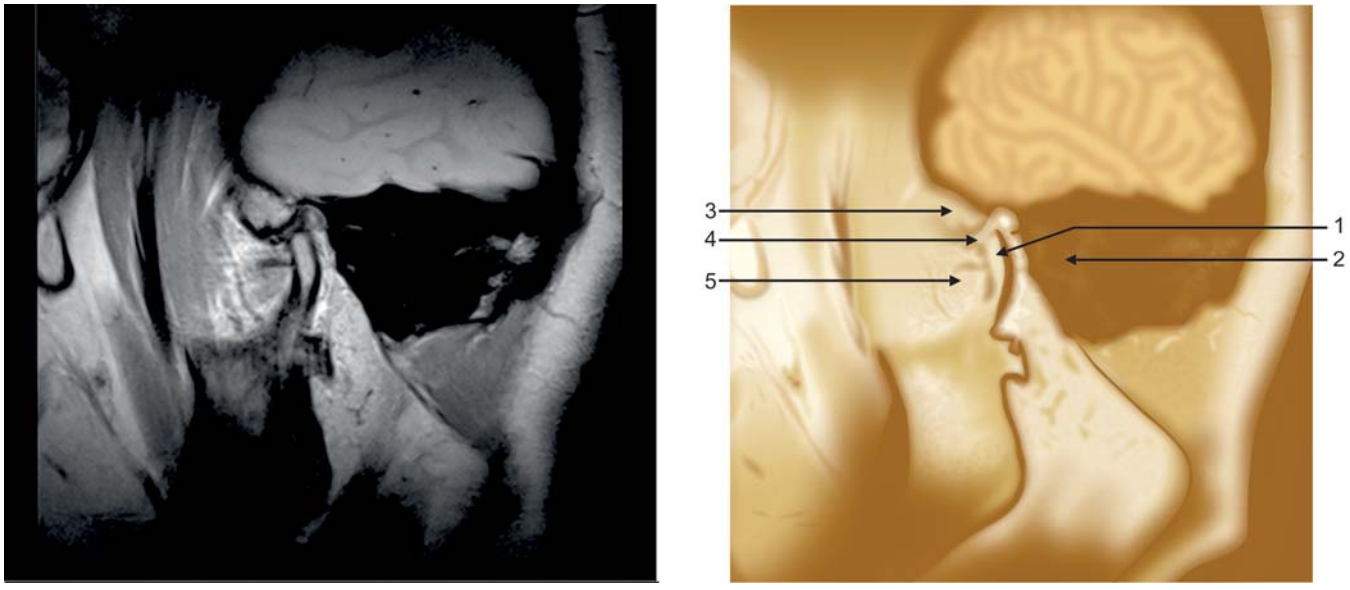

Figure 4.20

1. Head, mandible
2. External auditory canal
3. Articular tubercle
4. Articular disk
5. Lateral pterygoid muscle

CHAPTER 5

Neck



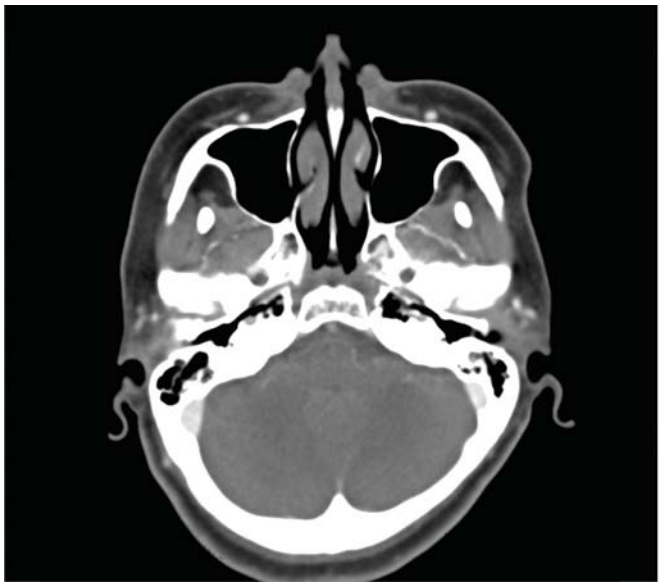

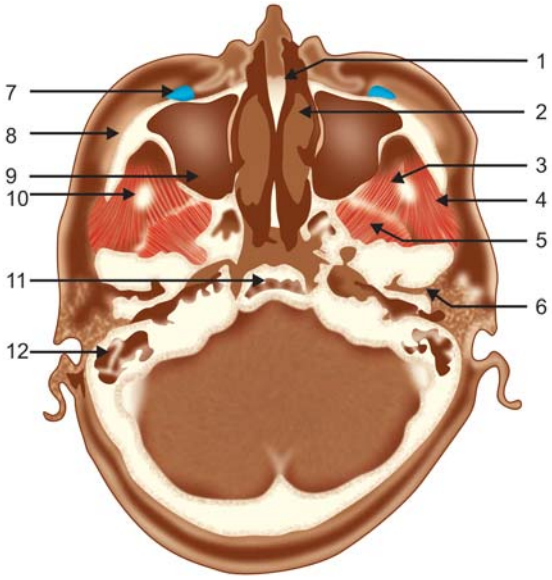

Figure 5.1

1. Nasal septum
2. Inferior turbinate
3. Temporalis muscle
4. Masseter muscle
5. Lateral pterygoid muscle
6. TM joint
7. Facial vein
8. Zygoma
9. Maxillary antrum
10. Coronoid process, mandible
11. Clivus
12. Mastoid sinus

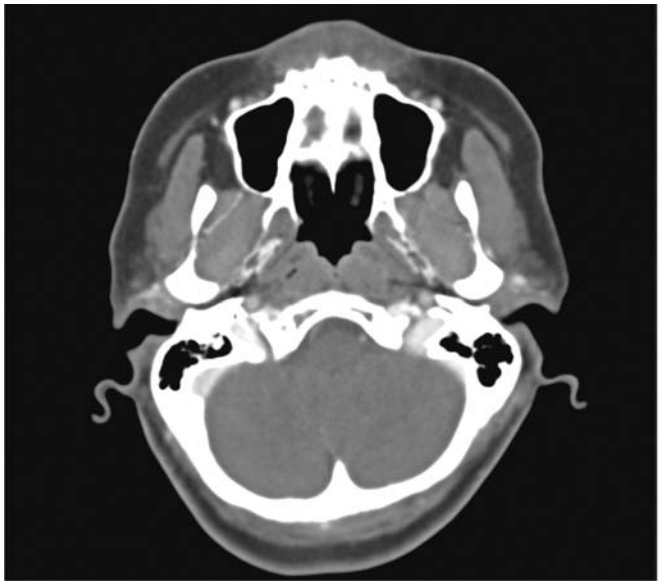

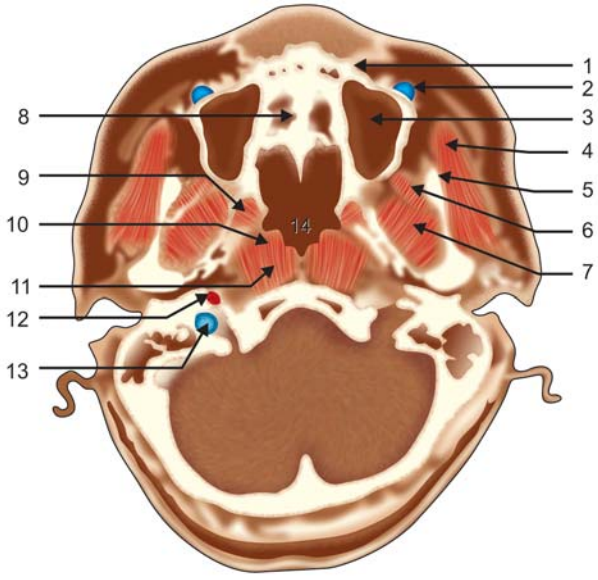

Figure 5.2

1. Alveolar margin, maxilla
2. Facial vein
3. Maxillary antrum
4. Masseter muscle
5. Mandible
6. Temporalis muscle
7. Lateral pterygoid muscle
8. Hard palate
9. Medial pterygoid muscle
10. Torus tubarius
11. Longus capitis/collis muscle
12. Internal carotid artery
13. Jugular fossa

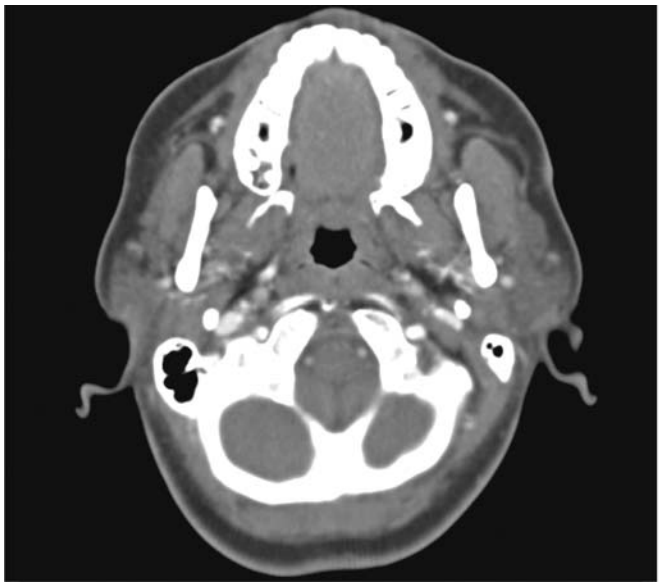

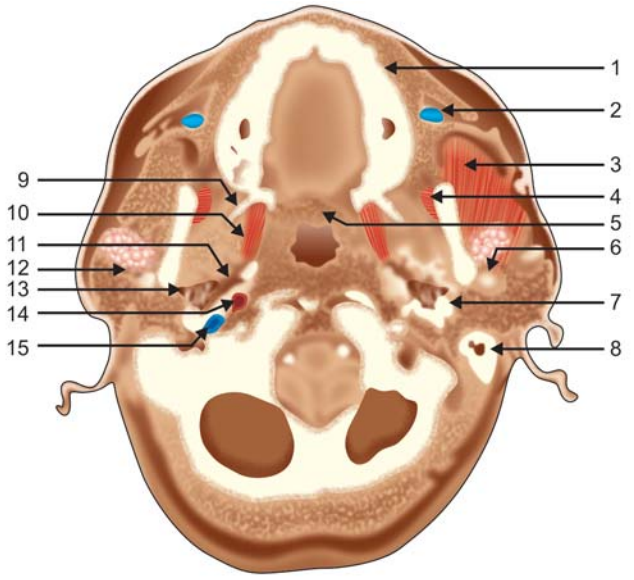

Figure 5.3

1. Maxilla, alveolar margin
2. Facial vein
3. Masseter
4. Temporalis muscle
5. Soft palate
6. Retromandibular vein
7. Styloid process
8. Mastoid
9. Lateral pterygoid plate
10. Medial pterygoid muscle
11. Parapharyngeal space
12. Parotid gland, superficial
13. Parotid gland, deep lobe
14. ICA
15. IJV

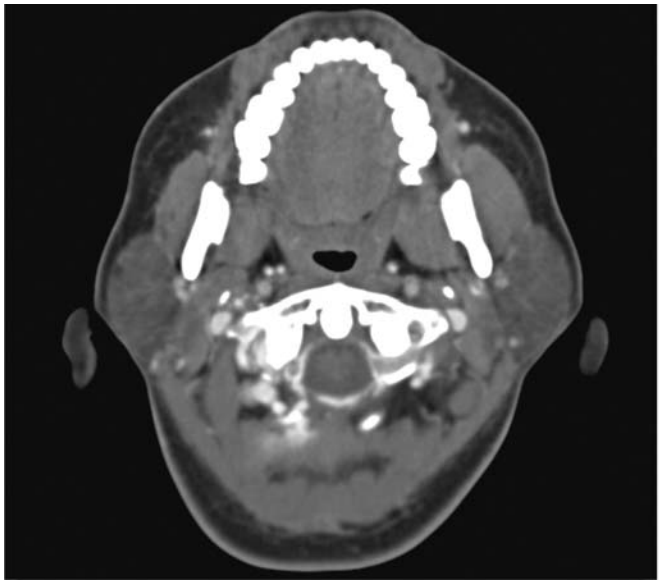

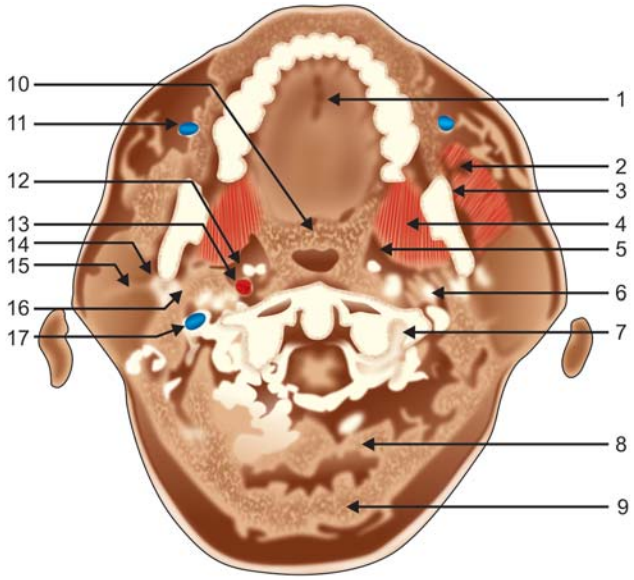

Figure 5.4

1. Tongue
2. Masseter
3. Mandible
4. Medial pterygoid muscle
5. Parapharyngeal space
6. Styloid process
7. Transverse foramen
8. Paraspinal muscles
9. Trapezius muscle
10. Soft palate
11. Facial vein
12. Ascending pharyngeal vessels
13. ICA
14. Retromandibular vein
15. Parotid gland
16. Parotid, deep lobe
17. IJV

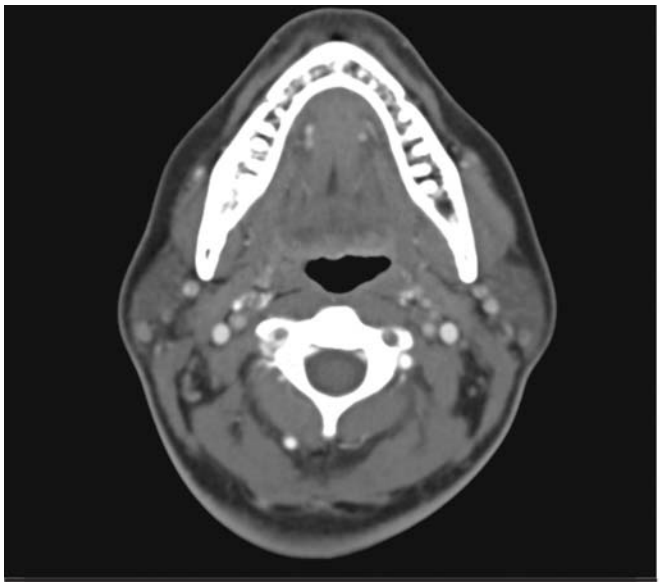

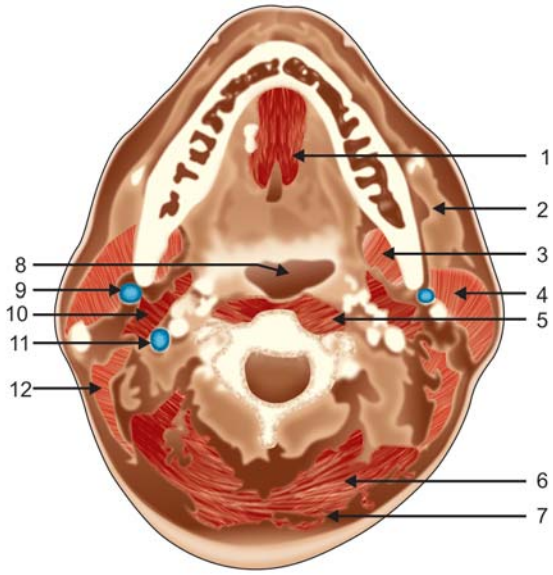

Figure 5.5

1. Genioglossus muscle
2. Masseter muscle
3. Medial pterygoid muscle
4. Parotid gland
5. Longus collis muscle
6. Splenius muscle
7. Trapezius muscle
8. Oropharynx
9. Retromandibular vein
10. Digastric muscle, post belly
11. IJV
12. Sternocleidomastoid muscle

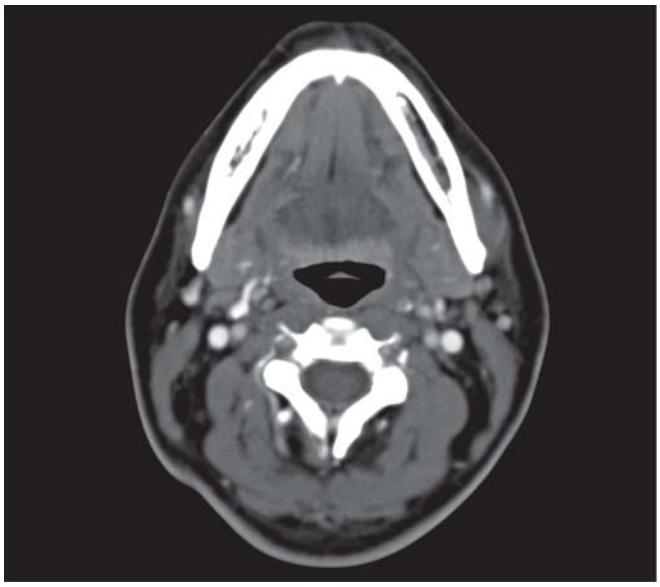

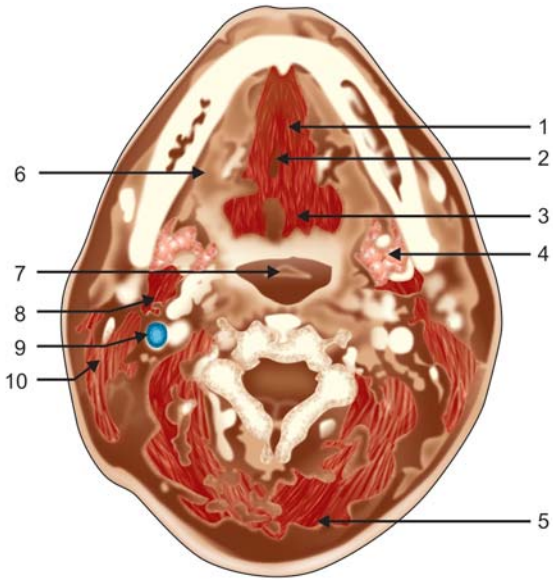

Figure 5.6

1. Genioglossus muscle
2. Lingual septum
3. Hyoglossus muscle
4. Submandibular gland
5. Trapezius muscle
6. Mylohyoid
7. Epiglottis
8. Digastric muscle
9. IJV
10. Sternocleidomastoid muscle

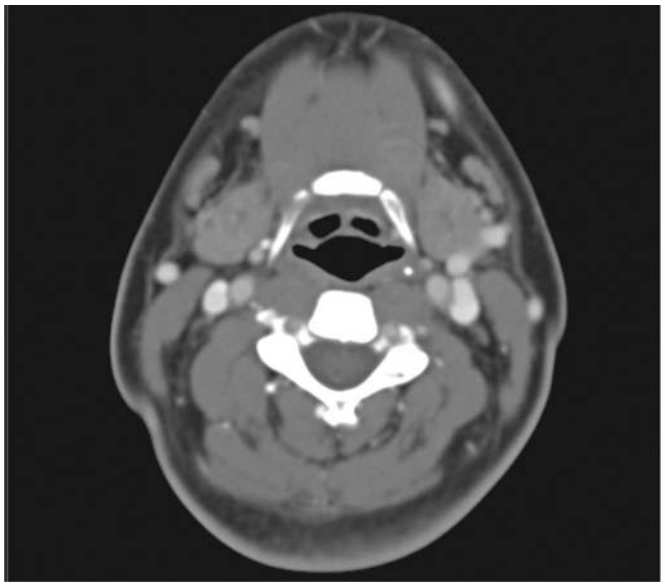

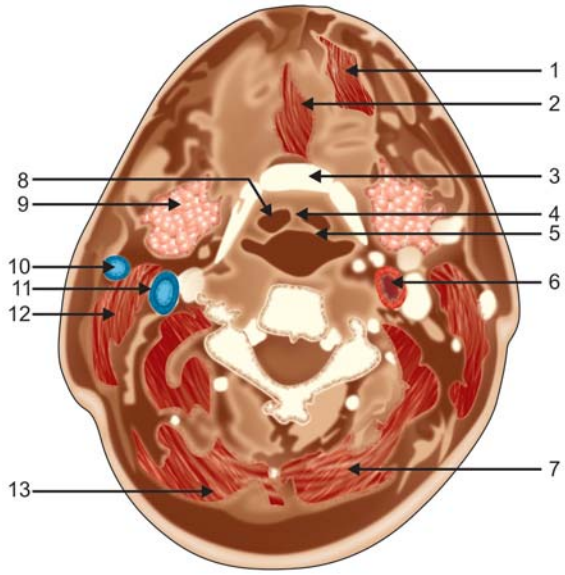

Figure 5.7

1. Digastric muscle
2. Mylohyoid muscle
3. Hyoid bone, body
4. Median glosso-epiglottic fold
5. Epiglottis
6. Carotid artery
7. Splenius muscle
8. Vallecula
9. Submandibular gland
10. External jugular vein
11. Internal jugular vein
12. Sternocleidomastoid muscle
13. Trapezius muscle

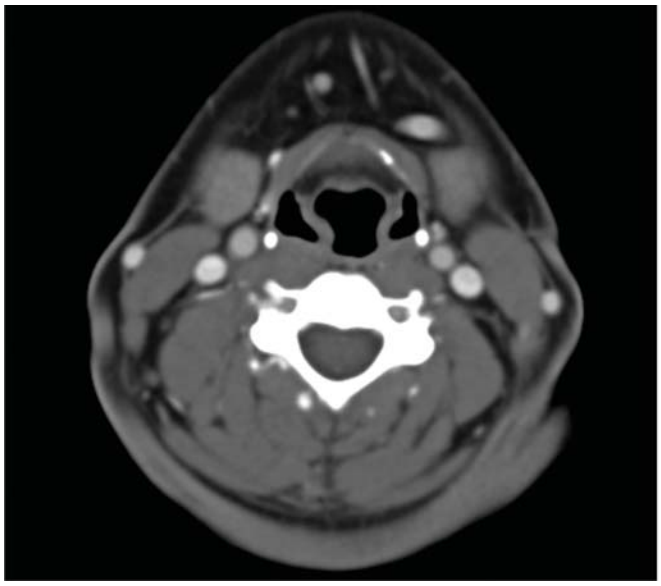

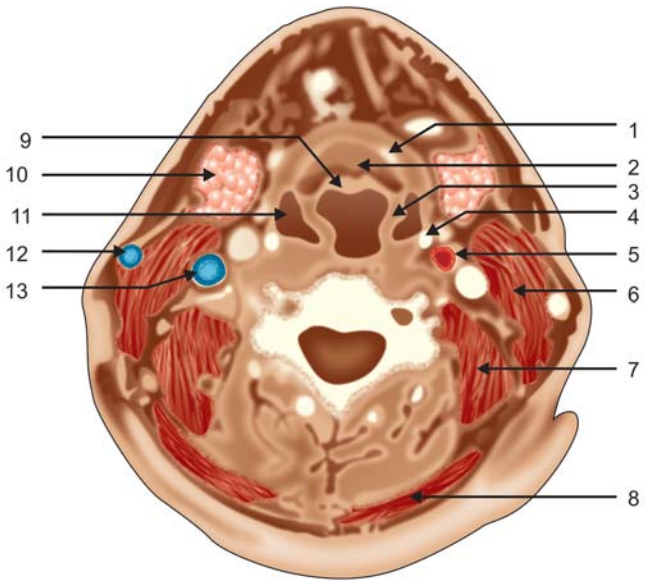

Figure 5.8

1. Thyroid cartilage
2. Preepiglottic space
3. Aryepiglottic fold
4. Superior horn, thyroid cartilage
5. Common carotid artery
6. Sternocleidomastoid muscle
7. Levator scapulae
8. Trapezius
9. Epiglottis
10. Submandibular gland
11. Pyriform sinus
12. External jugular vein
13. Internal jugular vein

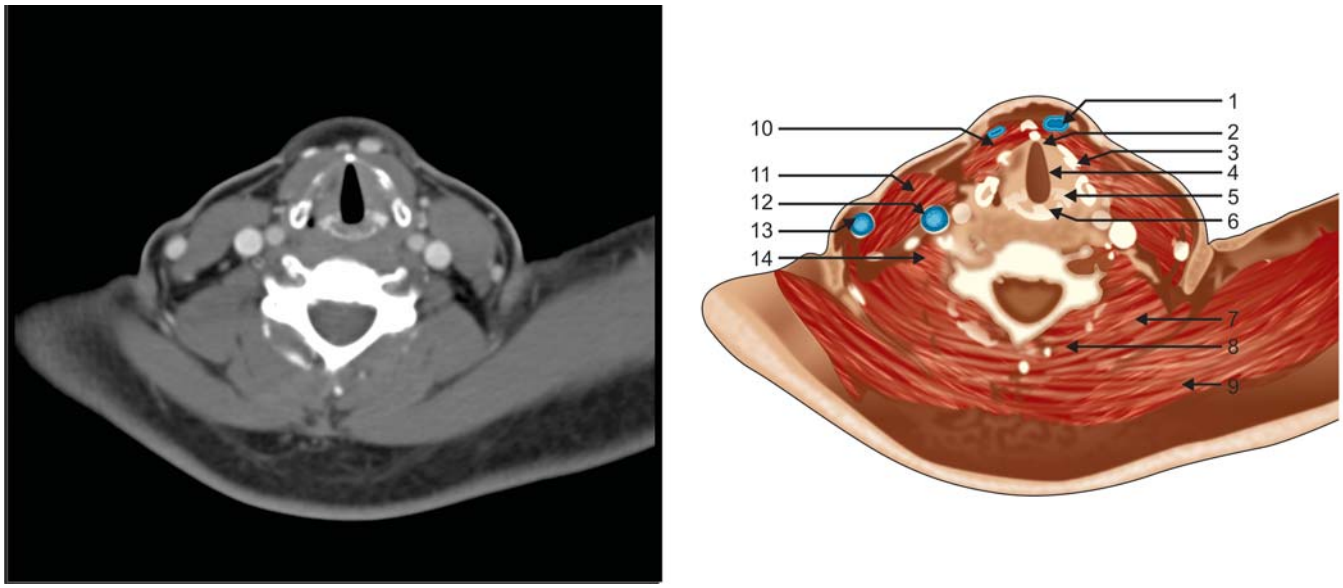

Figure 5.9

1. Anterior jugular vein
2. Anterior commissure
3. Thyroid cartilage
4. Vocal cord
5. Arytenoid cartilage
6. Cricoid cartilage
7. Levator scapulae
8. Paraspinal muscles
9. Trapezius muscle
10. Strap muscles
11. Sternocleidomastoid muscle
12. Internal jugular vein
13. External jugular vein
14. Middle scalene muscle

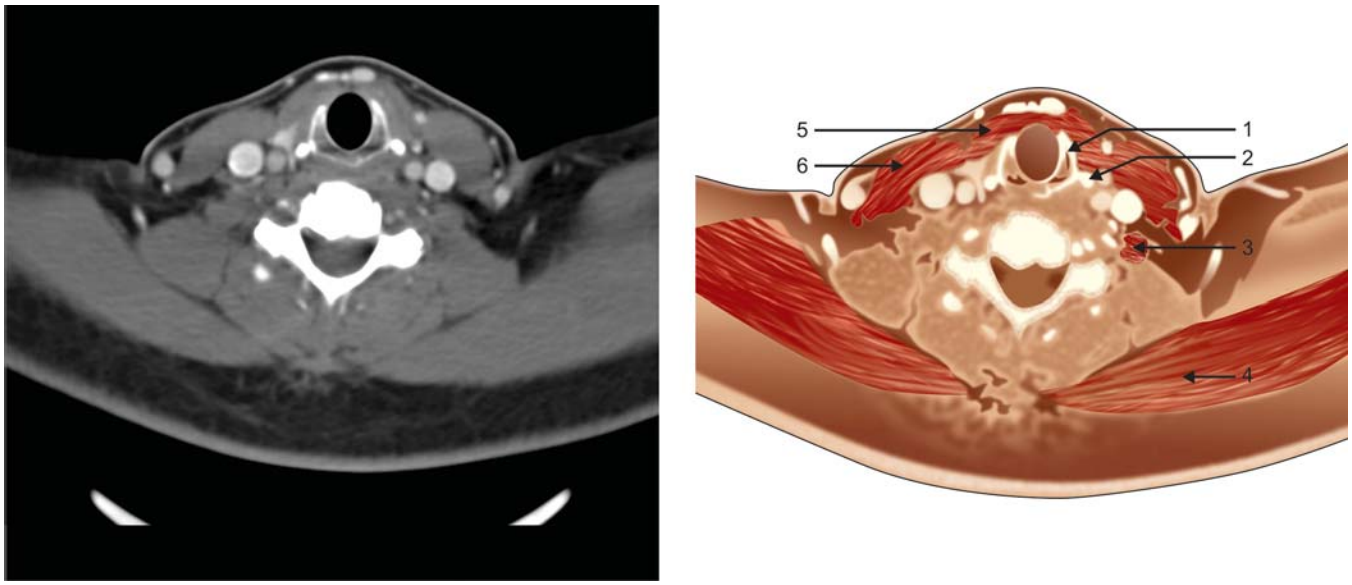

Figure 5.10

1. Cricoid cartilage
2. Inferior horn of thyroid cartilage
3. Middle scalene muscle
4. Trapezius muscle
5. Strap muscle
6. Sternocleidomastoid muscle

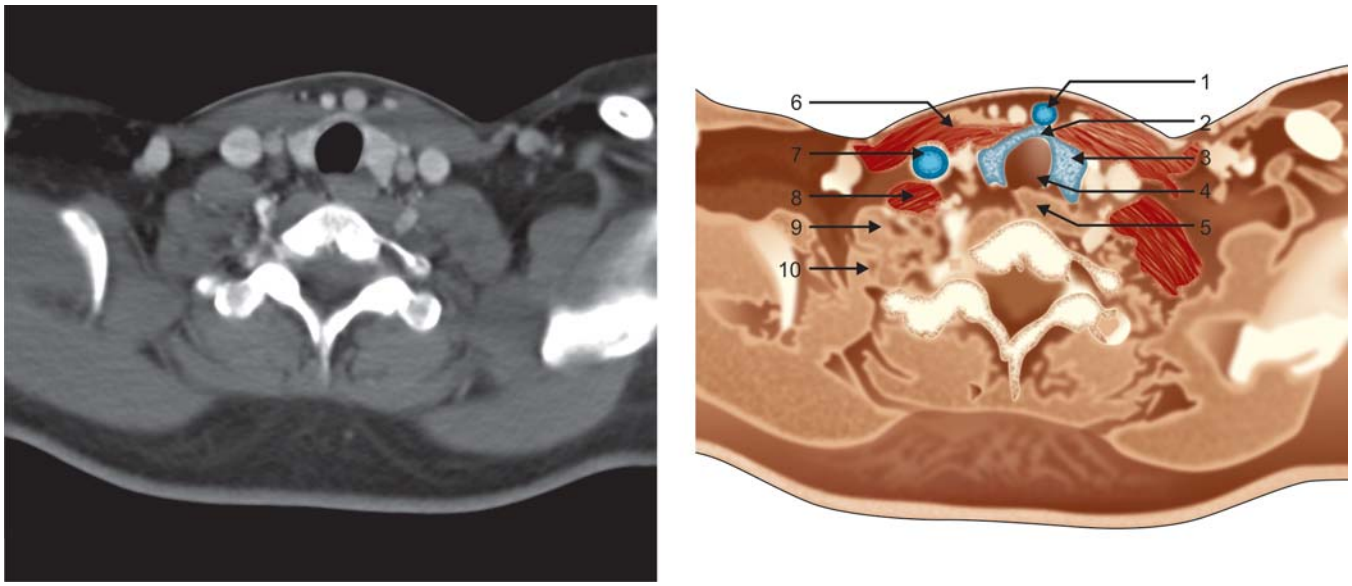

Figure 5.11

1. Anterior jugular vein
2. Thyroid isthmus
3. Thyroid gland, left lobe
4. Trachea
5. Esophagus
6. Sternocleidomastoid muscle
7. Internal jugular vein
8. Scalene muscles, anterior
9. Middle scalene muscle
10. Posterior scalene muscle

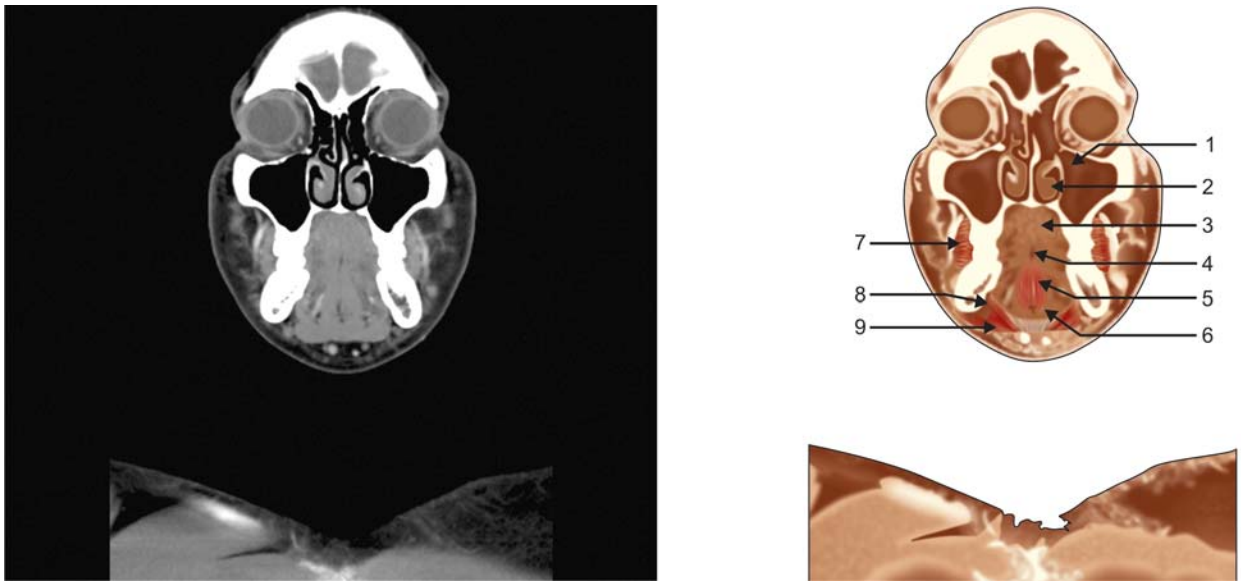

Figure 5.12

1. Maxillary antrum
2. Inferior turbinate
3. Tongue
4. Lingual septum
5. Genioglossus muscle
6. Geniohyoid muscle
7. Buccinator muscle
8. Mylohyoid muscle
9. Digastric muscle, anterior belly

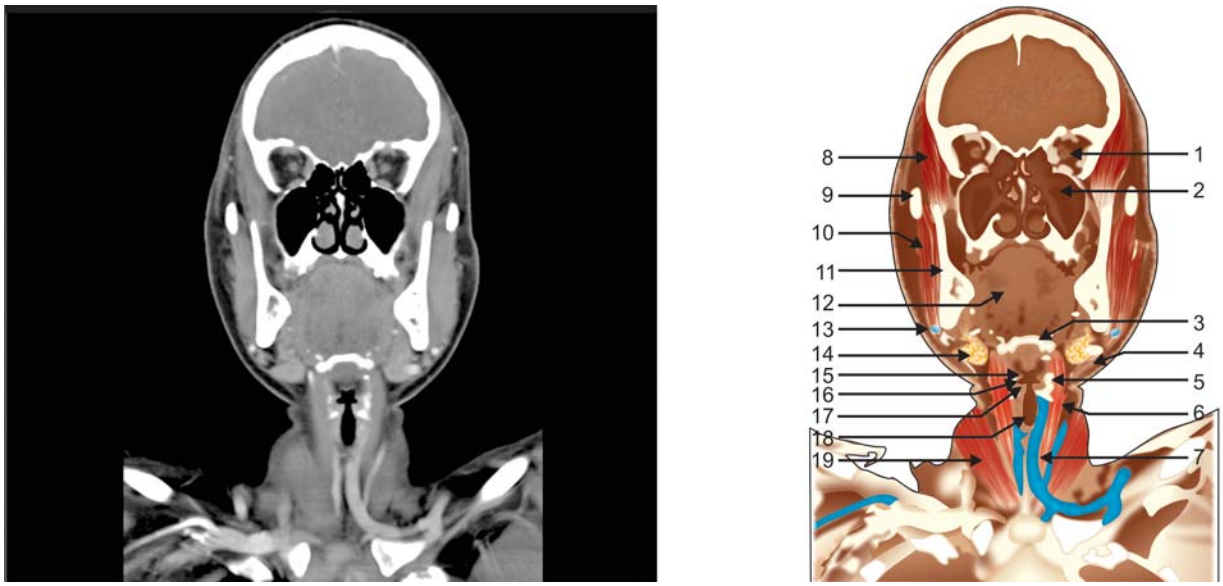

Figure 5.13

1. Optic nerve
2. Maxillary antrum
3. Hyoid bone
4. Platysma
5. Thyroid cartilage
6. Sternothyroid muscle
7. Anterior jugular vein
8. Temporalis muscle
9. Zygomatic arch
10. Masseter muscle
11. Mandible
12. Tongue
13. Facial vein
14. Submandibular gland
15. False vocal cord
16. Laryngeal ventricle
17. True vocal cord
18. Trachea
19. Sternocleidomastoid muscle

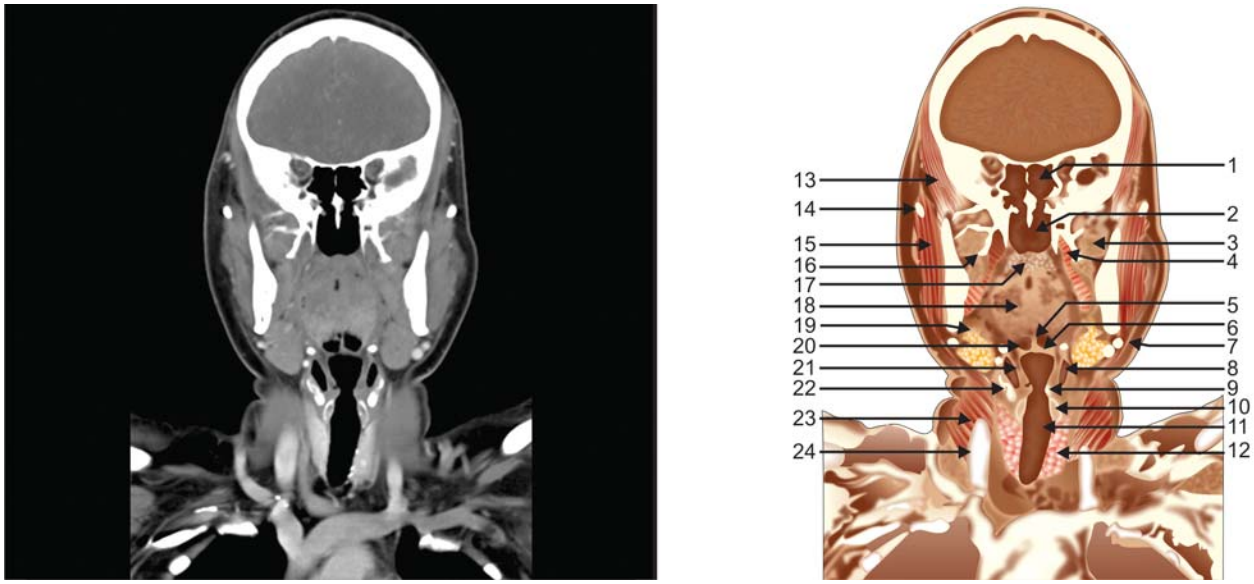

Figure 5.14

1. Ethmoid sinus
2. Nasopharynx
3. Lateral pterygoid muscle
4. Medial pterygoid muscle
5. Median glossoepiglottic fold
6. Epiglottis
7. Platysma muscle
8. Pyriform sinus
9. True vocal cord
10. Cricoid cartilage
11. Trachea
12. Thyroid lobe
13. Temporalis muscle
14. Zygomatic arch
15. Masseter muscle
16. Lateral pterygoid plate
17. Soft palate
18. Tongue
19. Submandibular gland
20. Vallecula
21. Aryepiglottic fold
22. Thyroid cartilage
23. Sternocleidomastoid muscle
24. Internal jugular vein

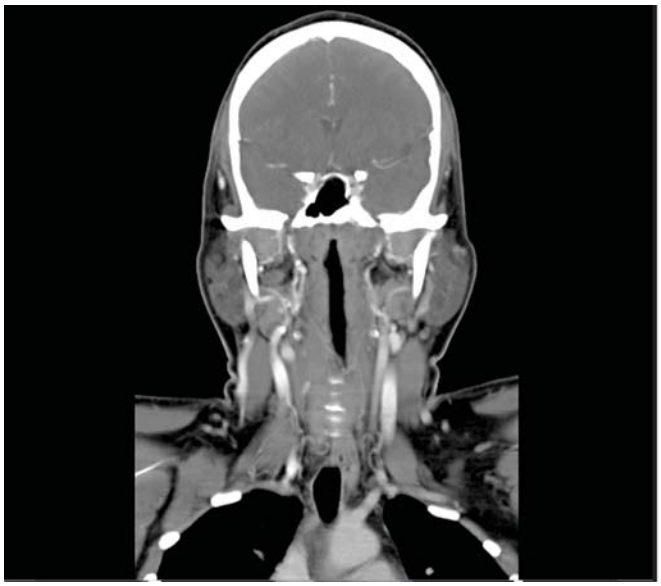

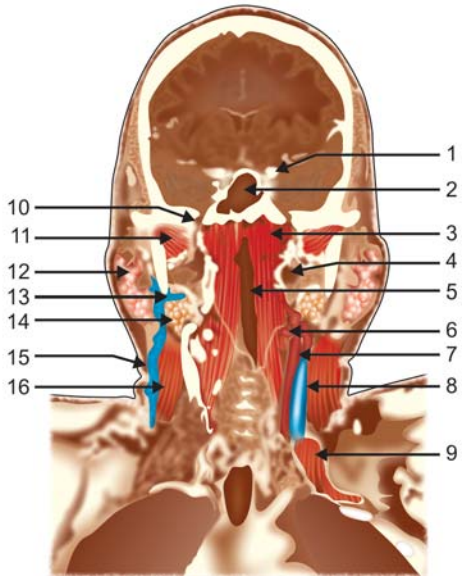

Figure 5.15

1. Anterior clinoid
2. Sphenoid sinus
3. Longus capitis
4. Parapharyngeal space
5. Pharynx
6. Hyoid bone, cornu
7. Carotid artery
8. Internal jugular vein
9. Scalenus anterior muscle
10. Foramen ovale
11. Lateral pterygoid muscle
12. Parotid gland
13. Retromandibular vein
14. Submandibular gland
15. External jugular vein
16. Sternocleidomastoid muscle

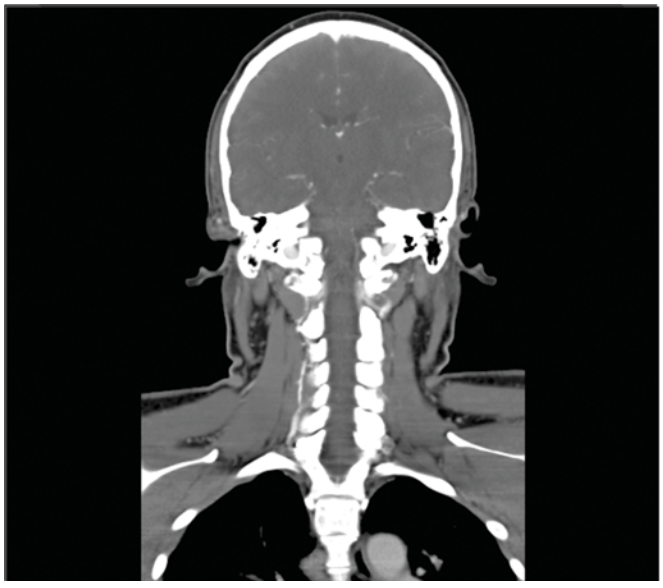

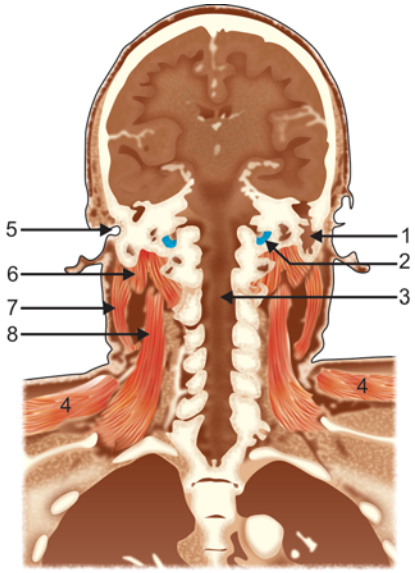

Figure 5.16

1. Mastoid sinus
2. Internal Jugular vein
3. Spinal cord
4. Trapezius
5. External auditory canal
6. Digastric muscle
7. Sternocleidomastoid muscle
8. Levator scapulae

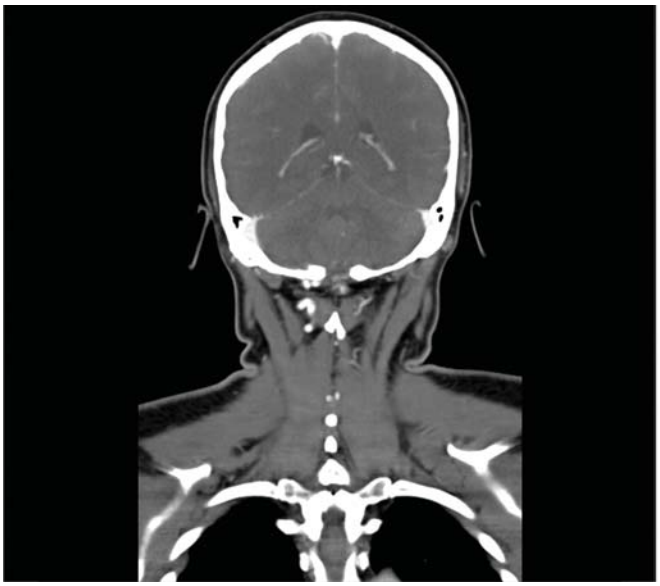

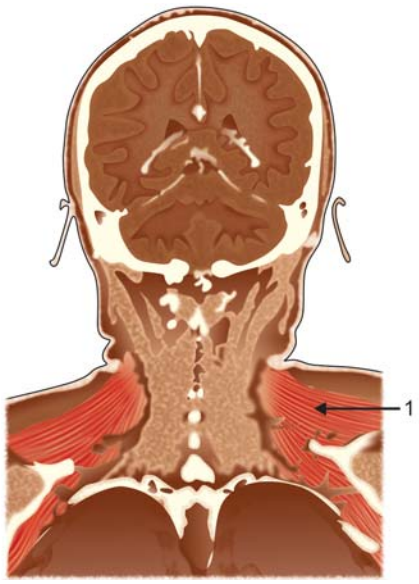

Figure 5.17

1. Trapezius

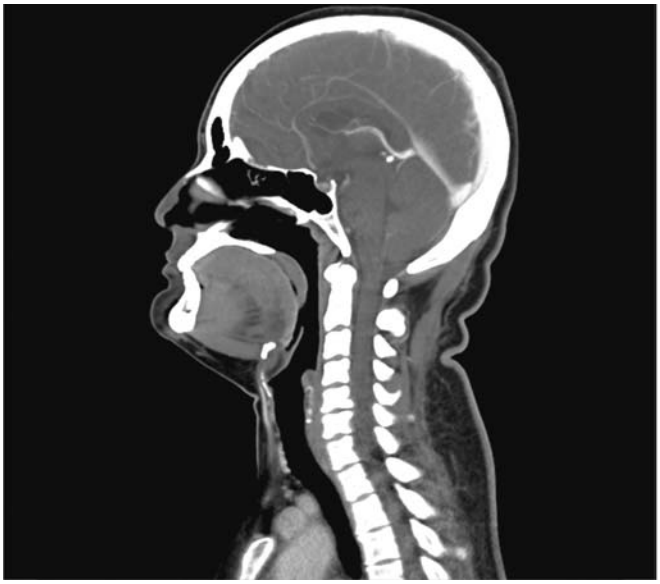

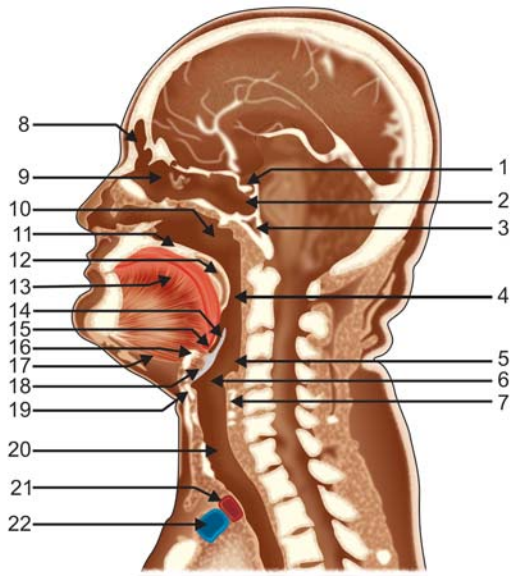

Figure 5.18

1. Pituitary gland
2. Sphenoid sinus
3. Clivus
4. Oropharynx
5. Hypopharynx
6. Larynx
7. Cricoid cartilage
8. Frontal sinus
9. Ethmoid sinuses
10. Nasopharynx
11. Hard palate
12. Soft palate
13. Tongue
14. Epiglottis
15. Vallecula
16. Hyoid bone
17. Mylohyoid muscle
18. Preepiglottic space
19. Thyroid cartilage
20. Trachea
21. Bracheocephalic artery
22. Bracheocephalic vein

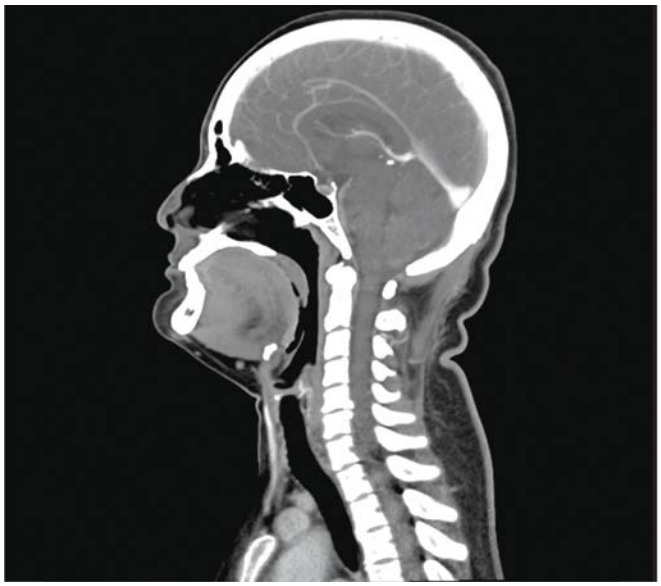

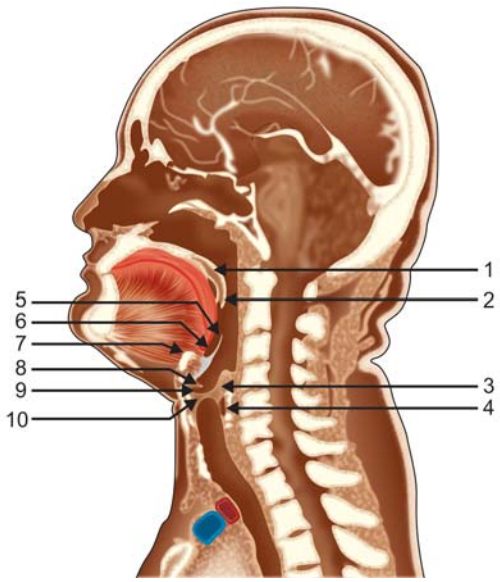

Figure 5.19

1. Soft palate
2. Uvula
3. Arytenoid cartilage
4. Cricoid cartilage
5. Epiglottis
6. Vallecula
7. Hyoid
8. False vocal cord
9. Laryngeal ventricle
10. True vocal cord



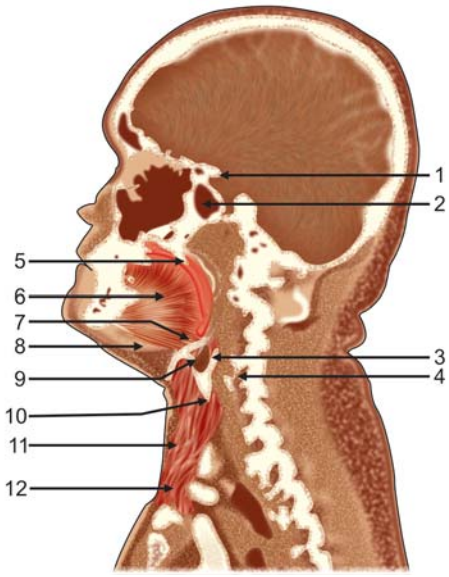

Figure 5.20

1. Anterior clinoid
2. Sphenoid sinus
3. Superior horn, thyroid cartilage
4. Vertebral artery
5. Hard palate
6. Tongue
7. Hyoid bone
8. Mylohyoid muscle
9. Pyriform sinus
10. Thyroid cartilage
11. Strap muscles
12. Sternocleidomastoid muscle

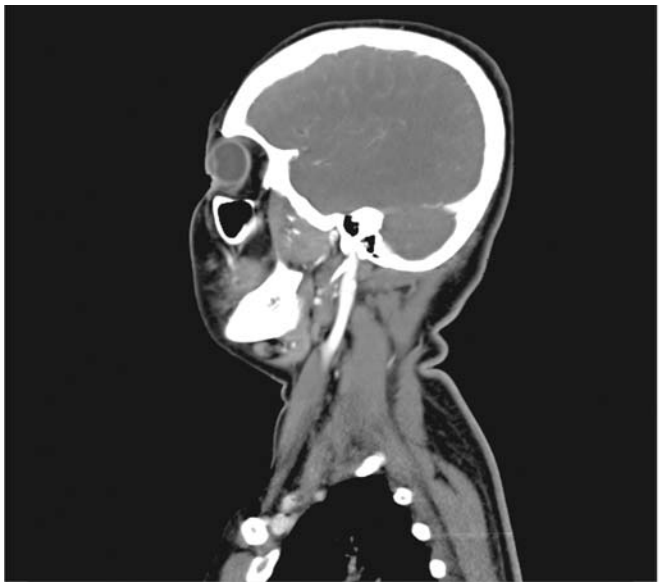

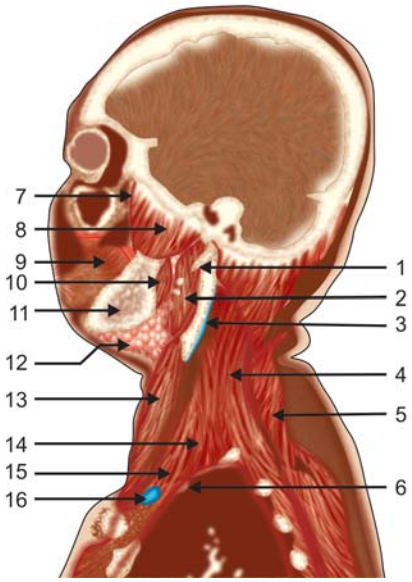

Figure 5.21

1. Styloid process
2. Digastric muscle
3. Internal jugular vein
4. Levator scapulae
5. Trapezius muscle
6. Subclavian artery
7. Temporalis muscle
8. Lateral pterygoid muscle
9. Buccinator muscle
10. Medial pterygoid muscle
11. Mandible
12. Submandibular gland
13. Sternocleidomastoid muscle
14. Scalenus medius muscle
15. Scalenus anterior muscle
16. Subclavian vein

Section 2



Spine

- **Spine**

CHAPTER 6

Spine

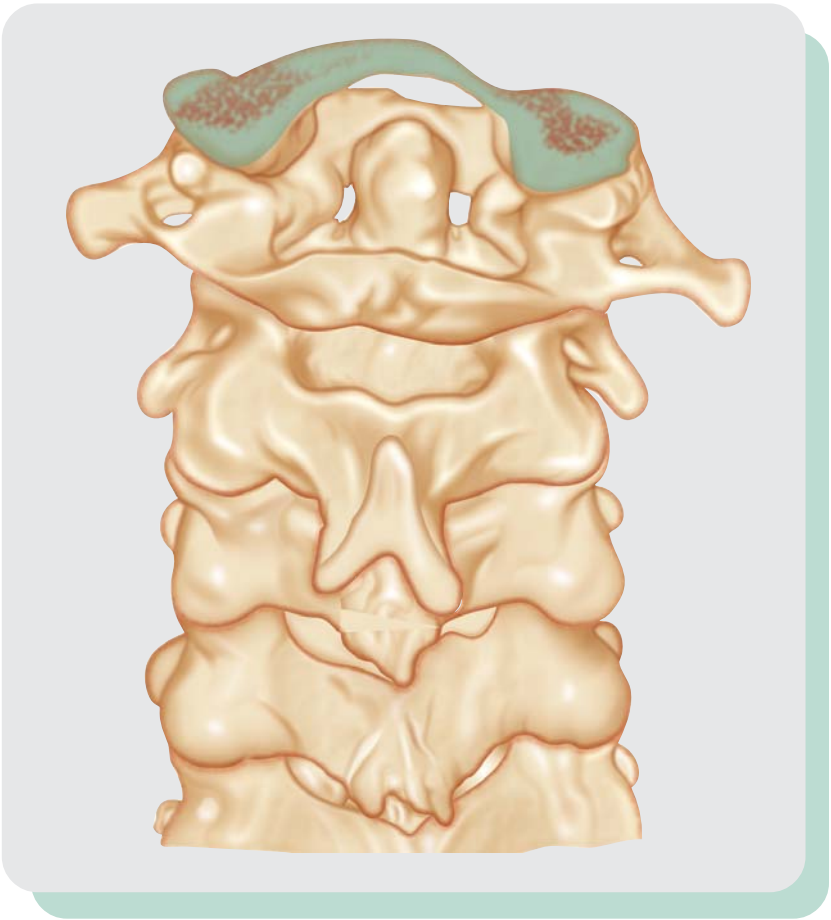

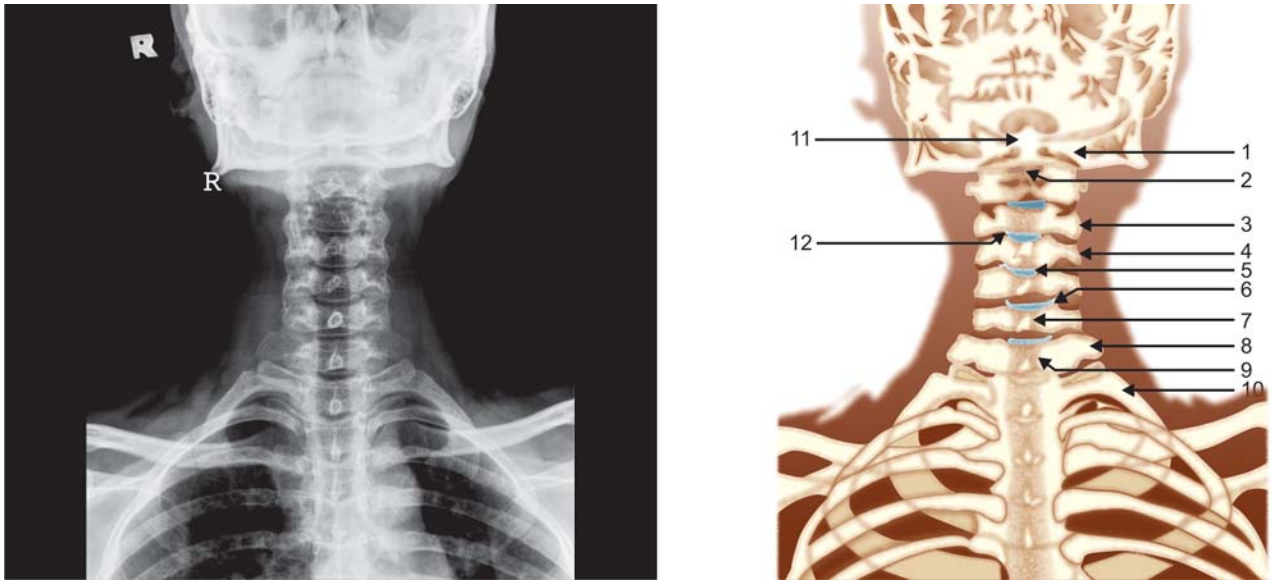

Figure 6.1

1. Lateral mass of atlas
2. C2 body
3. Facet joint
4. Transverse process
5. Disk space
6. Uncinate process
7. Spinous process
8. C7 transverse process
9. Trachea
10. First rib
11. Dens
12. Uncovertebral joint

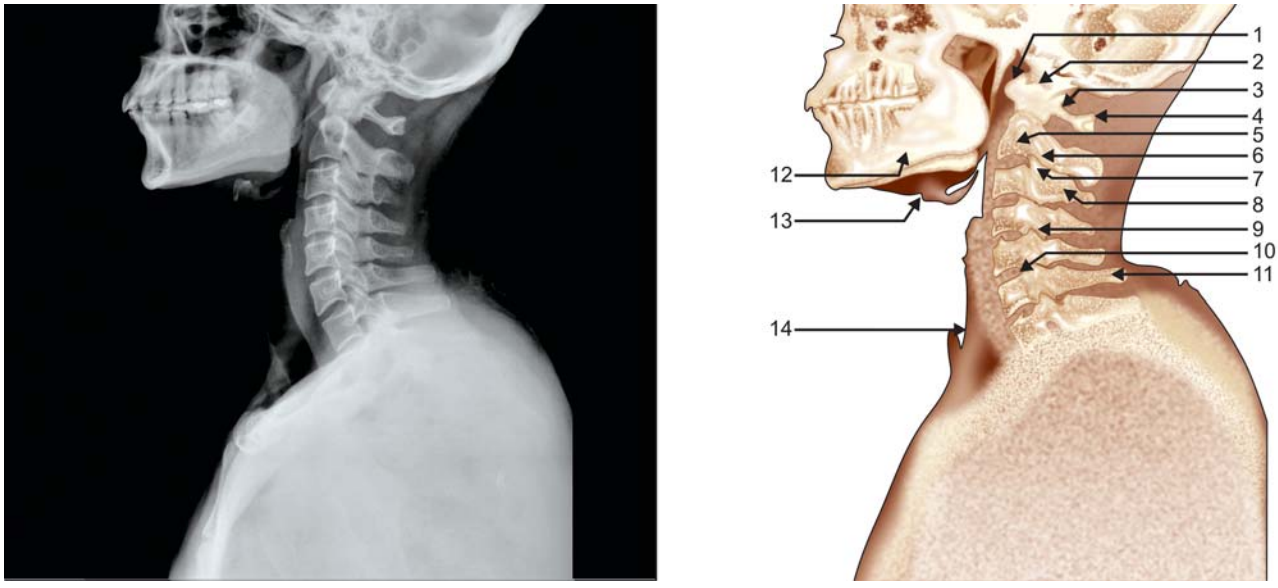

Figure 6.2

1. Anterior tubercle of atlas
2. Dens
3. Posterior arch of atlas
4. Posterior tubercle of atlas
5. C2 vertebra
6. Inferior facet
7. Superior facet
8. Spinolaminar line
9. Facet joint
10. Disk space
11. Spinous process
12. Mandible
13. Hyoid
14. Trachea



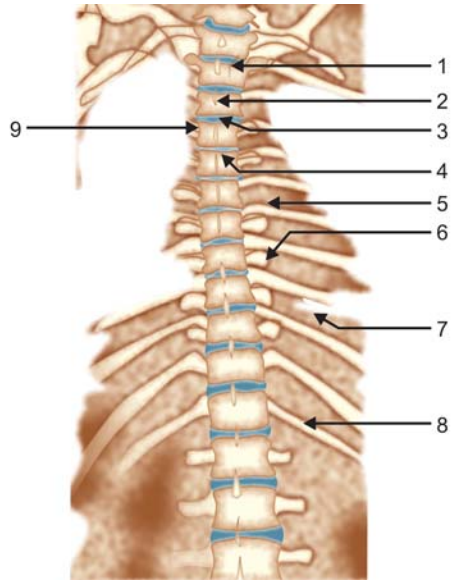

Figure 6.3

1. Trachea
2. Spinous process
3. Disk space
4. Carina
5. Aortic shadow
6. Transverse process
7. Left diaphragm
8. 12th rib
9. Pedicle



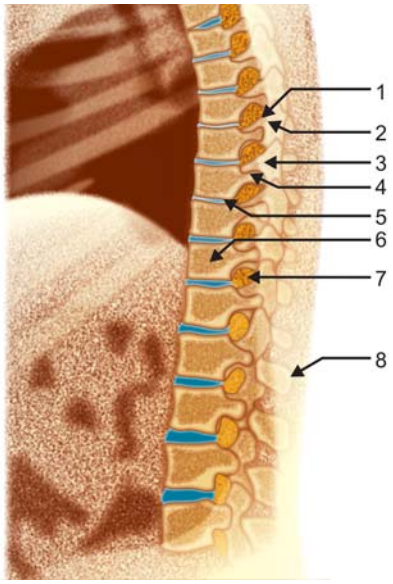

Figure 6.4

1. Superior facet
2. Inferior facet
3. Facet joint
4. Pedicle
5. Disk space
6. Vertebral body
7. Intervertebral foramen
8. Spinous process

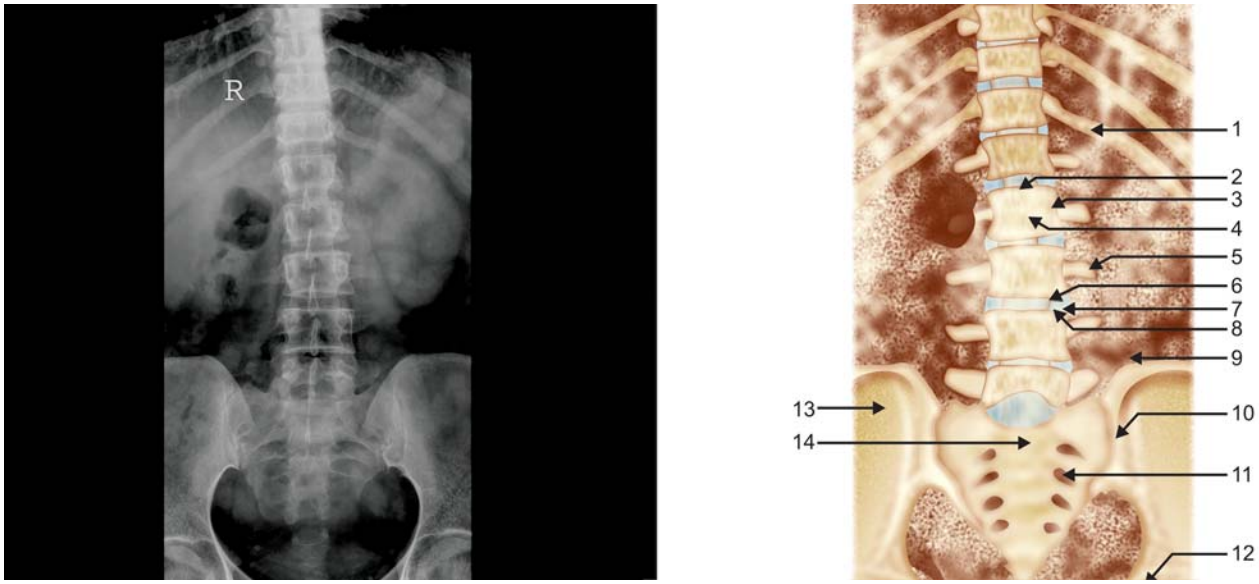

Figure 6.5

1. Twelfth rib
2. Spinous process L1
3. Pedicle
4. Lamina L2
5. Transverse process
6. Inferior facet
7. Superior facet
8. Facet joint
9. Psoas
10. SI joint
11. Sacral foramen
12. Hip joint
13. Ileum
14. Sacrum

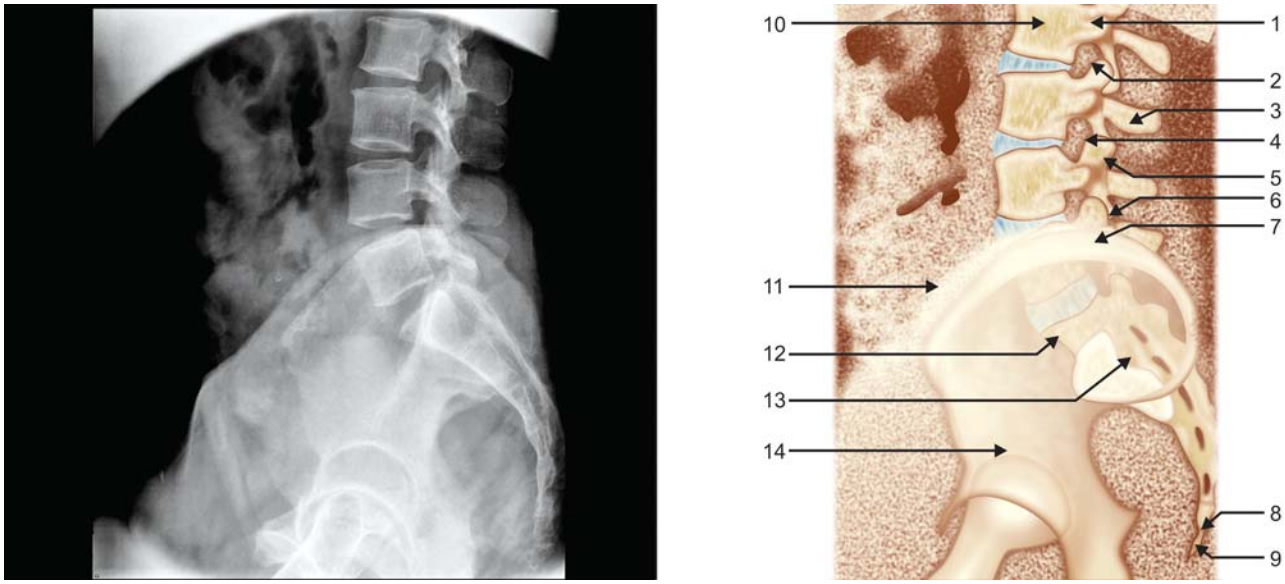

Figure 6.6

1. Pedicle
2. Intervertebral foramen
3. Spinous process
4. Superior facet L4
5. Inferior facet L3
6. Facet joint
7. Pars interarticularis
8. Sacrococcygeal joint
9. Coccyx
10. L2 body
11. Iliac crest
12. Sacral promontory
13. S2
14. Hip joint

CERVICAL SPINE CT

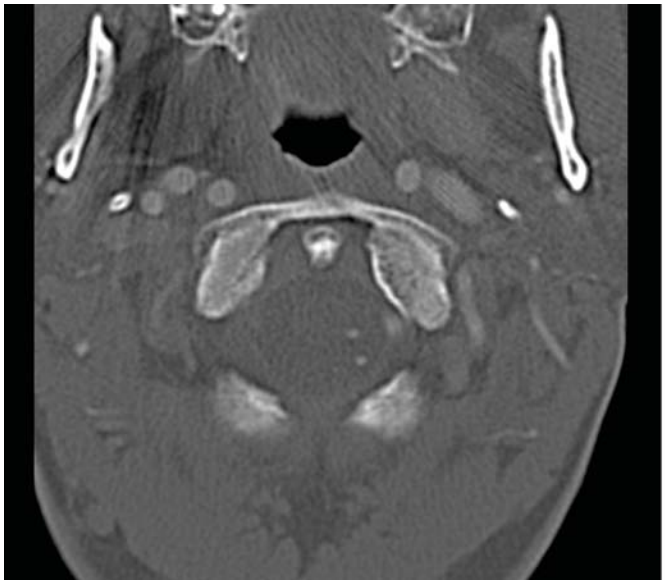

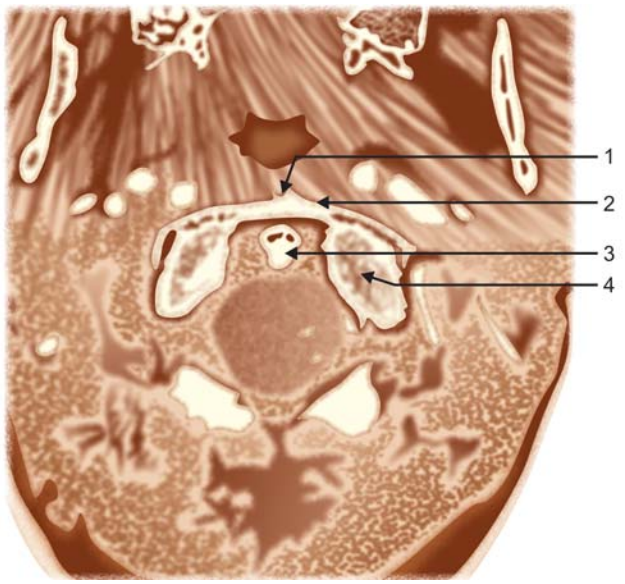

Figure 6.7

1. Anterior tubercle of atlas
2. Anterior arch of atlas
3. Dens
4. Occipital condyle

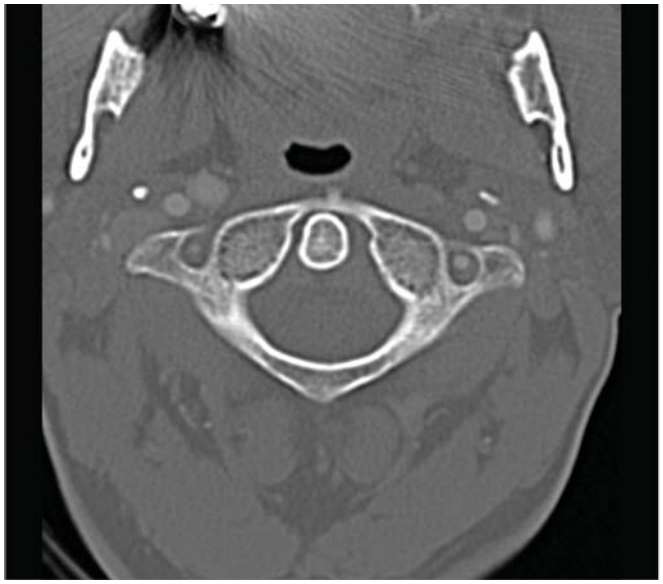

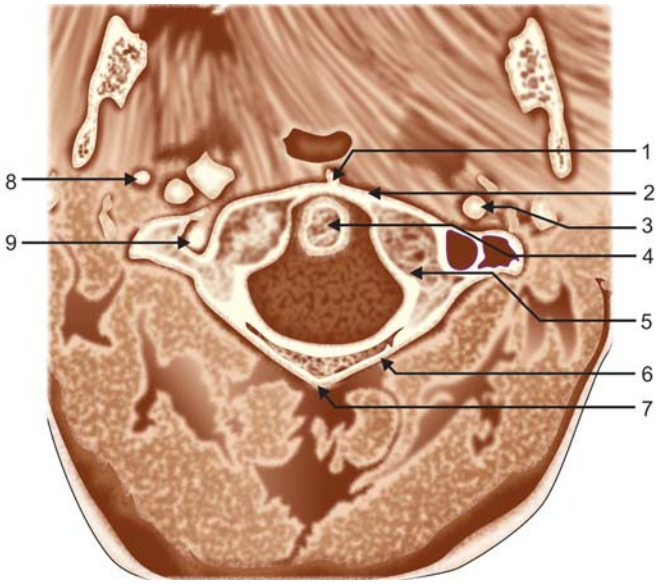

Figure 6.8

1. Anterior tubercle C1
2. Anterior arch of atlas
3. ICA
4. Dens
5. Lateral mass C1
6. Posterior arch of atlas
7. Posterior tubercle
8. Styloid process
9. Vertebral artery

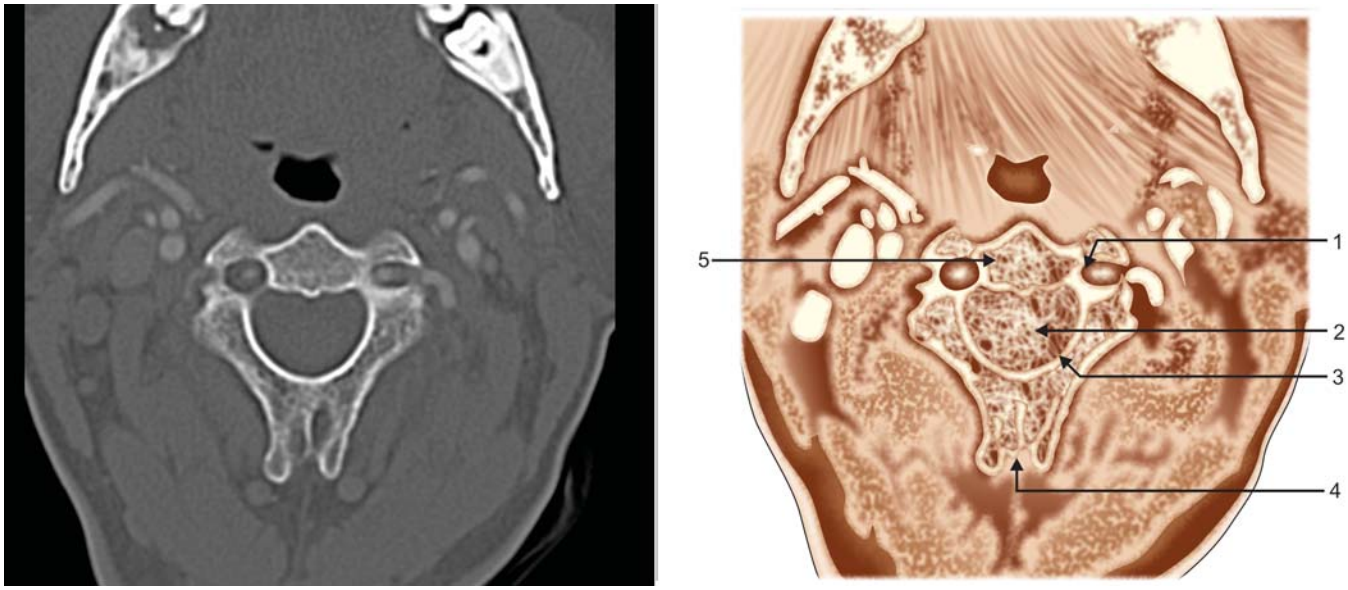

Figure 6.9

1. Vertebral artery in transverse foramen
2. Spinal canal
3. Lamina
4. Spinous process
5. C2 body

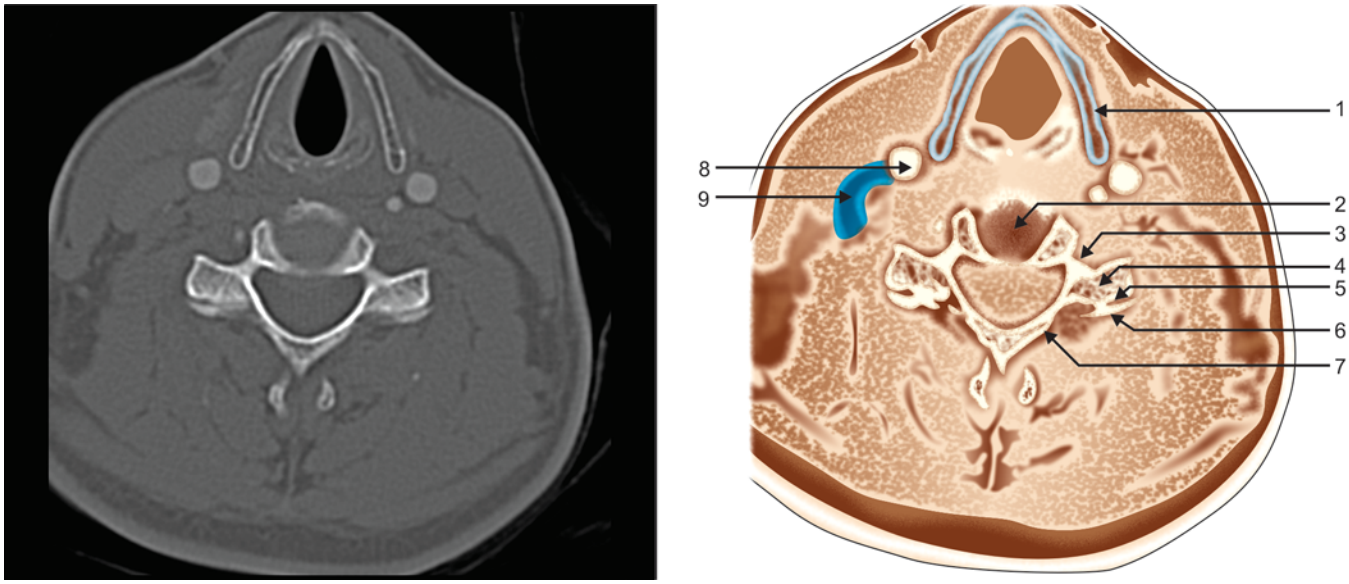

Figure 6.10

1. Thyroid cartilage
2. Intervertebral disk
3. Pedicle
4. Superior facet
5. Facet joint
6. Inferior facet
7. Lamina
8. Common carotid artery
9. Internal jugular vein

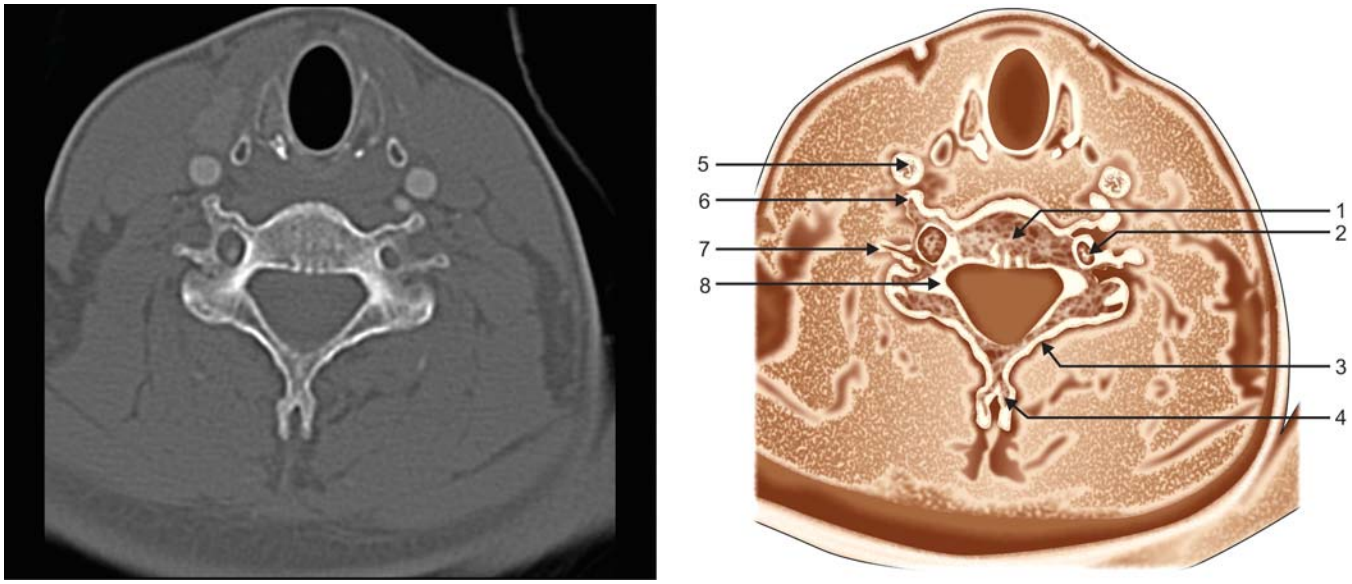

Figure 6.11

1. Vertebral body
2. Foramen transversarium
3. Lamina
4. Spinous process
5. CCA
6. Anterior tubercle of transverse process
7. Posterior tubercle of transverse process
8. Pedicle

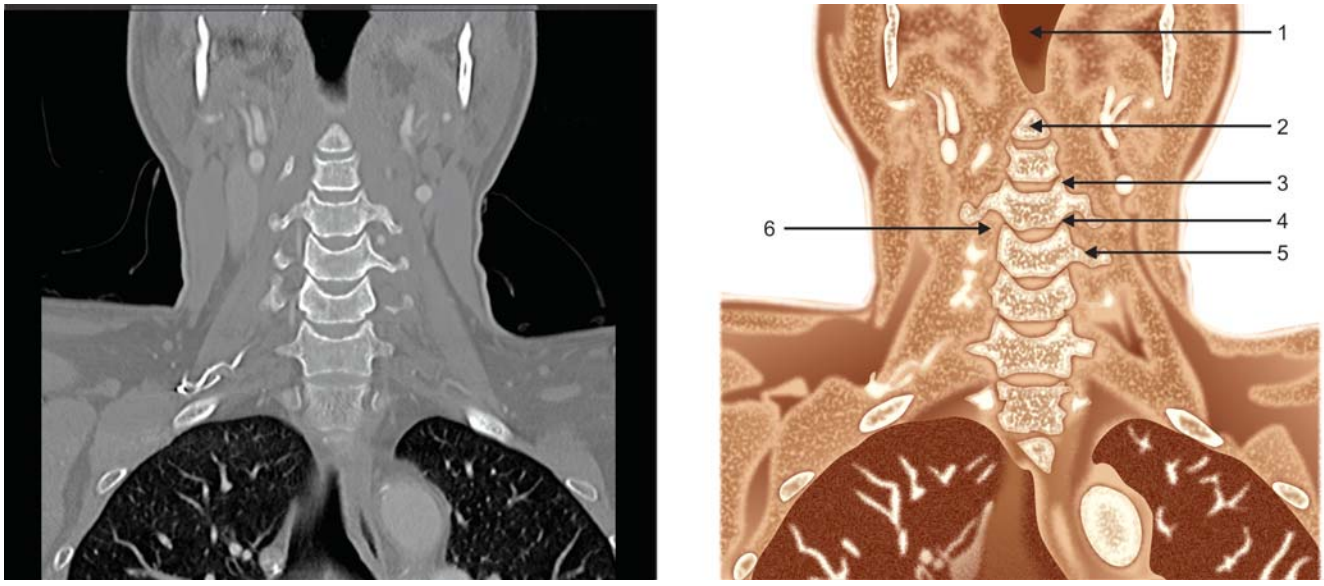

Figure 6.12

1. Pharynx
2. C2 body
3. Uncinate process
4. Uncovertebral joint
5. Transverse process
6. Vertebral artery



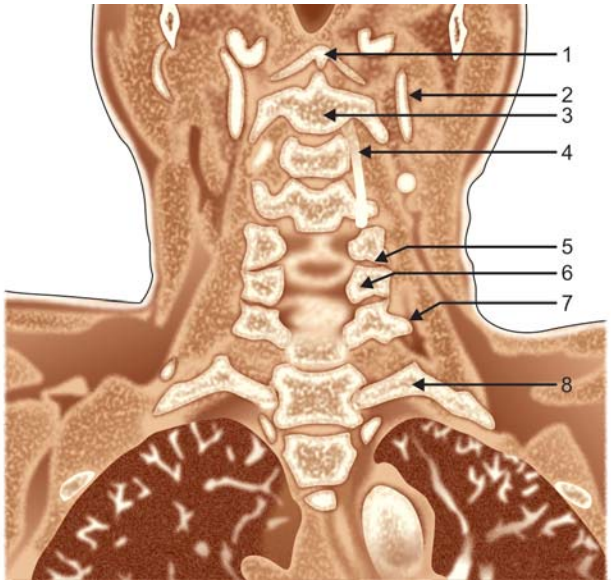

Figure 6.13

1. Anterior tubercle of atlas
2. ICA
3. C2
4. Vertebral artery
5. Facet joint
6. Pedicle
7. Transverse process C7
8. First rib



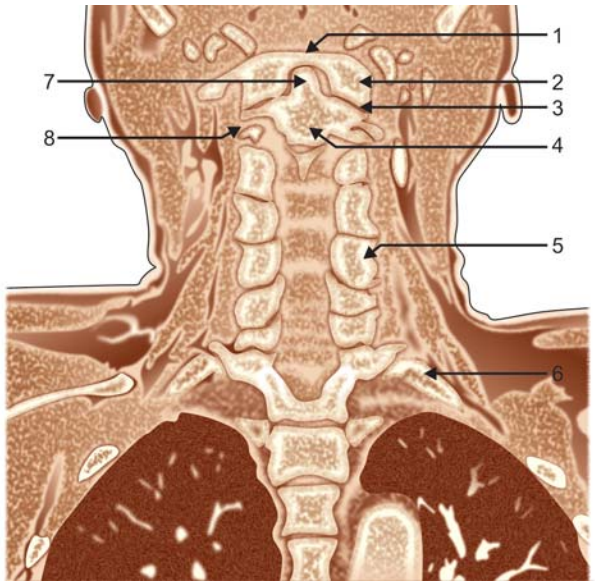

Figure 6.14

1. Anterior arch of atlas
2. Lateral mass of atlas
3. Atlantoaxial joint
4. C2
5. Articular pillar
6. First rib
7. Dens
8. Vertebral artery



Figure 6.15

1. Atlantoaxial joint
2. C2
3. C3 lamina
4. Spinous process
5. T1 transverse process
6. Dens

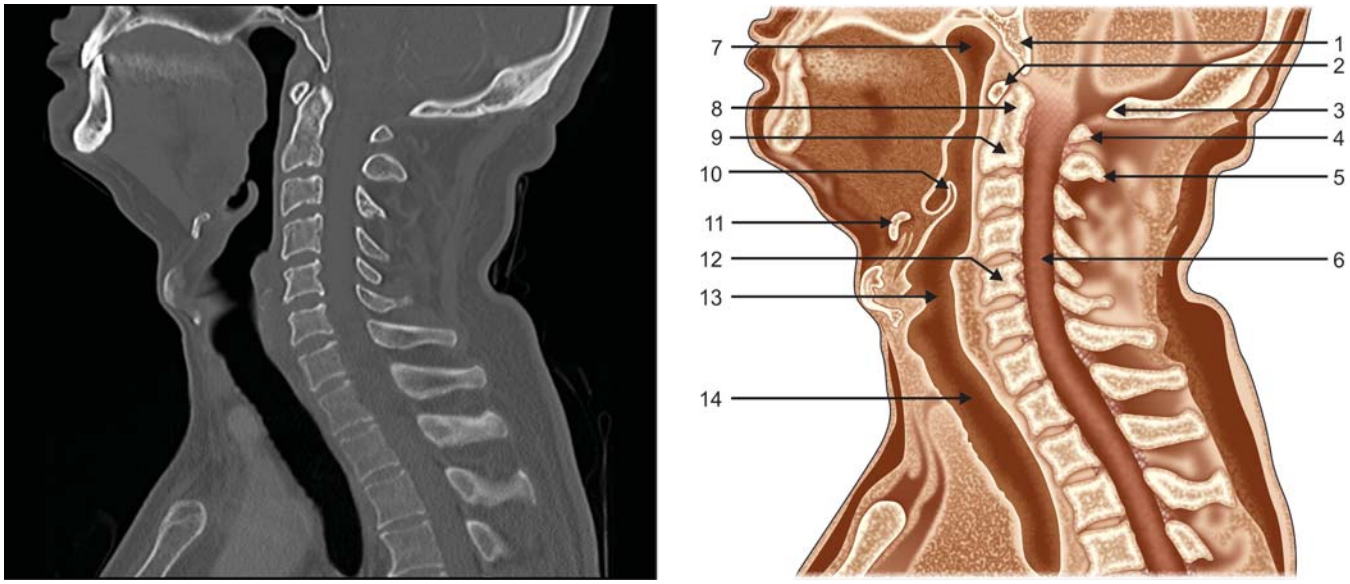

Figure 6.16

1. Clivus
2. Anterior tubercle of atlas
3. Posterior margin of foramen magnum
4. Posterior tubercle of atlas
5. C2 spinous process
6. Spinal canal
7. Nasopharynx
8. Dens
9. C2 body
10. Epiglottis
11. Hyoid
12. C5 vertebra
13. Glottis
14. Trachea

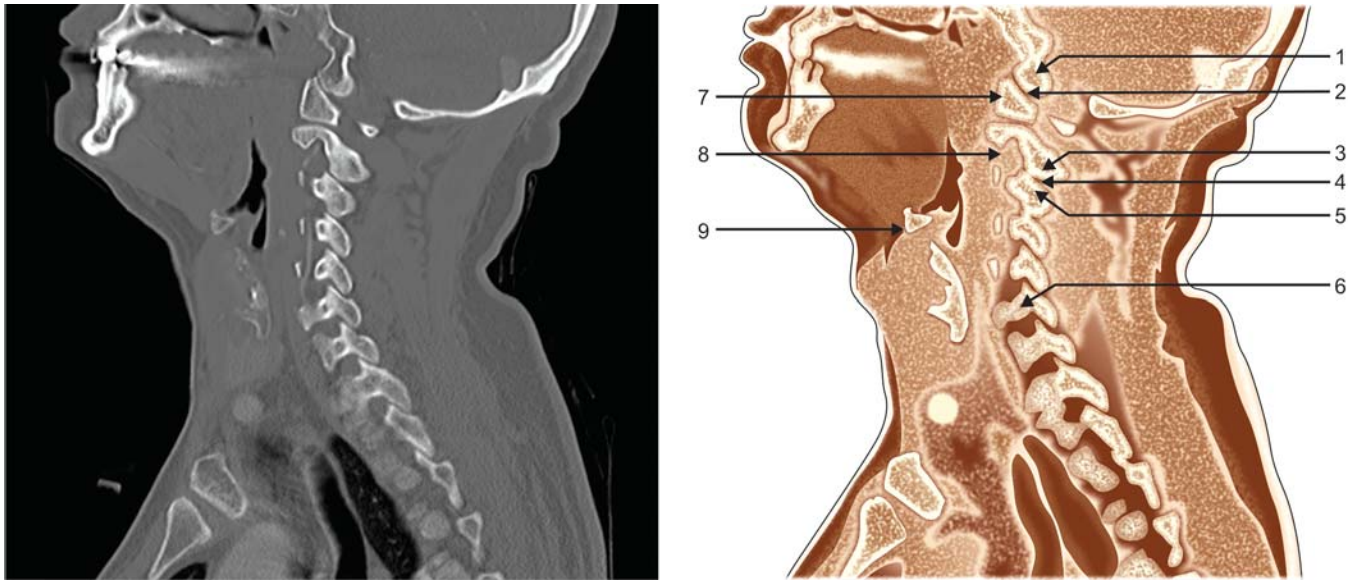

Figure 6.17

1. Occipital condyle
2. Atlanto-occipital joint
3. Inferior facet
4. Facet joint
5. Superior facet
6. Pedicle
7. Lateral mass of atlas
8. Vertebral artery in transverse foramen
9. Hyoid

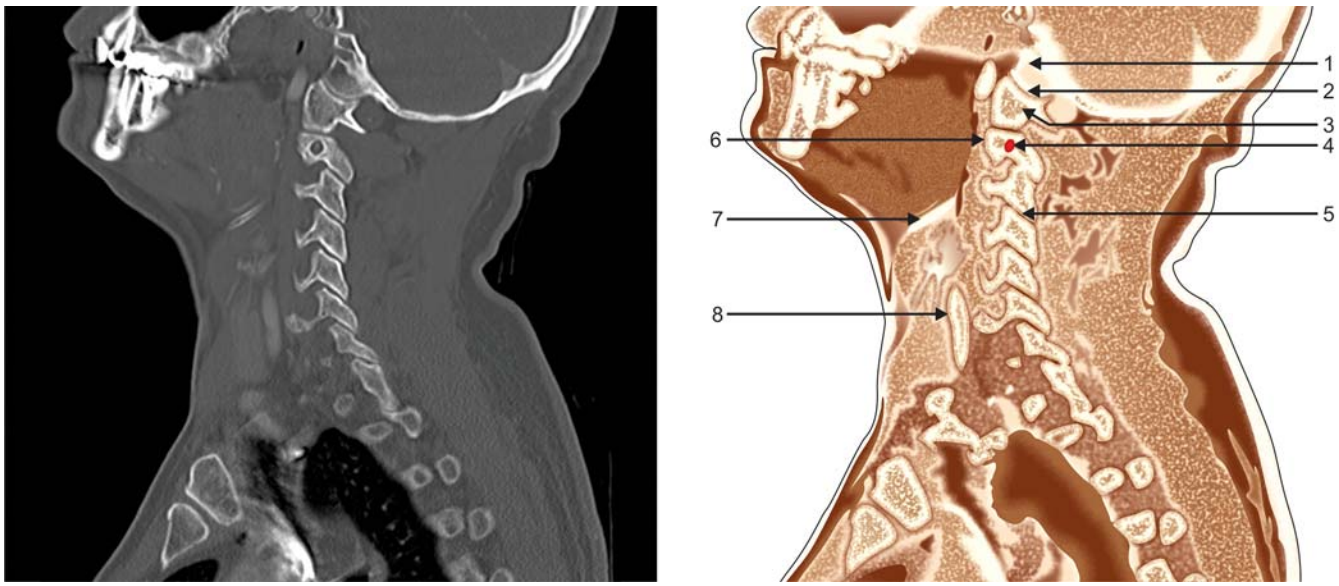

Figure 6.18

1. Occipital condyle
2. Atlanto-occipital joint
3. Lateral mass of atlas
4. Vertebral artery in transverse foramen
5. Facet joint
6. C2 vertebra
7. Hyoid
8. Common carotid artery



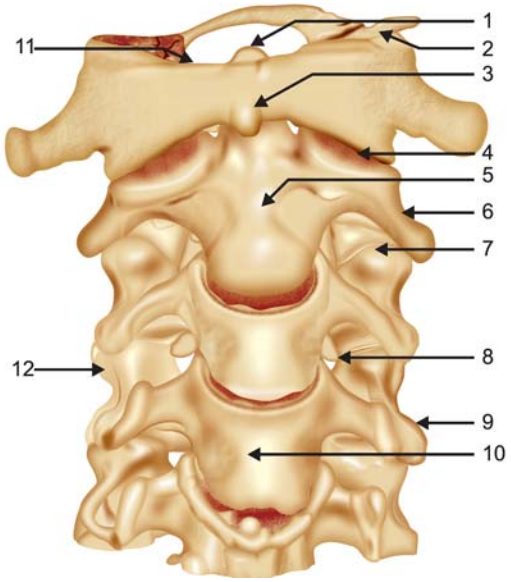

Figure 6.19

Anterior view

1. Dens
2. Atlanto-occipital joint
3. Anterior tubercle of atlas
4. Atlanto-axial joint
5. C2 body
6. Transverse process
7. Facet joint
8. Intervertebral foramen
9. Transverse process C4
10. C4 body
11. Anterior arch of atlas
12. Articular pillar

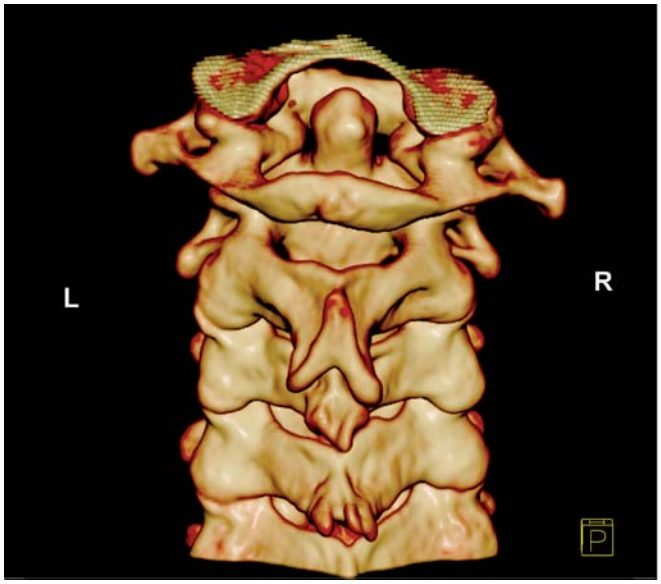

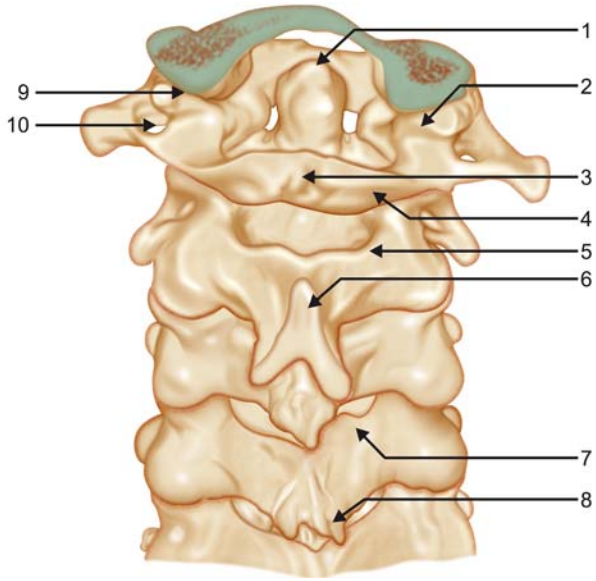

Figure 6.20

Posterior view

1. Dens
2. Lateral mass of atlas
3. Posterior tubercle of atlas
4. Posterior arch of atlas
5. C2 lamina
6. C2 spinous process
7. C4 lamina
8. C4 spinous process
9. Atlanto-occipital joint
10. Transverse foramen

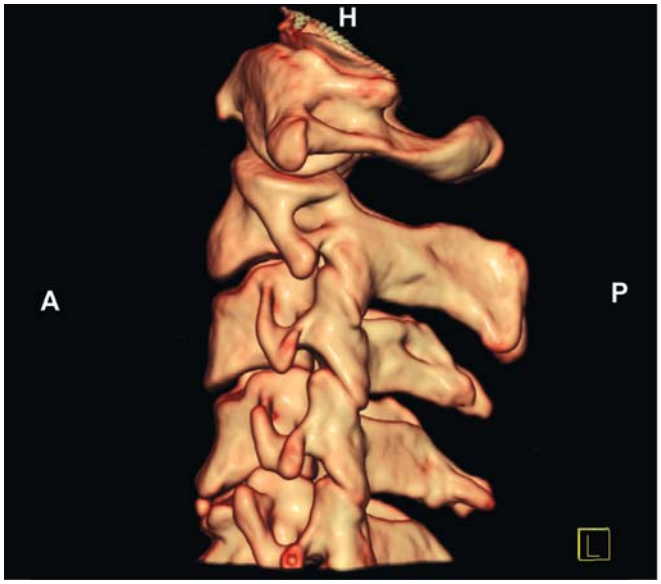

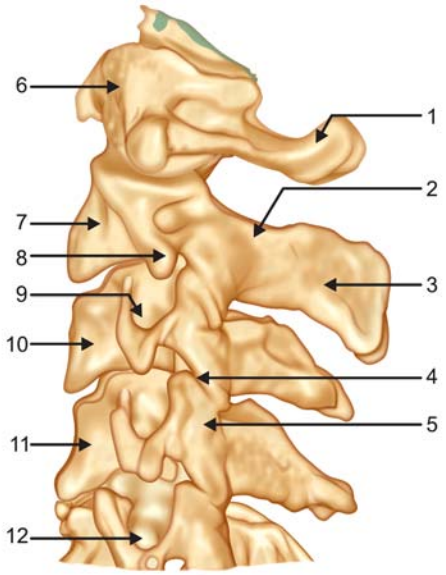

Figure 6.21

Lateral view

1. Posterior arch of atlas
2. Lamina
3. Spinous process C2
4. Facet joint
5. Articular pillar
6. C1 vertebra
7. C2 vertebra
8. Transverse process of C2
9. Foramen transversarium
10. C3 vertebra
11. C4 vertebra
12. Transverse foramen of C5

CERVICAL SPINE MR

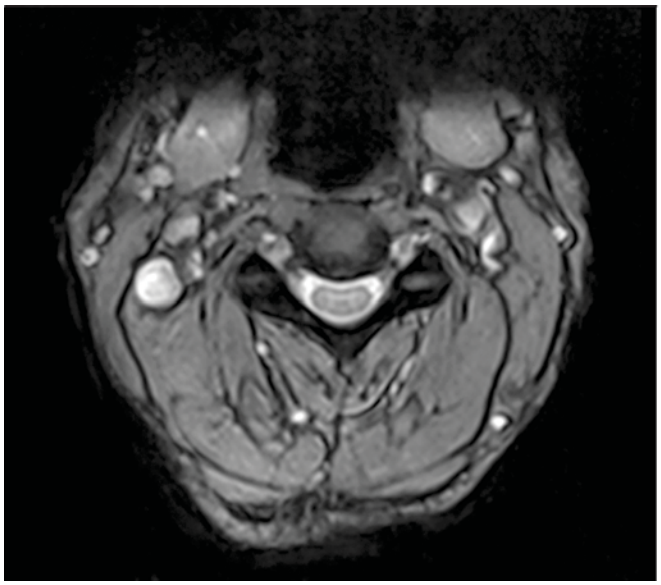

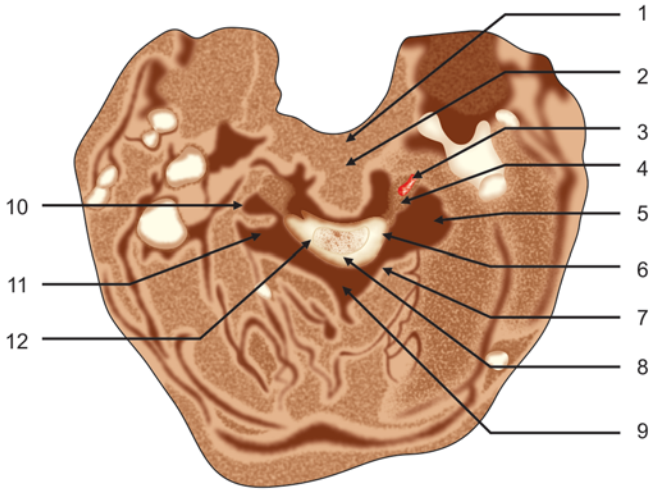

Figure 6.22

1. Anterior longitudinal ligament
2. Intervertebral disk
3. Vertebral artery
4. Dorsal root ganglion
5. Facet joint
6. Posterior root
7. Lamina
8. Spinal cord
9. Spinolaminar junction
10. Superior facet
11. Inferior facet
12. CSF

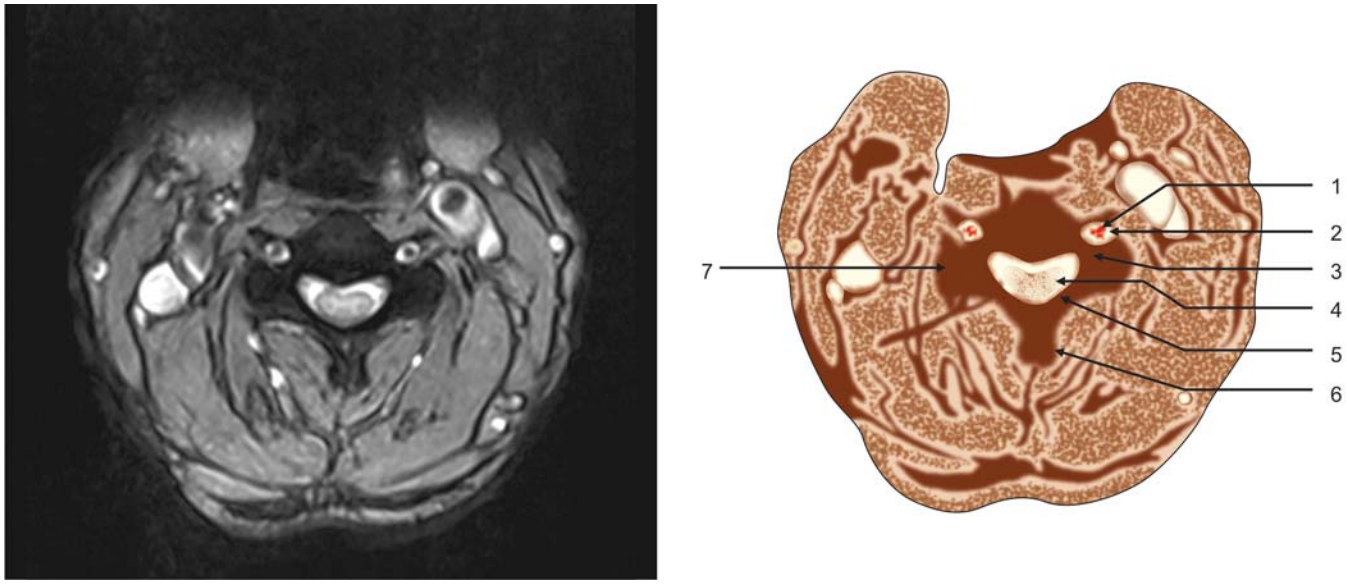

Figure 6.23

1. Vertebral artery
2. Transverse foramen
3. Pedicle
4. Spinal cord
5. Ligamentum flavum
6. Spinous process
7. Articular pillar

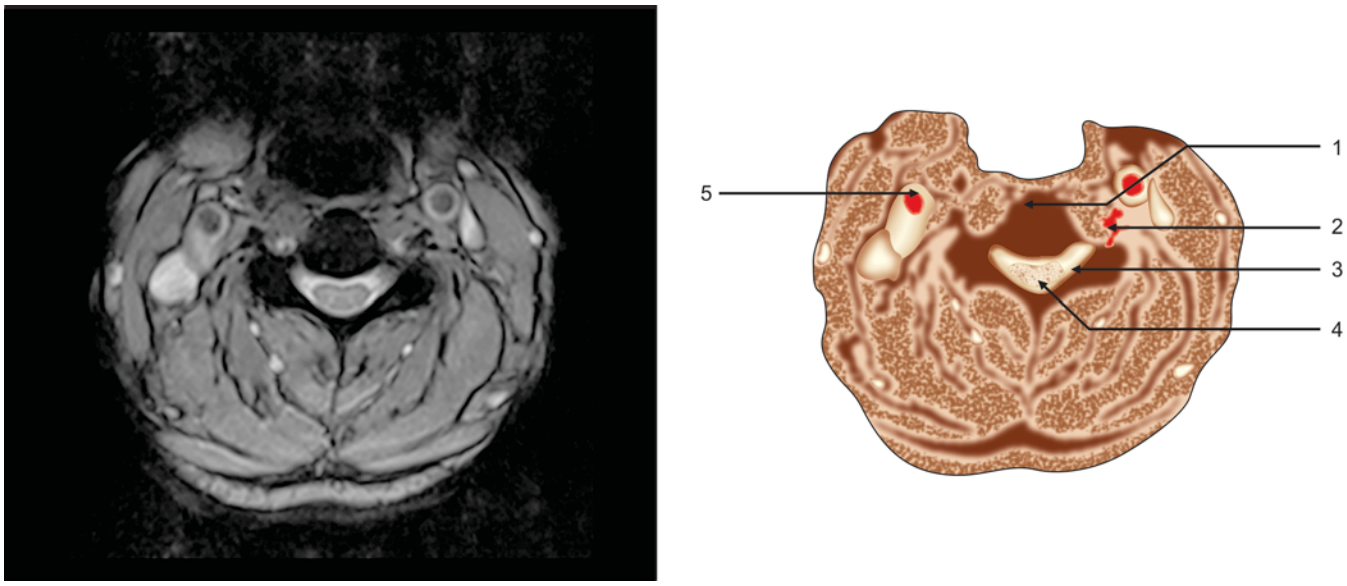

Figure 6.24

1. Cervical vertebral body
2. Vertebral artery
3. Posterior root
4. Spinal gray matter
5. Carotid artery

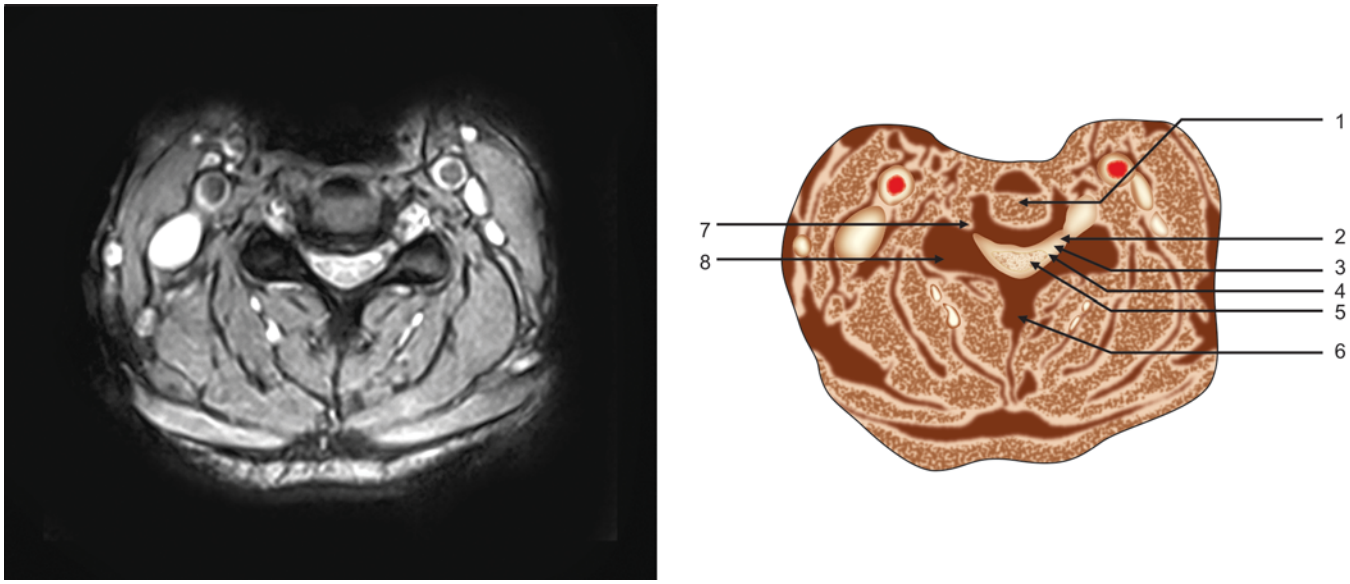

Figure 6.25

1. Intervertebral disk
2. Uncinate process
3. Dorsal root ganglion
4. Posterior root
5. H shaped spinal gray matter
6. Spinous process
7. Intervertebral foramen
8. Facet joint

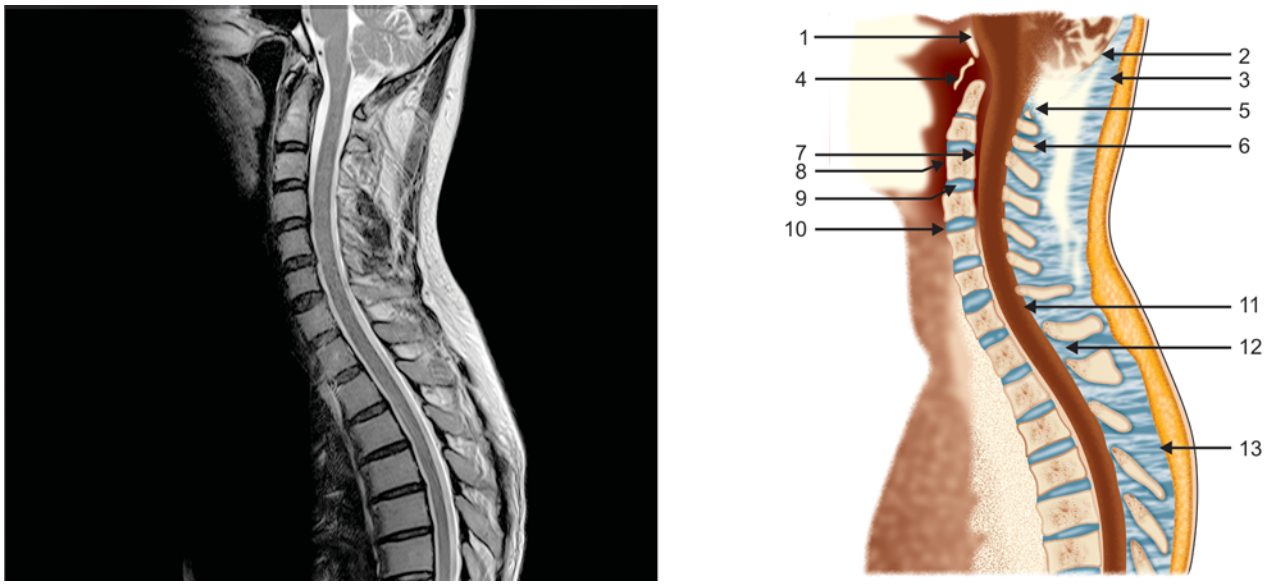

Figure 6.26

1. Clivus
2. Occipital bone
3. Ligamentum nuchae
4. Ant tubercle of atlas dens
5. Posterior tubercle of C1
6. Spinous process of C2
7. Posterior longitudinal ligament
8. Anterior longitudinal ligament
9. Nucleus pulposis
10. Annulus fibrosis
11. Spinal cord
12. Ligamentum flavum
13. Supraspinatous ligament

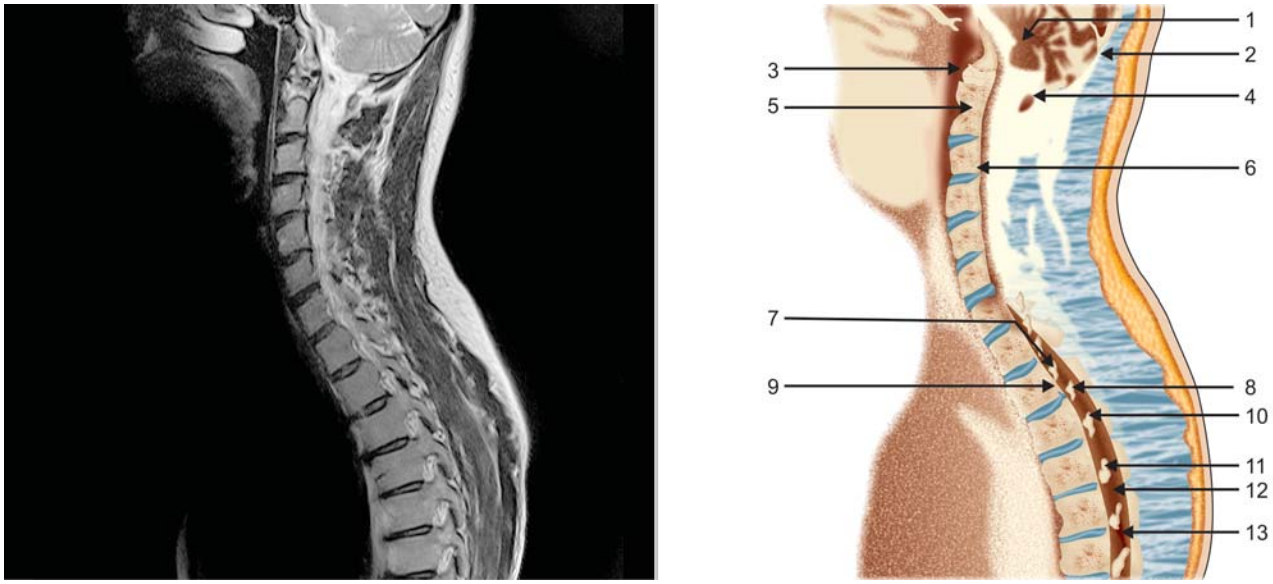

Figure 6.27

1. Cerebellum
2. Occipital bone
3. Anterior arch of C1
4. Posterior arch of C1
5. Dens
6. Intervertebral disk
7. Dorsal nerve root
8. Ligamentum flavum
9. Ventral nerve root
10. Intervertebral foramen
11. Nerve root
12. Pedicle
13. Facet joint

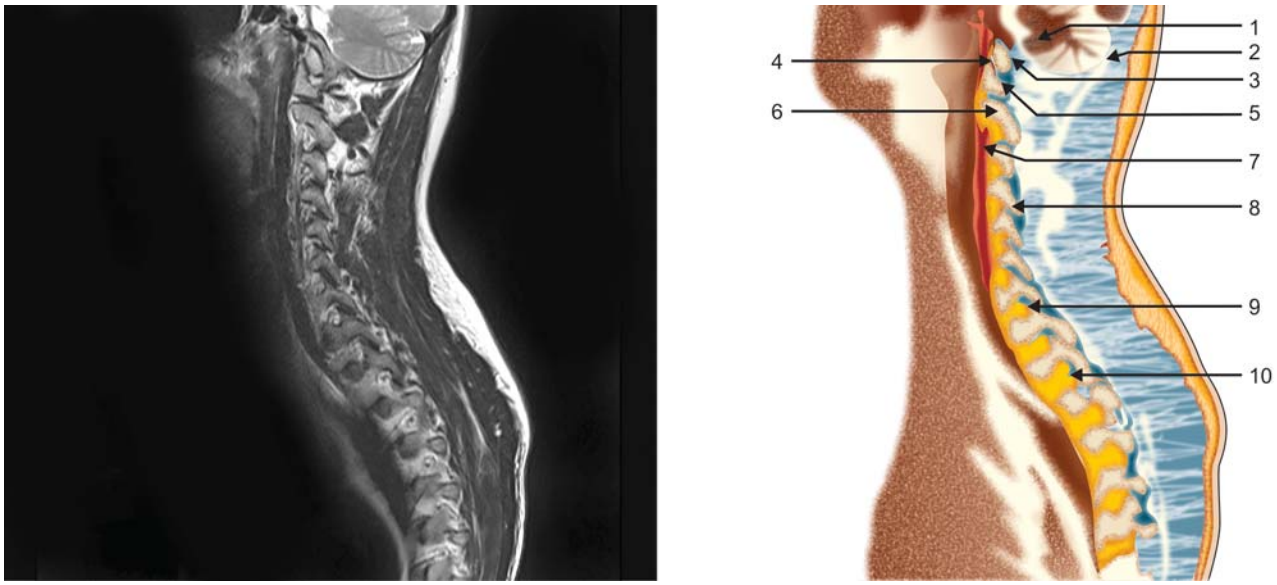

Figure 6.28

1. Cerebellum
2. Occipital bone
3. Occipital condyle
4. Atlanto-occipital joint
5. Lateral mass of atlas
6. C2 vertebra
7. Vertebral artery
8. Facet joint
9. Intervertebral foramen
10. Dorsal root ganglion

LUMBAR SPINE CT

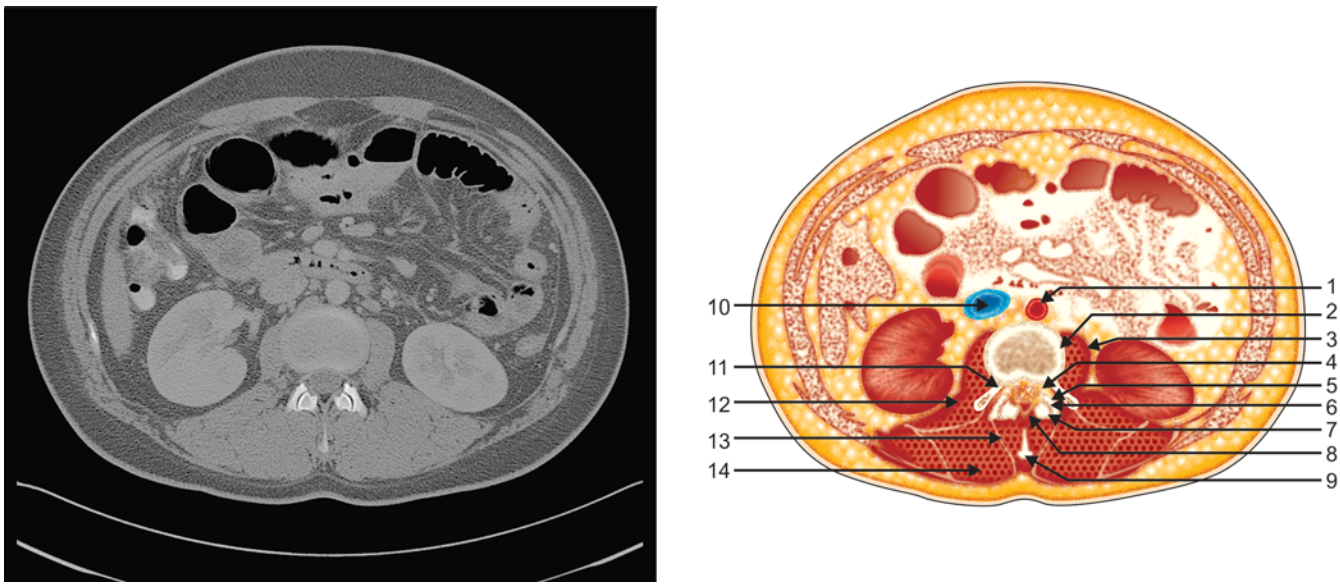

Figure 6.29

1. Aorta
2. Intervertebral disk
3. Psoas muscle
4. Thecal sac
5. Superior facet
6. Facet joint
7. Inferior facet
8. Ligamentum flavum
9. Spinous process
10. IVC
11. Intervertebral foramen
12. Quadratus lumborum
13. Multifidus
14. Erector spinae

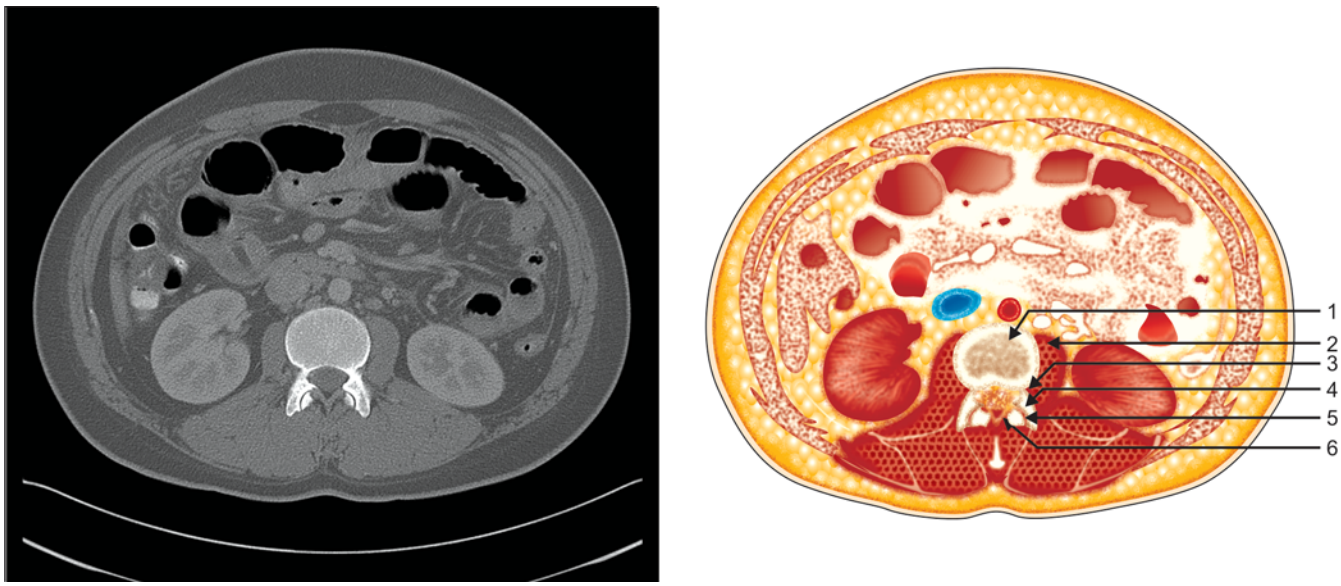

Figure 6.30

1. Vertebral body
2. Psoas muscle
3. Pedicle
4. Superior facet
5. Facet joint
6. Ligamentum flavum

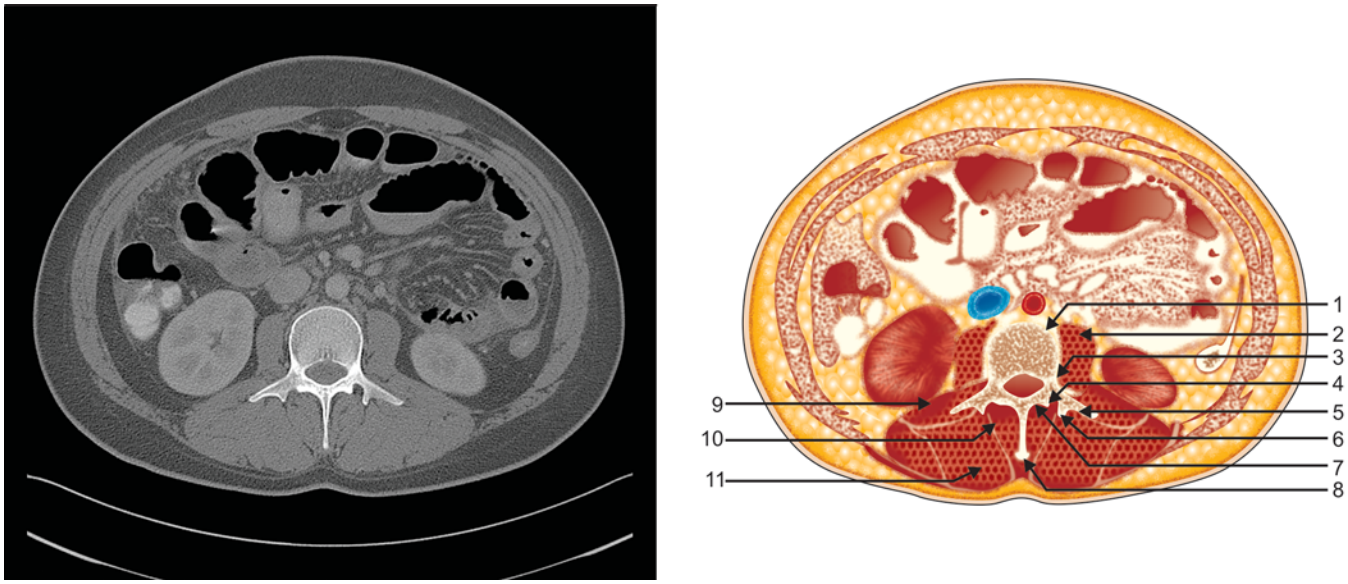

Figure 6.31

1. Vertebral body
2. Psoas muscle
3. Pedicle
4. Accessory tubercle
5. Transverse process
6. Mammillary process
7. Lamina
8. Spinous process
9. Quadratus lumborum
10. Multifidus muscle
11. Erector spinae

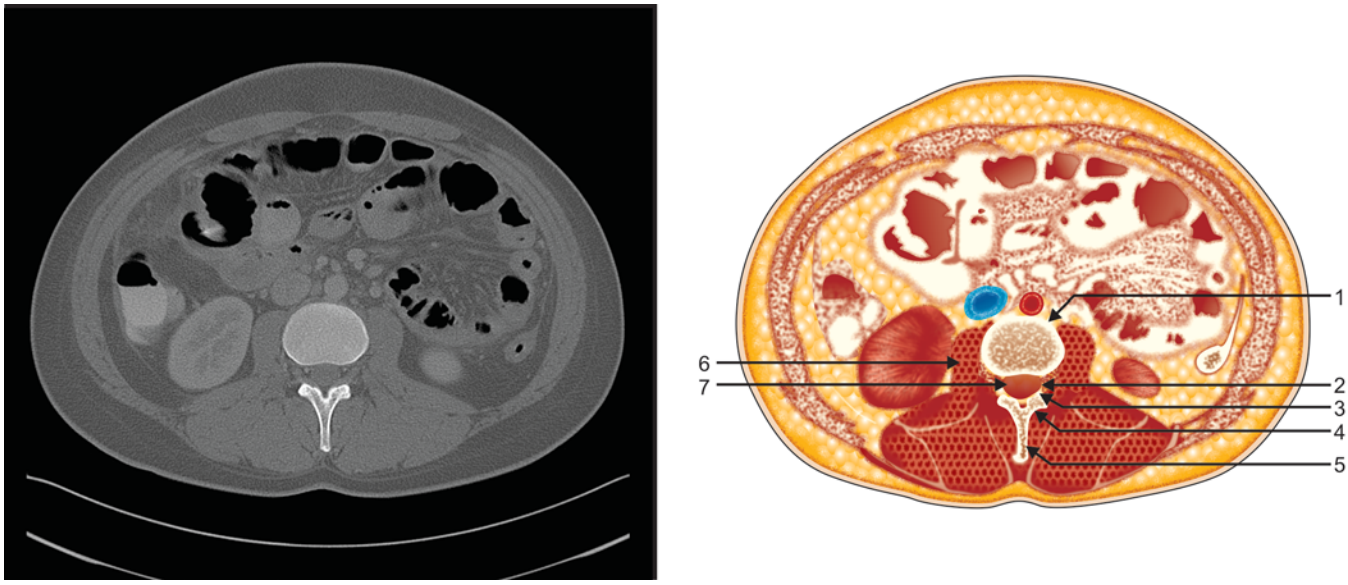

Figure 6.32

1. Vertebral body
2. Intervertebral foramen
3. Ligamentum flavum
4. Lamina
5. Spinous process
6. Psoas muscle
7. Thecal sac



Figure 6.33

1. Crus of diaphragm
2. L1
3. Left Kidney
4. Psoas muscle
5. Intervertebral disk
6. L5 body
7. Sacroiliac joint
8. Sacral promontory

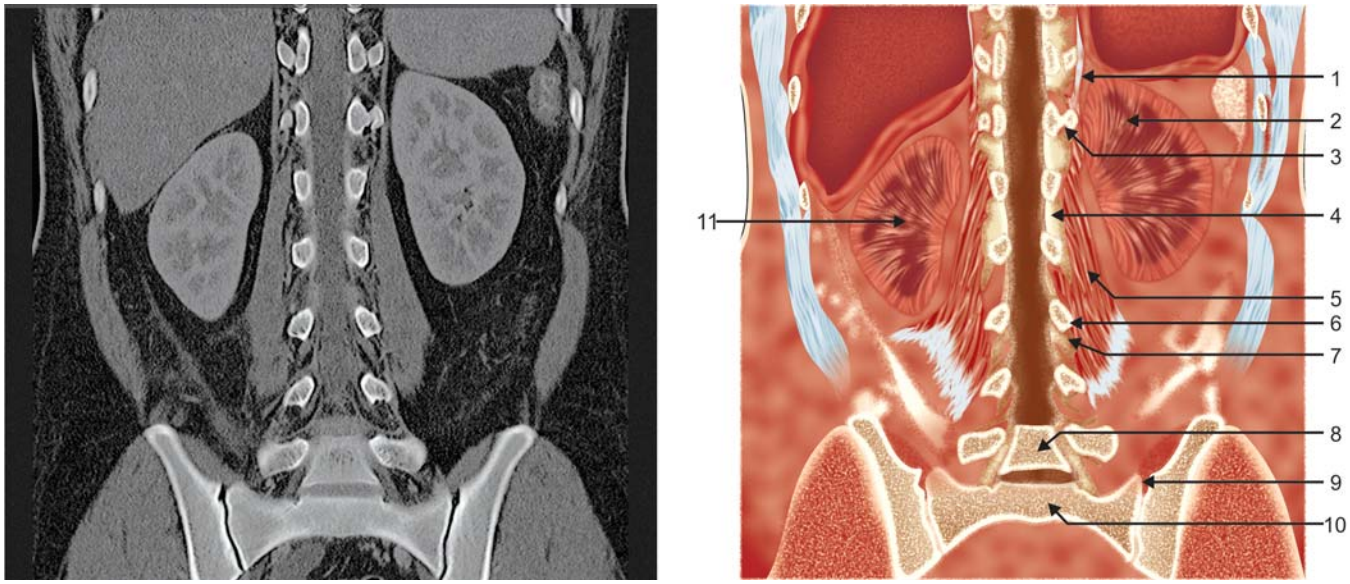

Figure 6.34

1. Left crus of diaphragm
2. Left kidney
3. Costovertebral joint
4. Intervertebral foramen
5. Psoas muscle
6. Pedicle
7. Nerve root
8. L5
9. Sarcoiliac joint
10. Sacrum
11. Right kidney

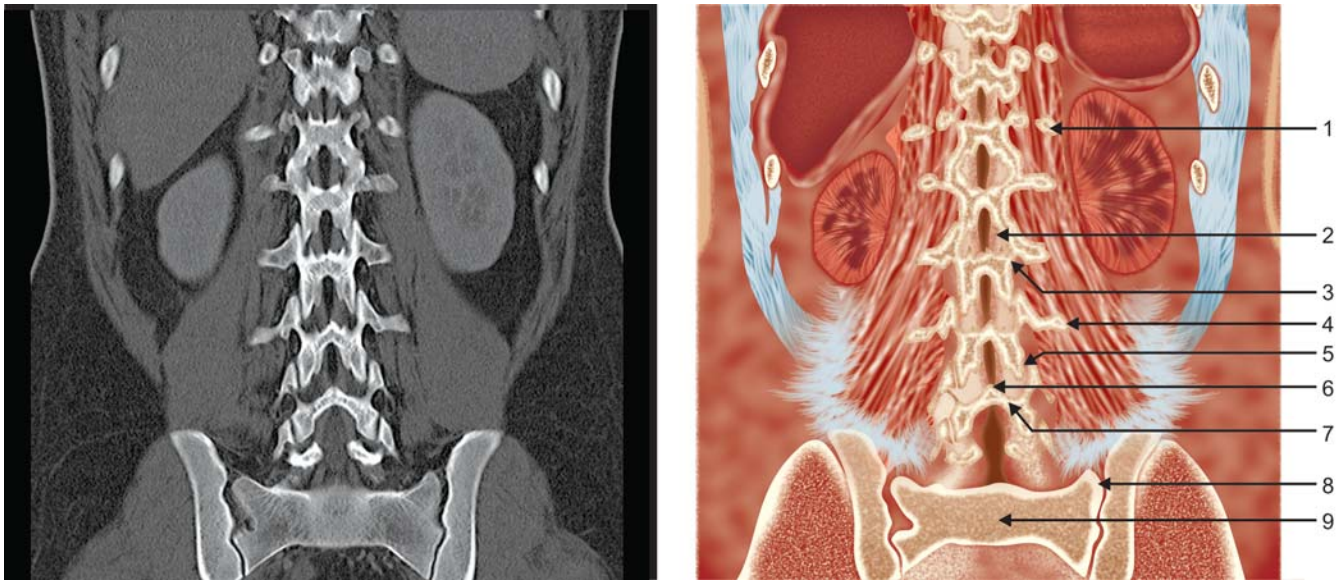

Figure 6.35

1. Twelfth rib
2. Ligamentum flavum
3. Pars interarticularis
4. Transverse process
5. Facet joint
6. Spinolaminar junction
7. Lamina
8. Sacroiliac joint
9. Sacrum

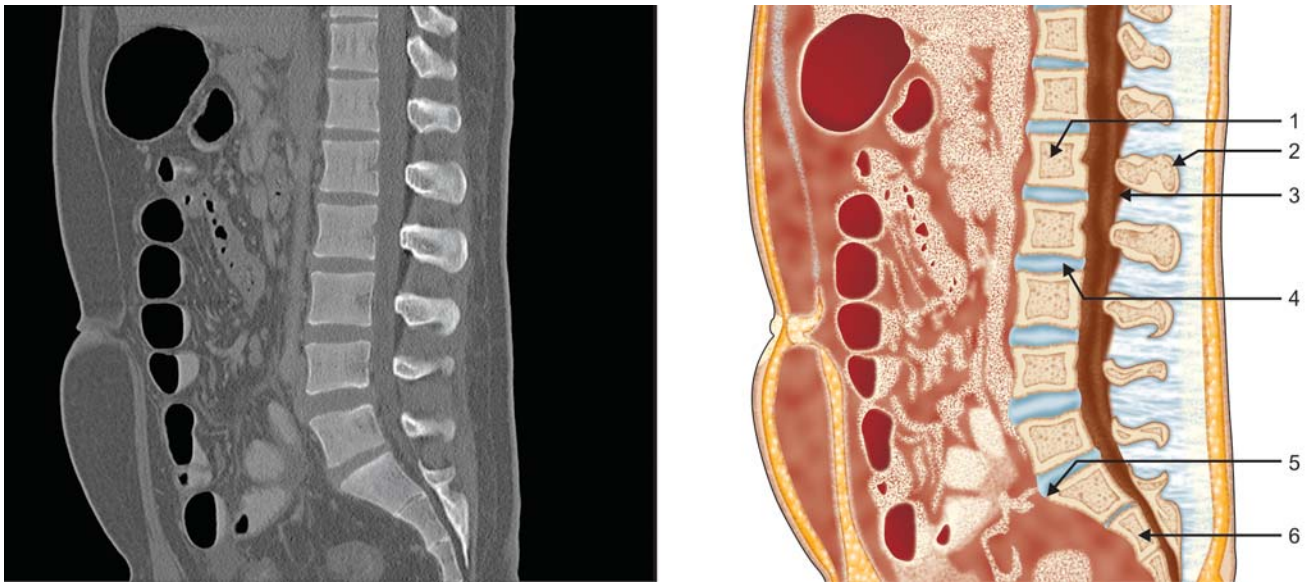

Figure 6.36

1. L1
2. Spinous process
3. Thecal sac
4. Intervertebral disk
5. Sacral promontory
6. S2

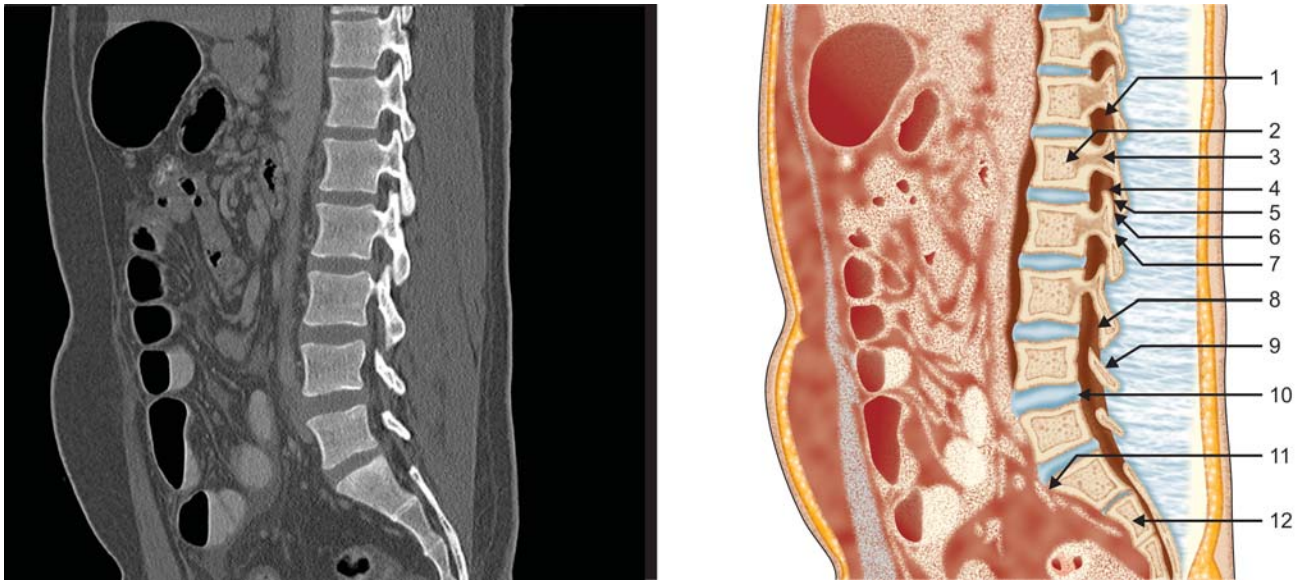

Figure 6.37

1. Intervertebral foramen
2. L1 body
3. Pedicle
4. Superior facet
5. Facet joint
6. Inferior facet
7. Pars interarticularis
8. Ligamentum flavum
9. Lamina
10. Intervertebral disk
11. Sacral promontory
12. S2

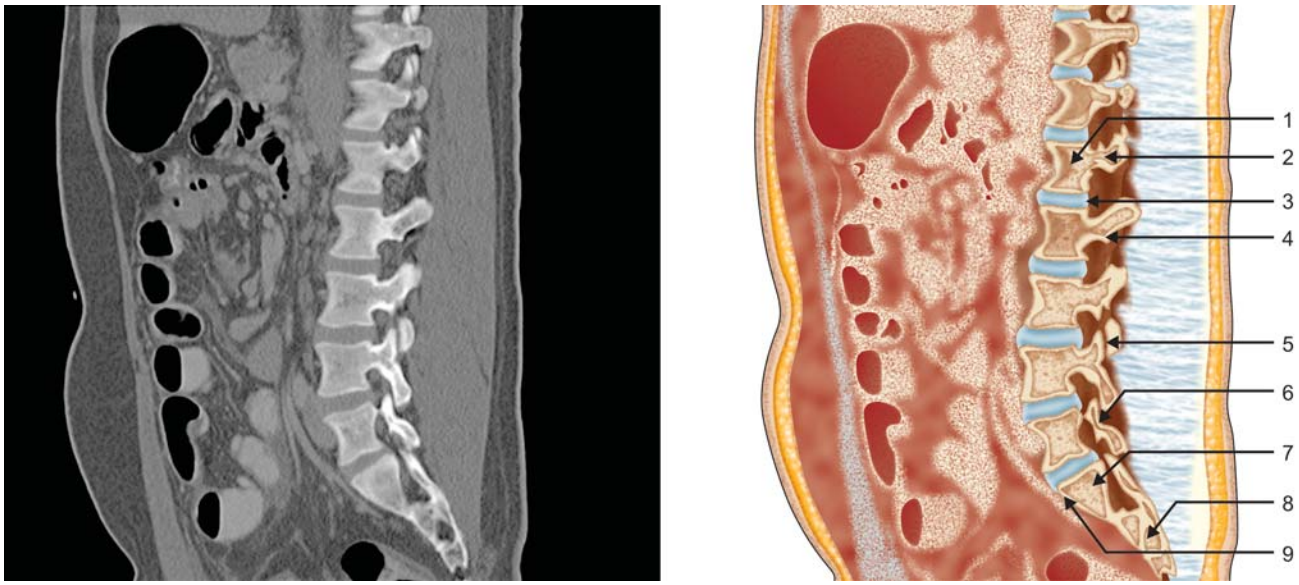

Figure 6.38

1. L1
2. Pedicle
3. Intervertebral disk
4. Accessory tubercle
5. Facet joint
6. Pars interarticularis
7. S1
8. Sacral foramen
9. Sacral promontory

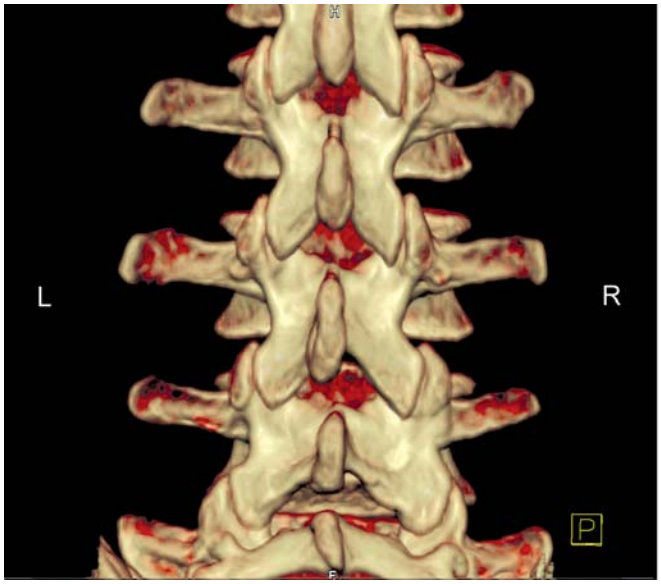

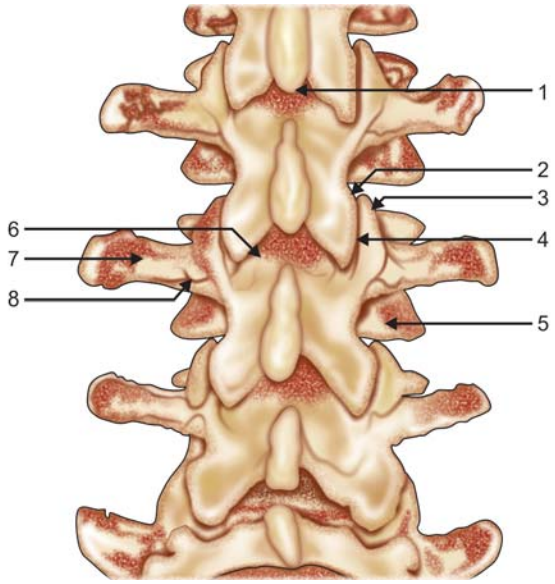

Figure 6.39

Posterior view

1. Spinous process
2. Inferior facet
3. Superior facet
4. Facet joint
5. Inferior margin of vertebra
6. Lamina
7. Transverse process
8. Accessory tubercle

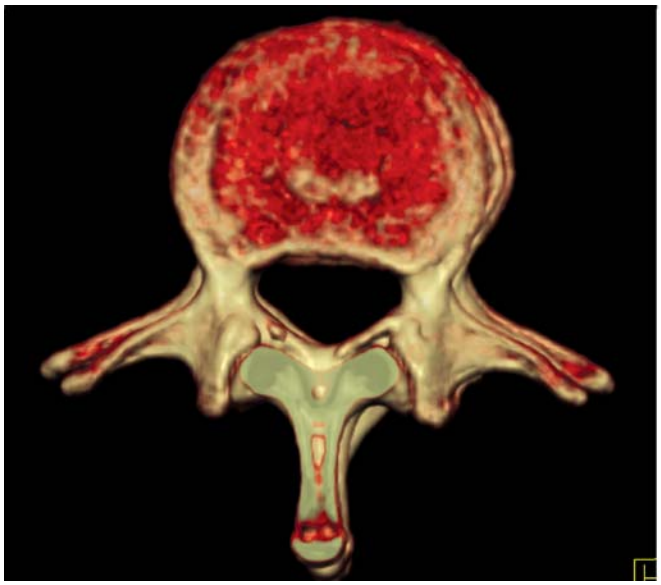

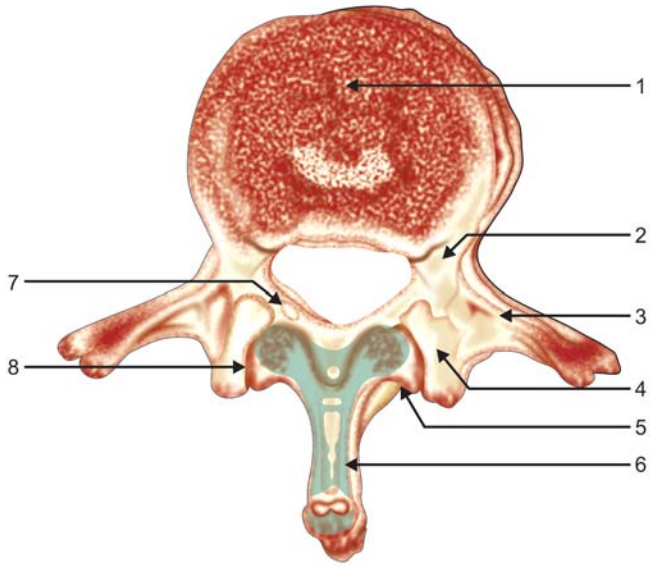

Figure 6.40

Superior view

1. Vertebral body
2. Pedicle
3. Transverse process
4. Superior facet
5. Inferior facet
6. Spinous process
7. Lamina
8. Facet joint

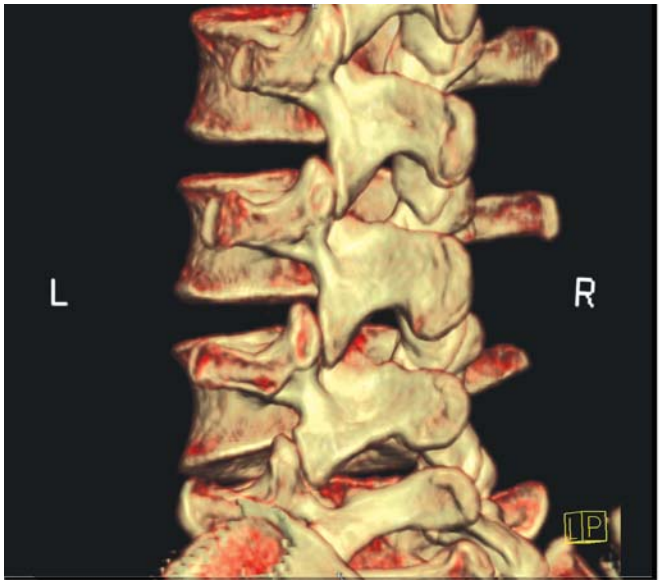

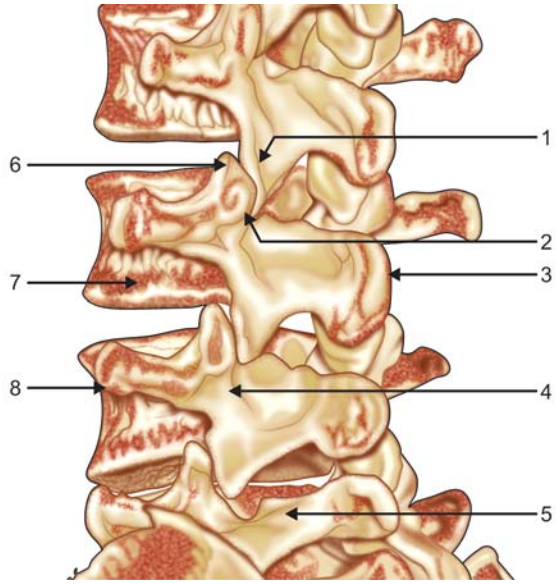

Figure 6.41

Lateral view

1. Inferior facet
2. Facet joint
3. Spinous process
4. Pars interarticularis
5. Lamina
6. Superior facet
7. Vertebral body
8. Transverse process

LUMBAR SPINE MR



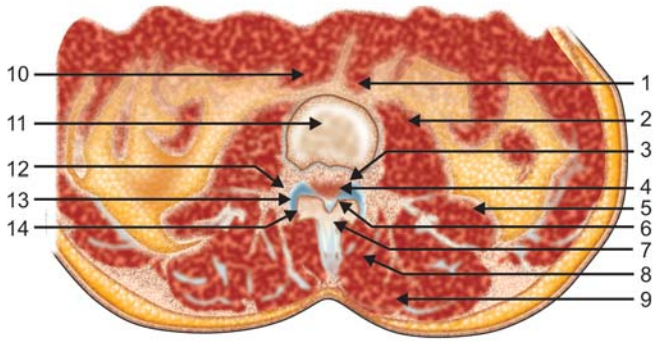

Figure 6.42

1. Aorta
2. Psoas muscle
3. Dura
4. Nerve roots
5. Quadratus lumborum
6. Ligamentum flavum
7. Interspinous ligament
8. Multifidus muscle
9. Erector spinae
10. IVC
11. Vertebral body
12. Superior facet
13. Facet joint
14. Inferior facet

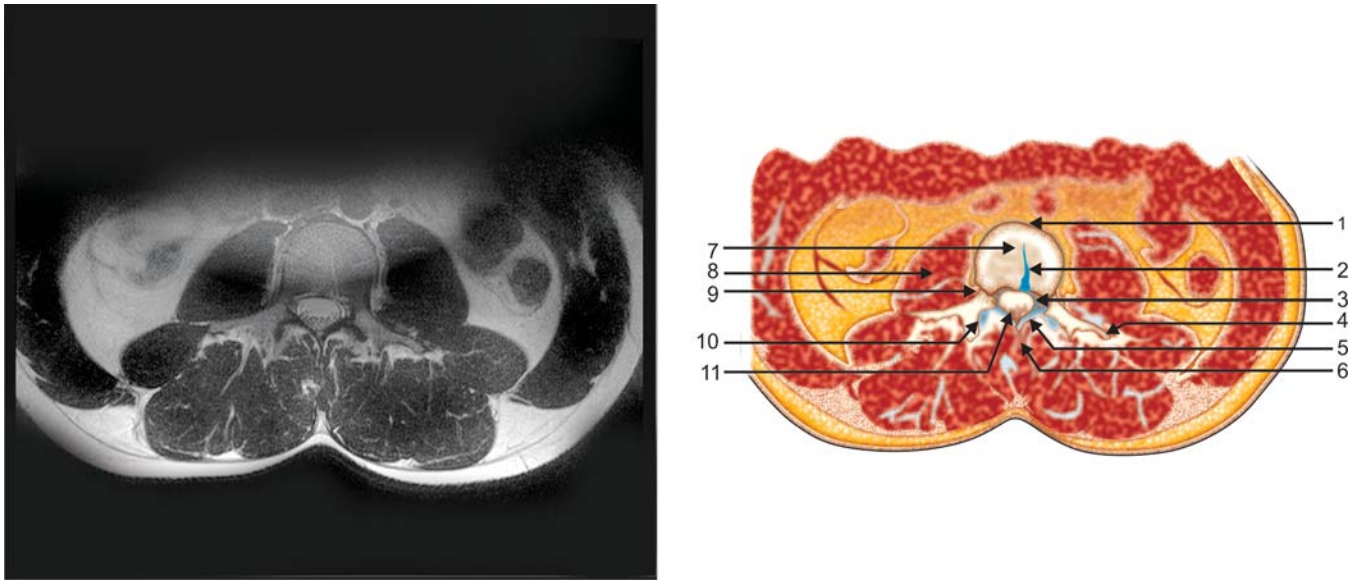

Figure 6.43

1. Anterior longitudinal ligament
2. Basivertebral vein
3. Dural sac
4. Transverse process
5. Ligamentum flavum
6. Interspinous ligament
7. Vertebral body
8. Psoas
9. Pedicle
10. Facet joint
11. Nerve roots

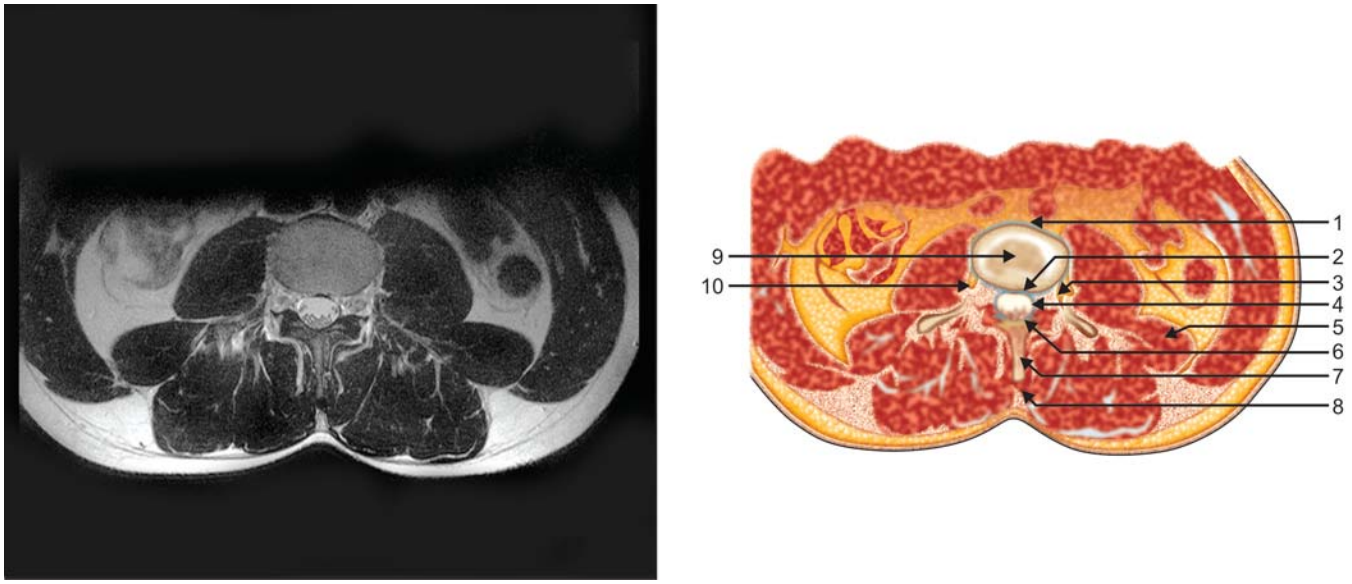

Figure 6.44

1. Anterior longitudinal ligament
2. Posterior longitudinal ligament
3. Dorsal root ganglion
4. Dura
5. Quadratus lumborum
6. Lamina
7. Spinous process
8. Supraspinatous ligament
9. Vertebral body
10. Intervertebral foramen

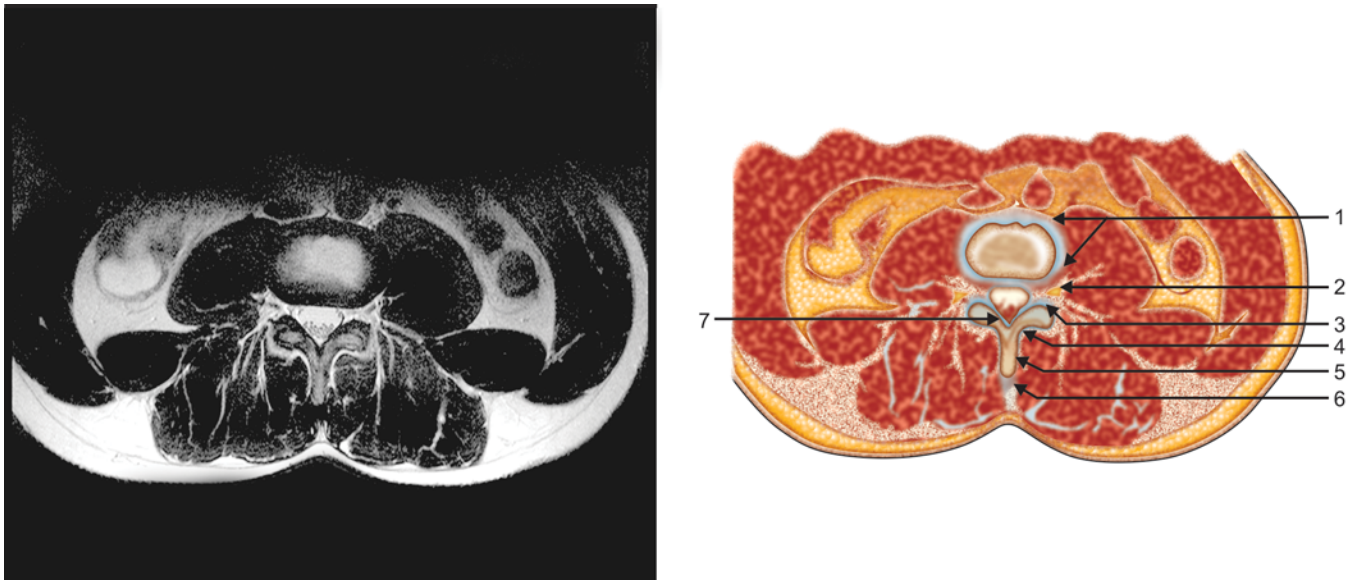

Figure 6.45

1. Intervertebral disk
2. Nerve roots
3. Facet joint
4. Lamina
5. Spinous process
6. Supraspinatous ligament
7. Ligamentum flavum

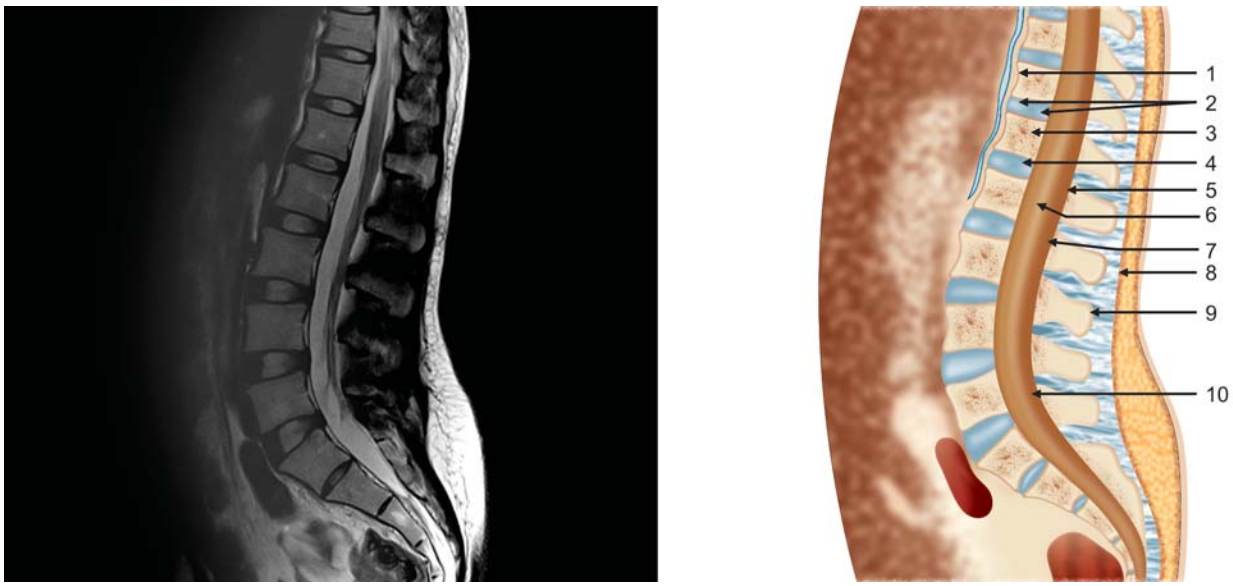

Figure 6.46

1. Anterior longitudinal ligament
2. Annular fibrosis
3. Vertebral body
4. Nucleus pulposis
5. Dura
6. Conus medullaris
7. Cauda equina
8. Supraspinatous ligament
9. Spinous process
10. Nerve roots

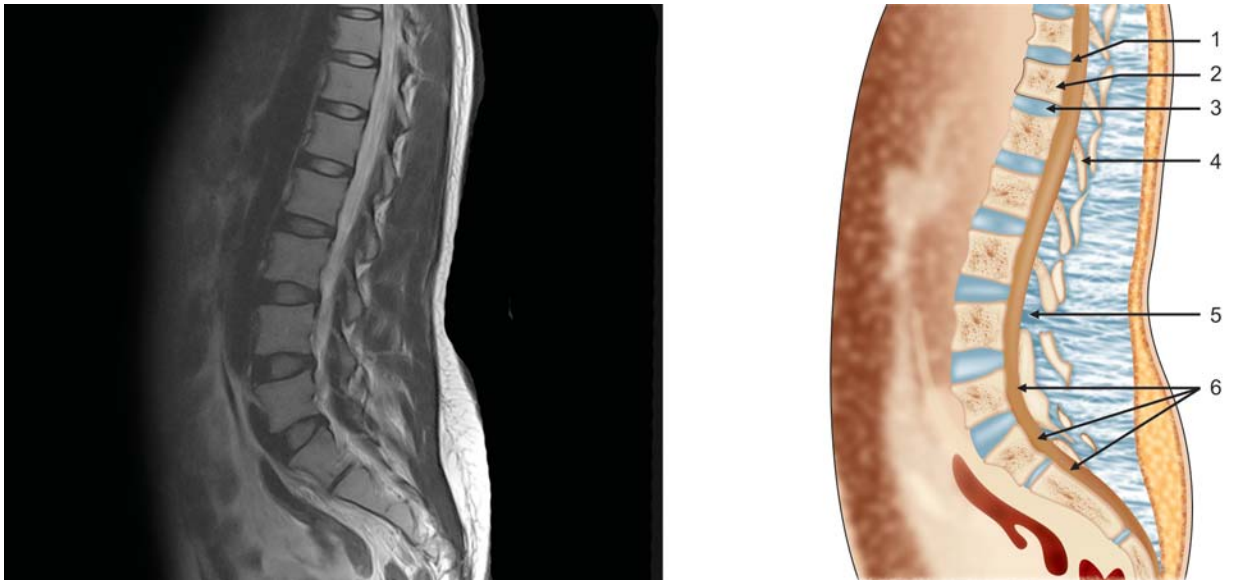

Figure 6.47

1. Annulus fibrosus
2. Vertebral body
3. Nucleus pulposus
4. Lamina
5. Ligamentum flavum
6. Nerve roots



Figure 6.48

1. Pedicle
2. Intervertebral disk
3. Intervertebral foramen
4. Superior facet
5. Pars interarticularis
6. Inferior facet
7. Nerve roots



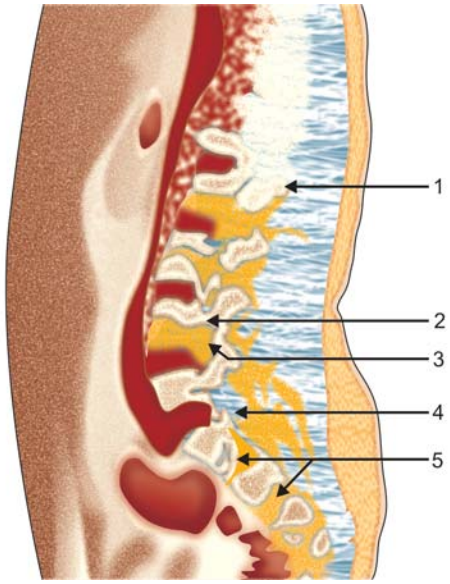

Figure 6.49

1. Transverse process
2. Pedicle
3. Intervertebral foramen
4. Facet joint
5. Sacral nerve roots

Section 3

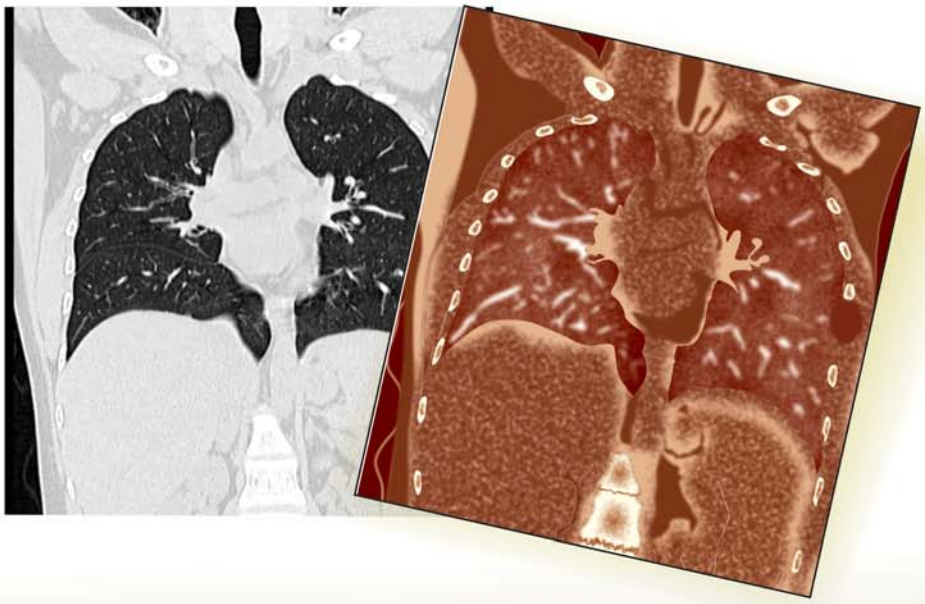

Trunk

- **Chest**
- **Abdomen**
- **Pelvis**

CHAPTER 7

Chest

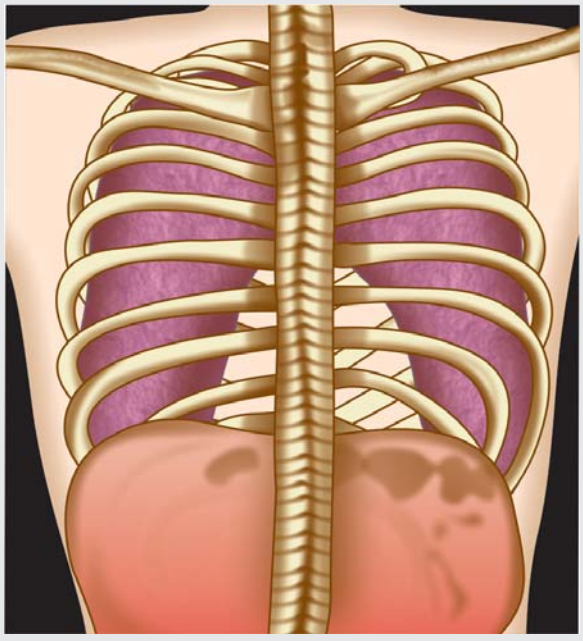

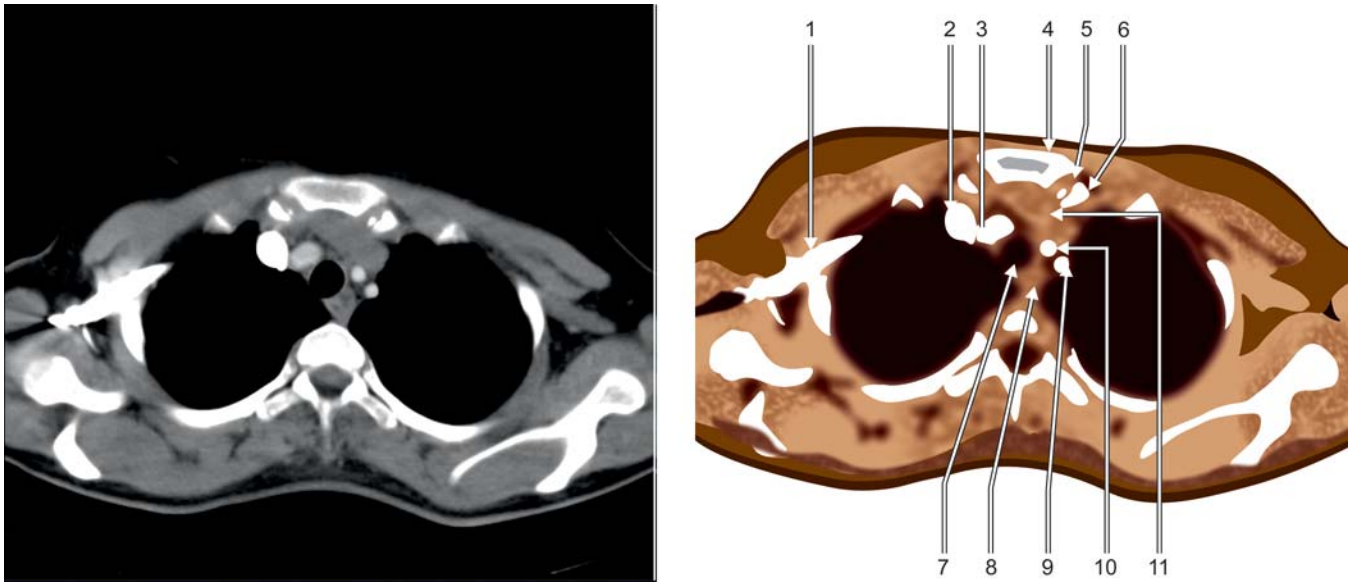

Figure 7.1

1. Right subclavian vein
2. Right brachiocephalic vein
3. Right brachiocephalic artery
4. Sternum
5. Sternoclavicular joint
6. Clavicle
7. Trachea
8. Esophagus
9. Left subclavian artery
10. Left carotid artery
11. Left brachiocephalic vein

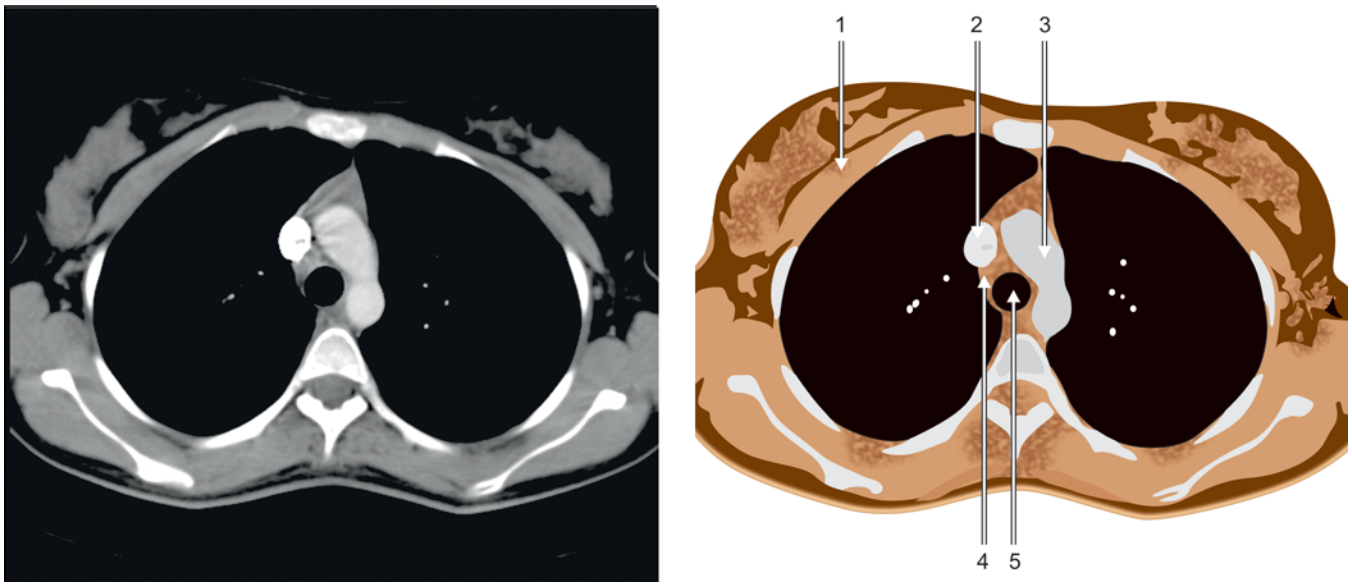

Figure 7.2

1. Pectoral muscles
2. SVC
3. Arch of aorta
4. Azygos vein
5. Trachea

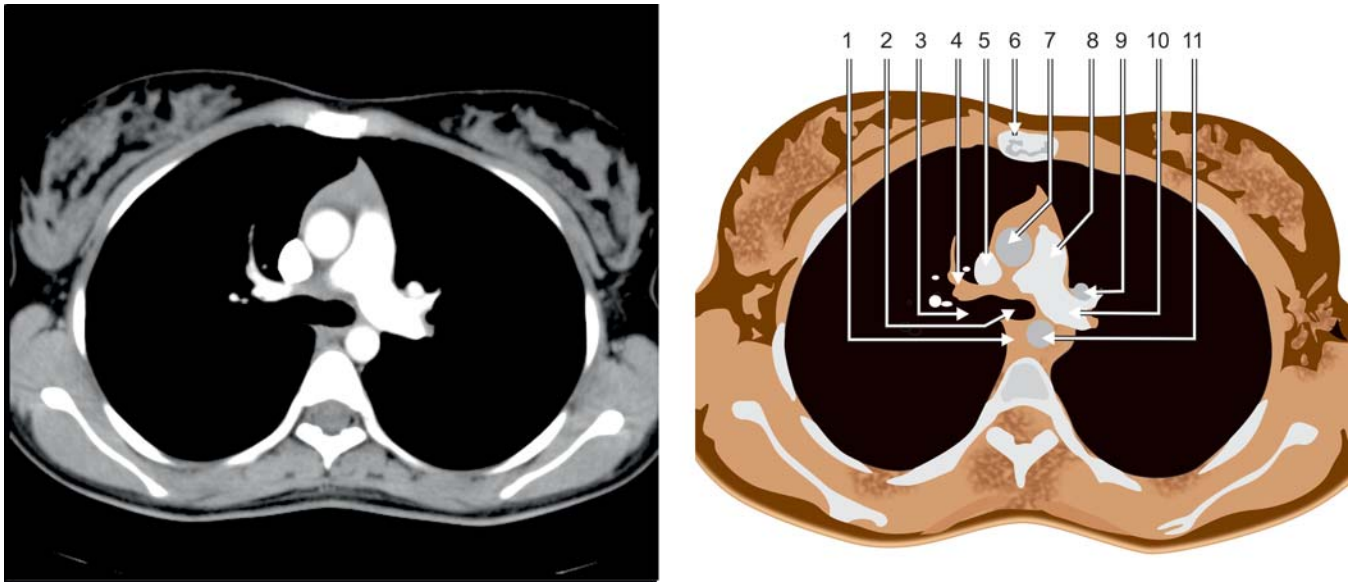

Figure 7.3

1. Esophagus
2. Left main bronchus
3. Right main bronchus
4. Right superior pulmonary artery
5. SVC
6. Sternum
7. Ascending aorta
8. Main pulmonary artery
9. Left superior pulmonary vein
10. Left pulmonary artery
11. Descending aorta

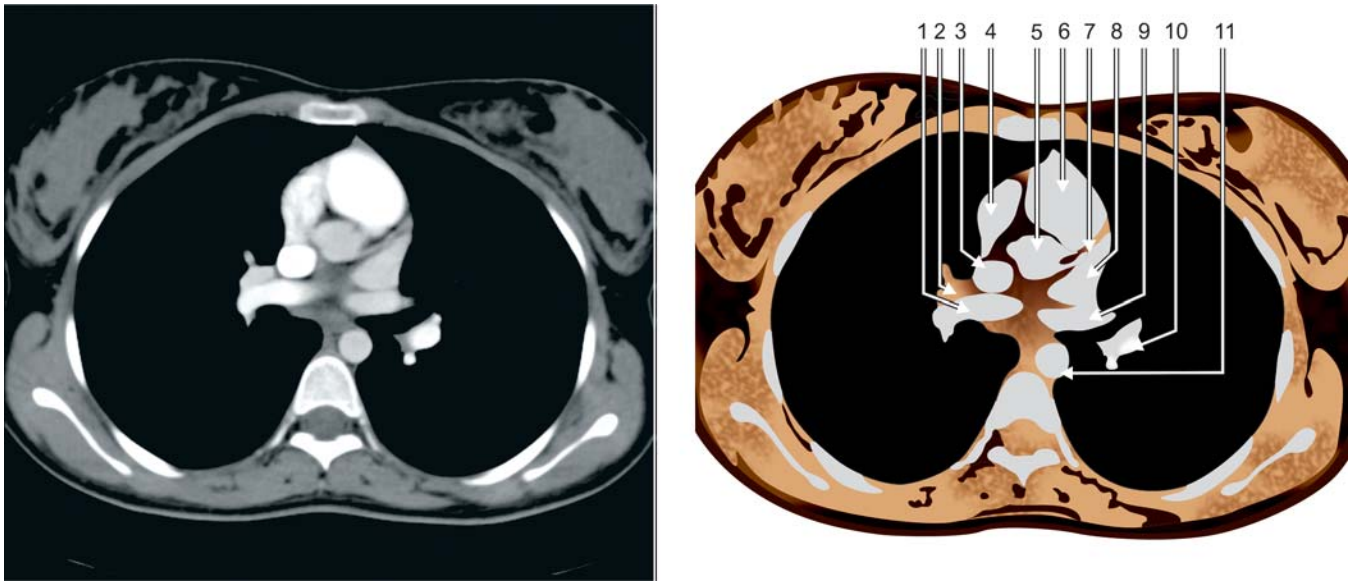

Figure 7.4

1. Right pulmonary artery
2. Rt Superior pulmonary vein
3. SVC
4. Right atrial appendage
5. Aortic root
6. Right ventricular outflow tract
7. Left coronary artery
8. Left atrial appendage
9. Left superior pulmonary vein
10. Left inferior pulmonary artery
11. Descending aorta

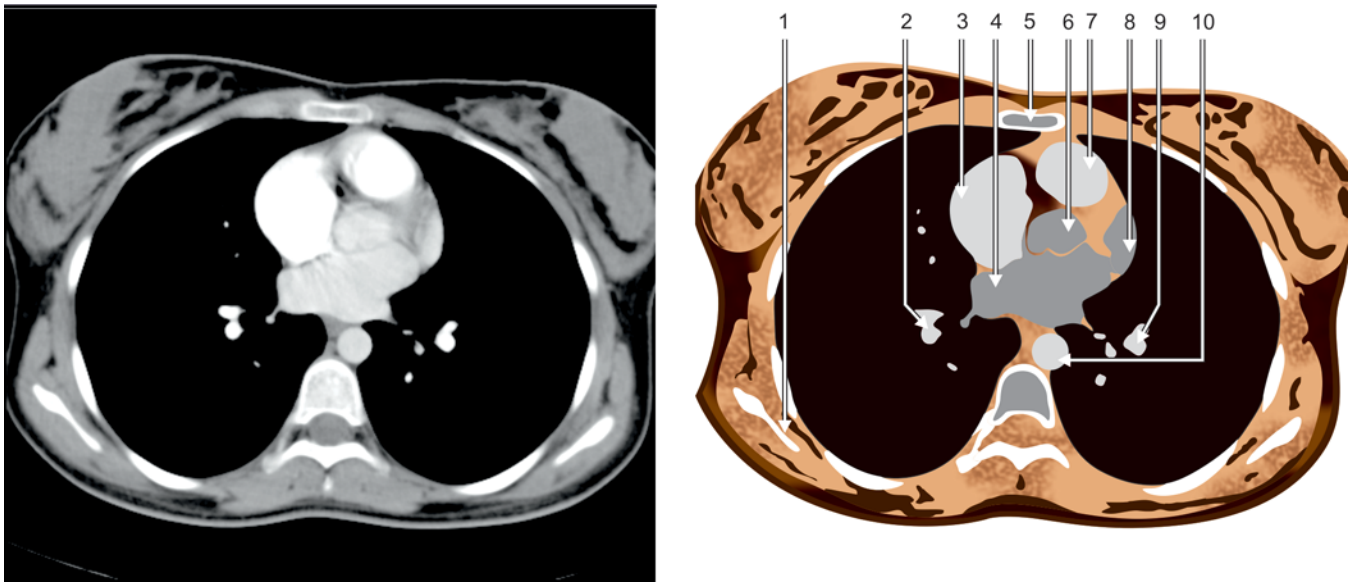

Figure 7.5

1. Scapula
2. Right inferior pulmonary artery
3. Right atrium
4. Left atrium
5. Sternum
6. Aortic root
7. Infundibulum of right ventricle
8. Left atrial appendage
9. Left inferior pulmonary artery
10. Descending aorta

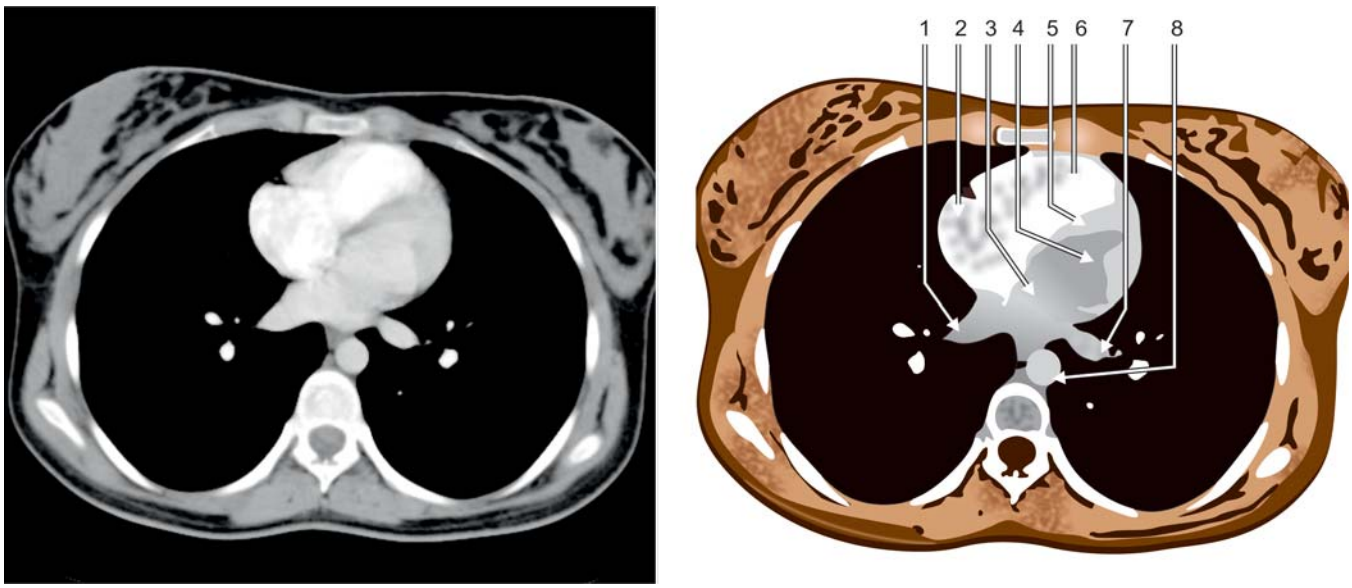

Figure 7.6

1. RT inferior pulmonary vein
2. Right atrium
3. Left atrium
4. Left ventricle
5. Interventricular septum
6. Right ventricle
7. Left inferior pulmonary vein
8. Descending aorta

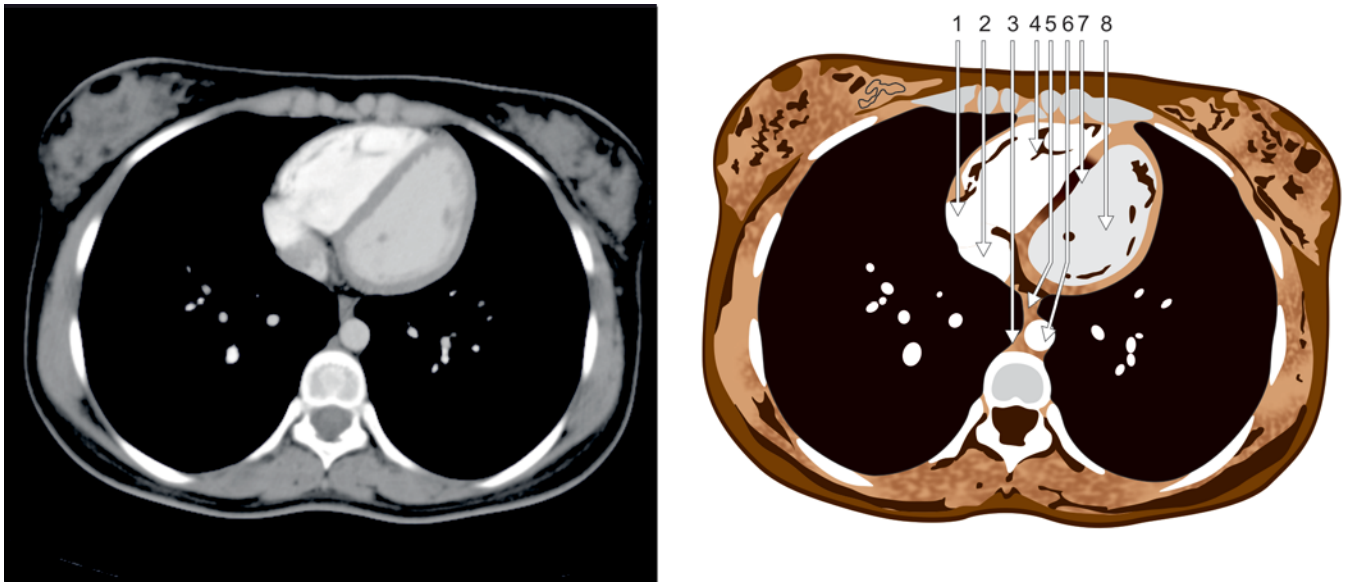

Figure 7.7

1. Right atrium
2. IVC opening into RA
3. Azygos vein
4. Right ventricle
5. Esophagus
6. Descending aorta
7. Interventricular septum
8. Left ventricle

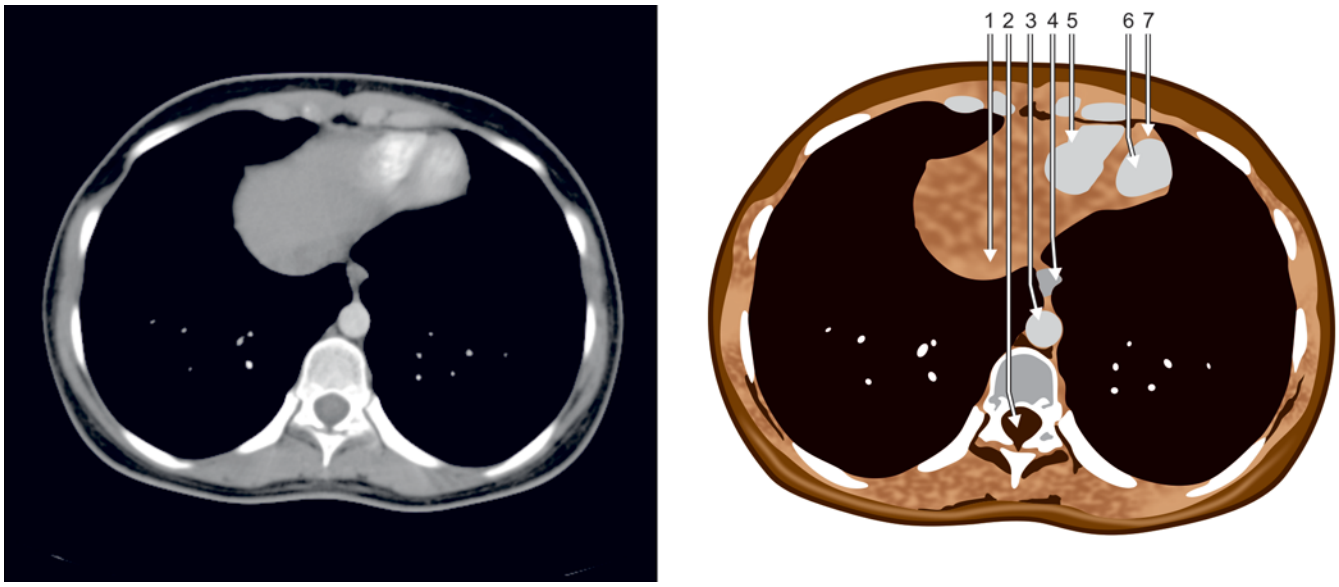

Figure 7.8

1. IVC
2. Spinal cord
3. Aorta
4. Esophagus
5. Right ventricle
6. Left ventricle
7. Cardiac apex

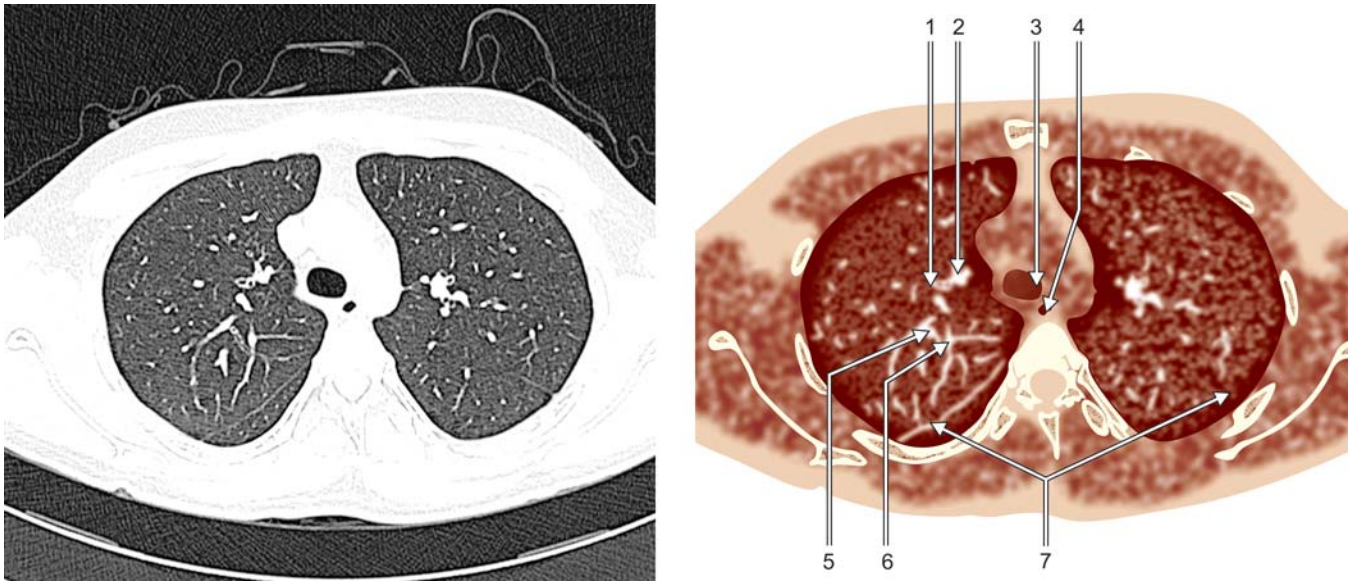

Figure 7.9

1. Bronchus
2. Apical segment vessels
3. Trachea
4. Esophagus
5. Bronchovascular structures
6. Posterior segment
7. Major fissure

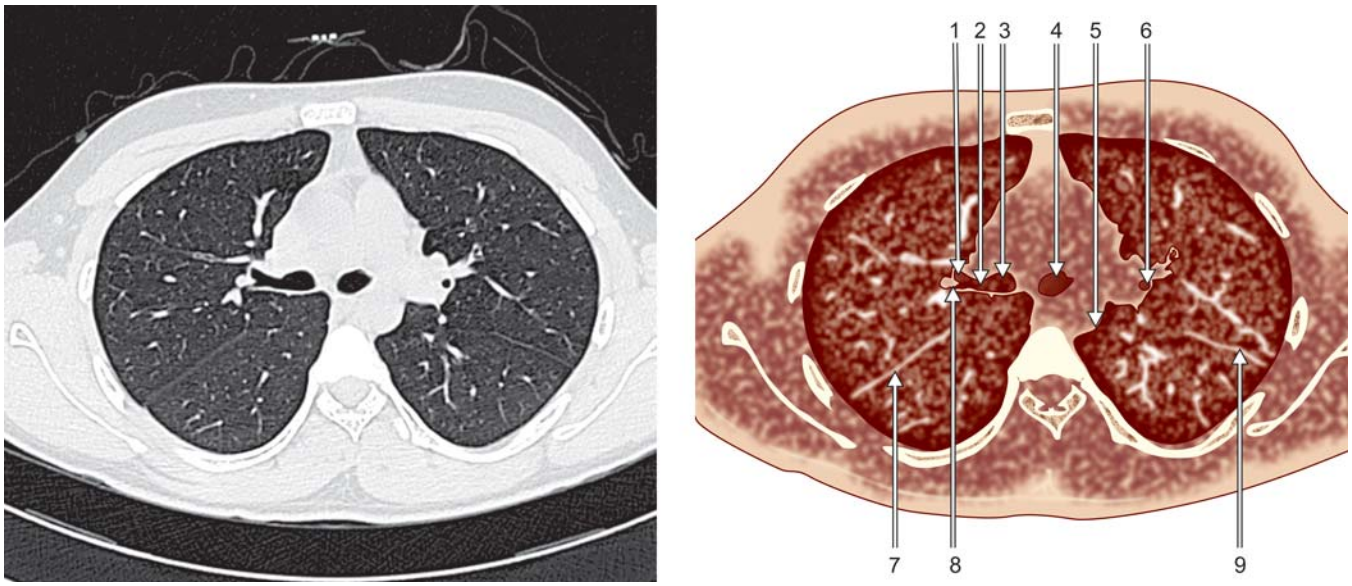

Figure 7.10

1. Anterior segment
2. Right upper lobe bronchus
3. Right mainstem bronchus
4. Left mainstem bronchus
5. Descending aorta
6. Apicoposterior bronchus
7. Major fissure
8. Posterior segment bronchus
9. Major fissure

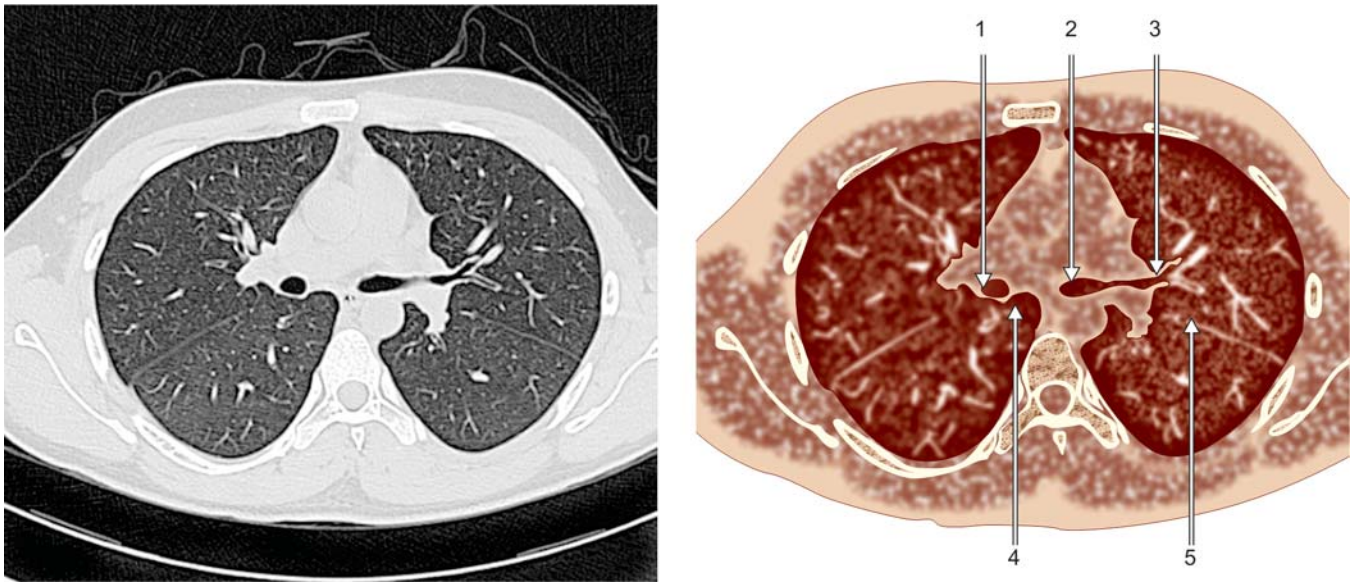

Figure 7.11

1. Bronchus intermedius
2. Left mainstem bronchus
3. Anterior segment bronchus
4. Azygoesophageal recess
5. Major fissure

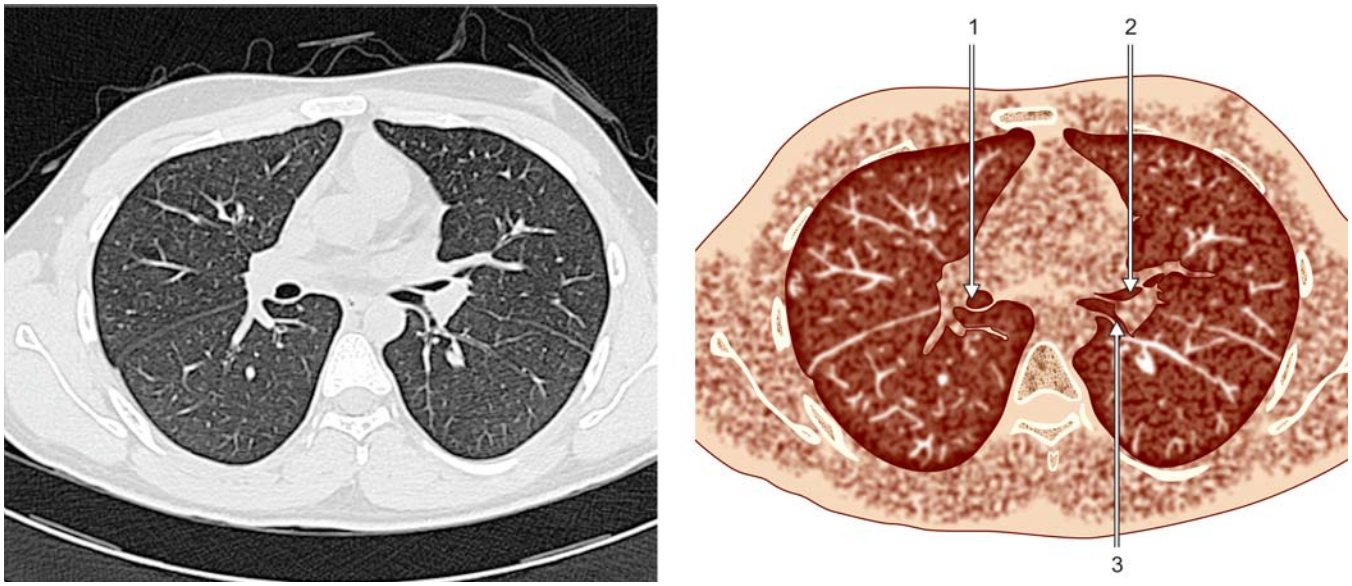

Figure 7.12

1. Bronchus intermedius
2. Lingular lobe bronchus
3. Superior basal segment bronchus

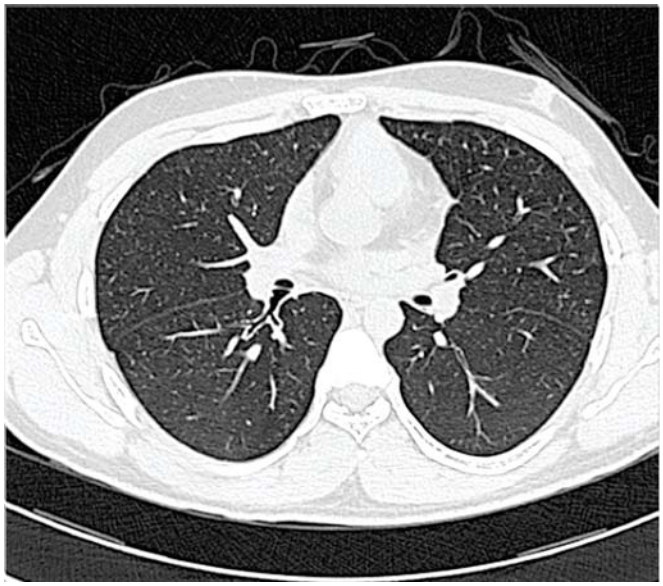

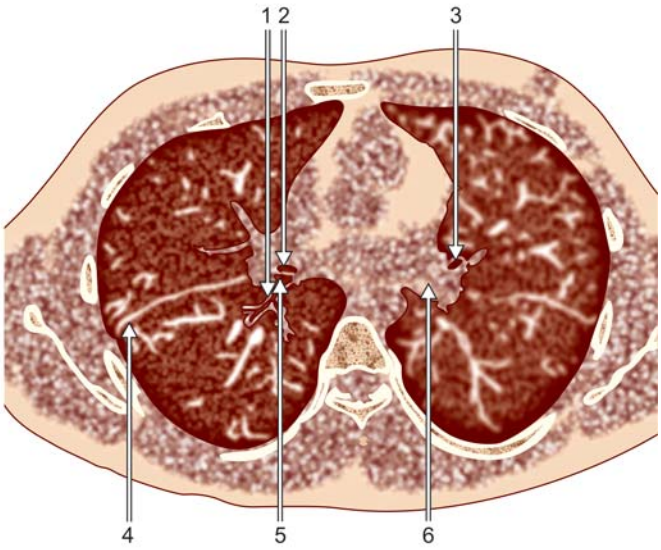

Figure 7.13

1. Superior basal segment bronchus
2. Middle lobe bronchus
3. Lingular lobe bronchus
4. Major fissure
5. Lower lobe bronchus
6. Lower lobe bronchus

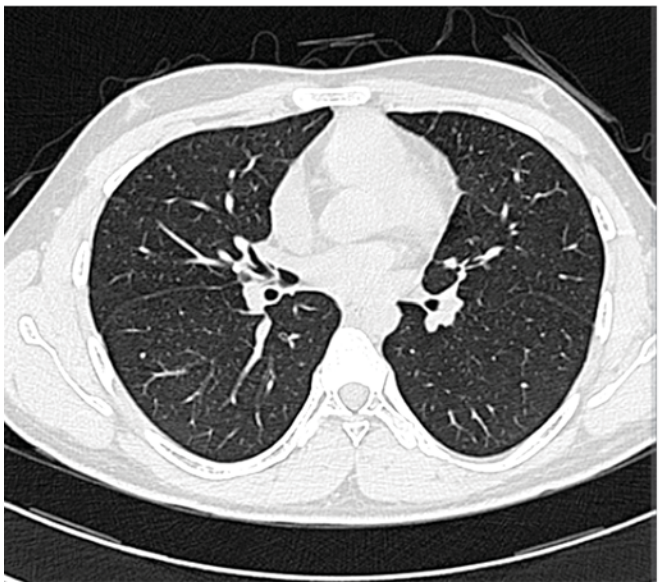

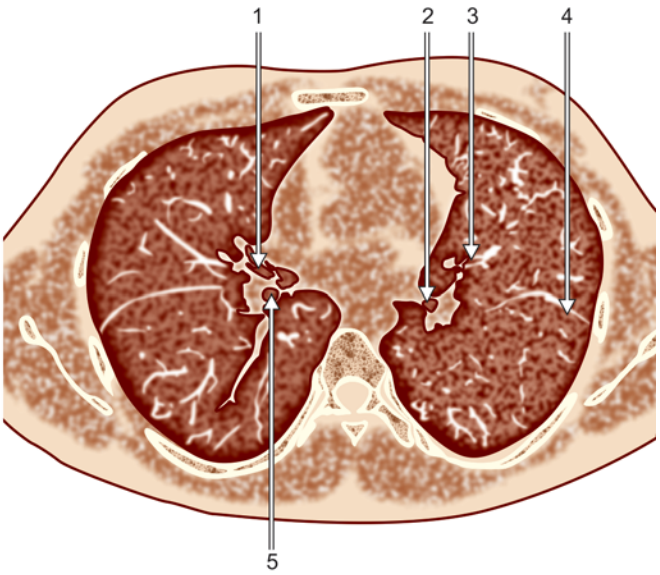

Figure 7.14

1. Middle lobe bronchus
2. Left lower lobe bronchus
3. Lingular lobe bronchus
4. Major fissure
5. Lower lobe bronchus

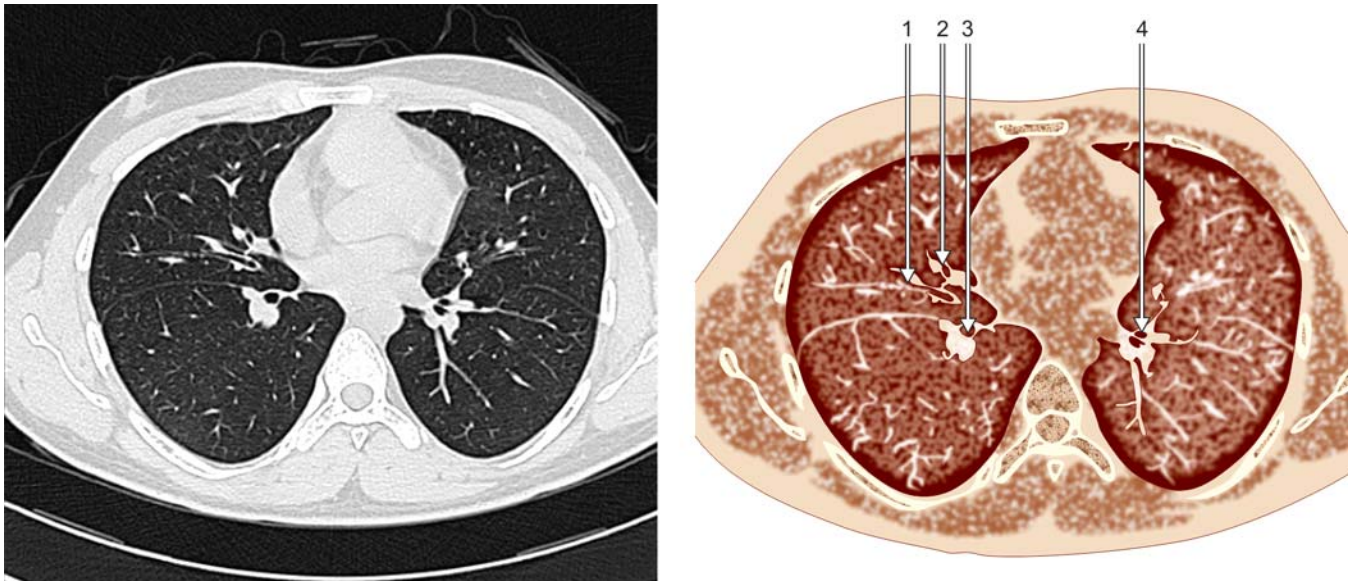

Figure 7.15

1. Bronchus of lateral segment of right middle lobe
2. Bronchus of medial segment of RML
3. Lower lobe bronchus
4. Left lower lobe bronchi

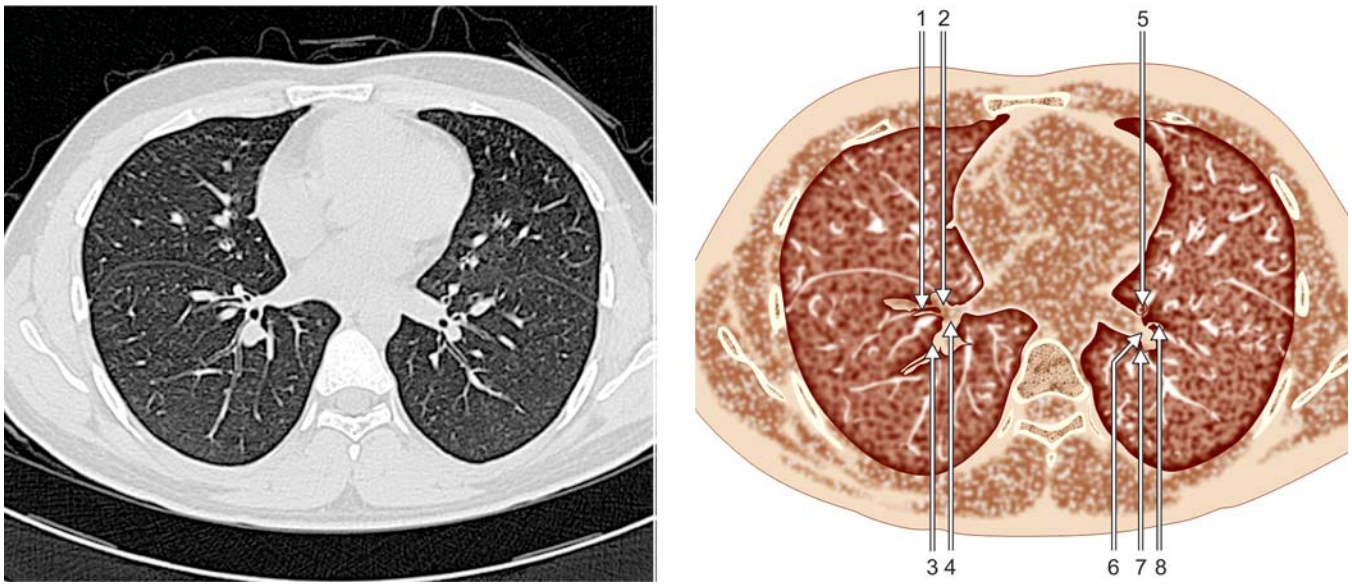

Figure 7.16

Segmental bronchi
1. Anterior basal
2. Medial basal
3. Lateral basal
4. Posterior basal

Lower lobe Segmental bronchi
5. Medial basal
6. Lateral basal
7. Posterior basal
8. Anterior basal

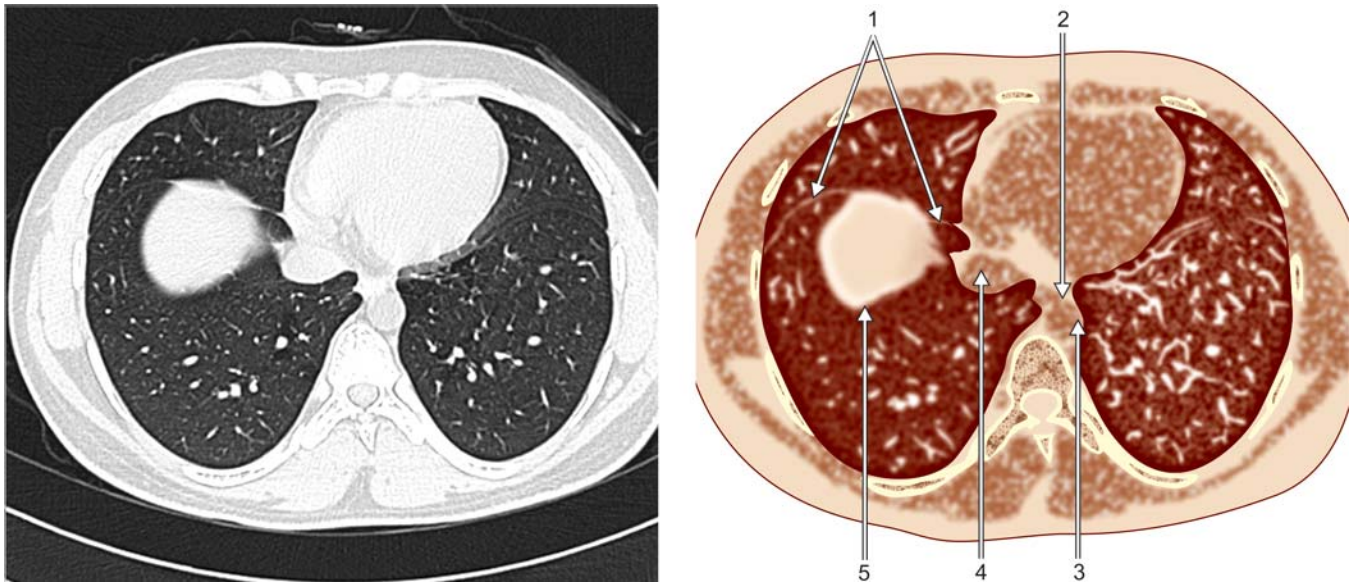

Figure 7.17

1. Major fissure
2. Esophagus
3. Descending aorta
4. IVC
5. Liver

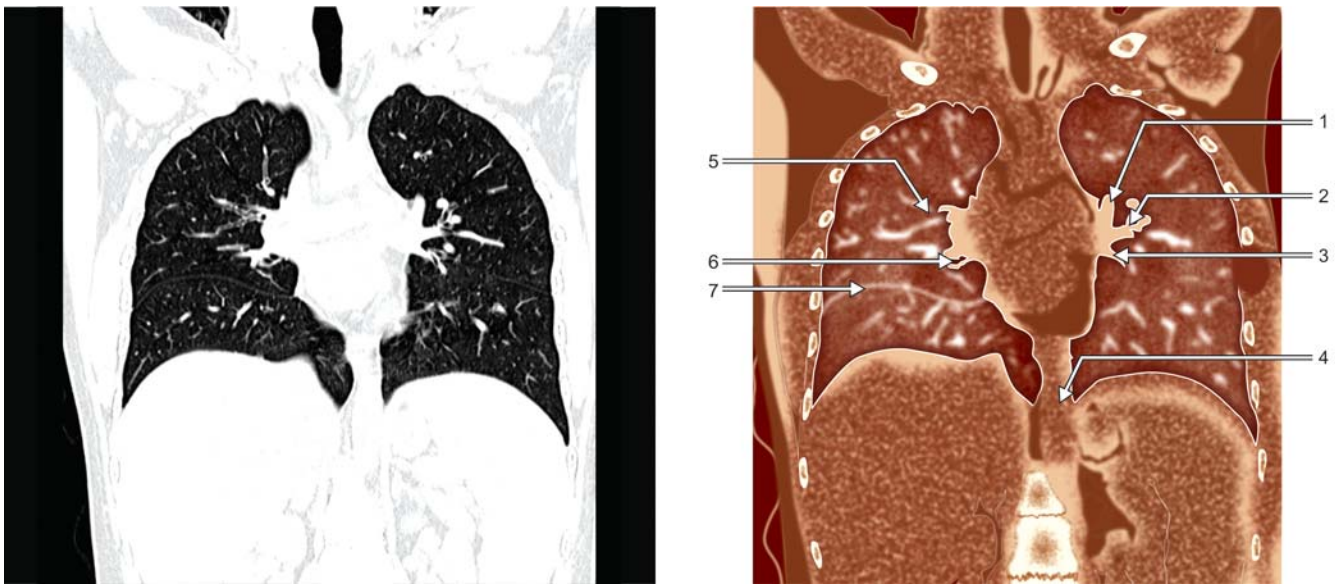

Figure 7.18

1. Left superior pulmonary vein
2. Anterior segment bronchus
3. Lingular lobe bronchi
4. Descending aorta
5. Anterior segment bronchi
6. Middle lobe bronchus
7. Major fissure

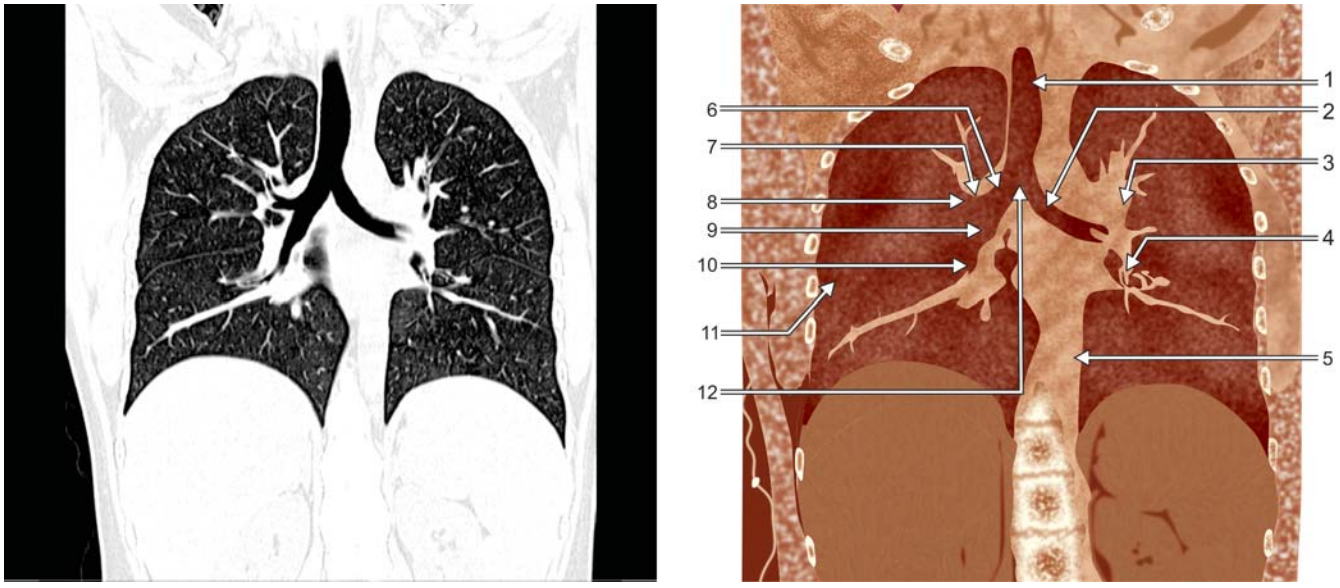

Figure 7.19

1. Trachea
2. Left mainstem bronchus
3. Apicoposterior segment bronchus
4. Lower lobe bronchi
5. Descending aorta
6. Right mainstem bronchus
7. Right upper lobe bronchus
8. Apical segment bronchus
9. Posterior segment bronchi
10. Bronchus intermedius
11. Major fissure
12. Carina

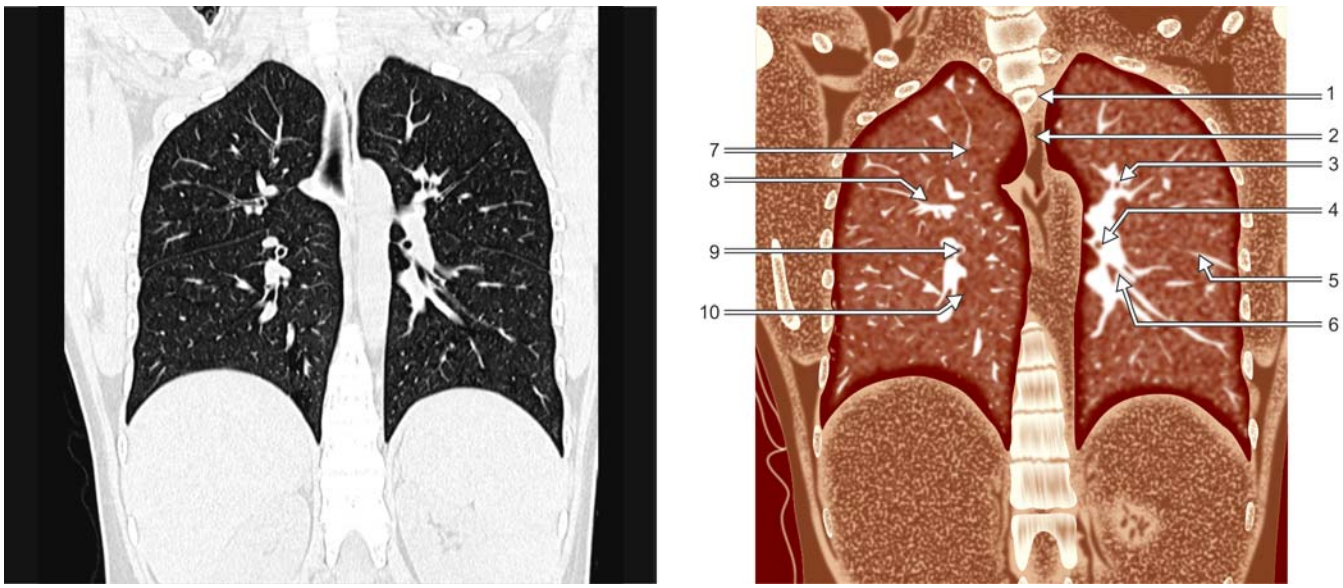

Figure 7.20

1. Air in the esophagus
2. Trachea
3. Apicoposterior segment bronchus
4. Superior basal segment bronchus
5. Major fissure
6. Lower lobe segment bronchus
7. Apical segment bronchus
8. Posterior segment bronchus
9. Superior basal segment bronchus
10. Lower lobe segment bronchus



Figure 7.21

1. Air in the esophagus
2. Apicoposterior segment bronchus
3. Superior basal segment bronchus
4. Major fissure
5. Lower lobe segment bronchus
6. Posterior segment bronchus
7. Superior basal segment bronchus
8. Lower lobe segment bronchus

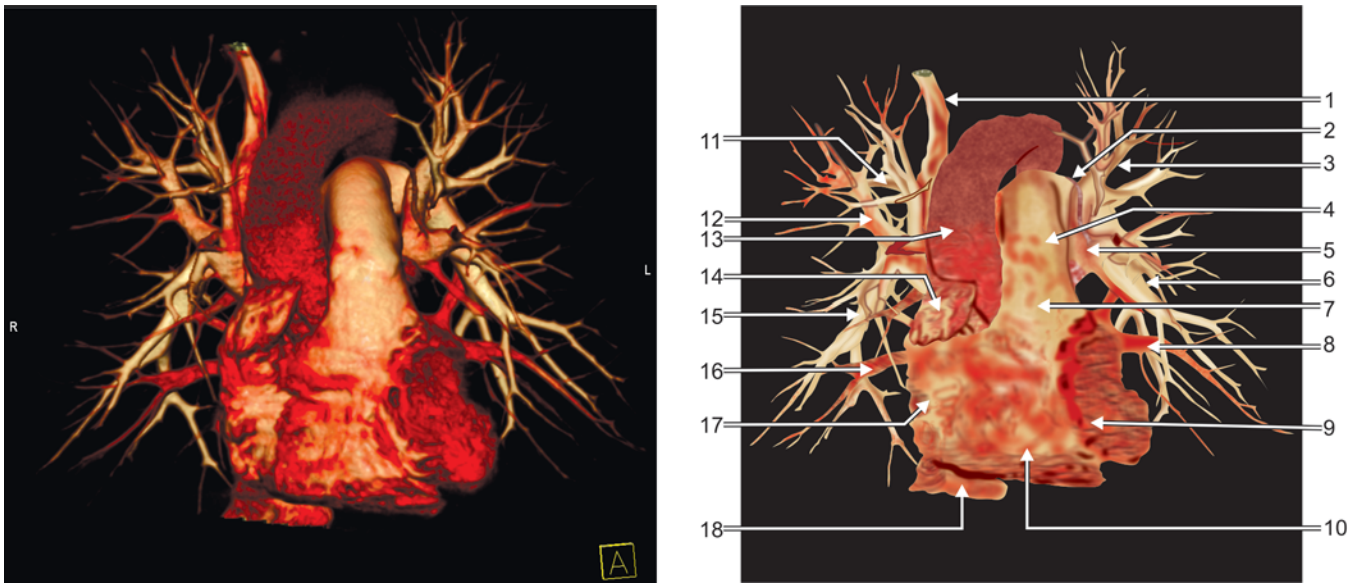

Figure 7.22

1. SVC
2. Left pulmonary artery
3. Sup. pulmonary artery
4. Main pulmonary artery
5. Sup. pulmonary vein
6. Inf. pulmonary artery
7. Infundibulum
8. Inf. pulmonary vein
9. Left ventricle
10. Right ventricle
11. Sup. pulmonary artery
12. Sup. pulmonary vein
13. Aorta
14. RAA
15. Inf. pulmonary artery
16. Inf. pulmonary vein
17. Right atrium
18. IVC

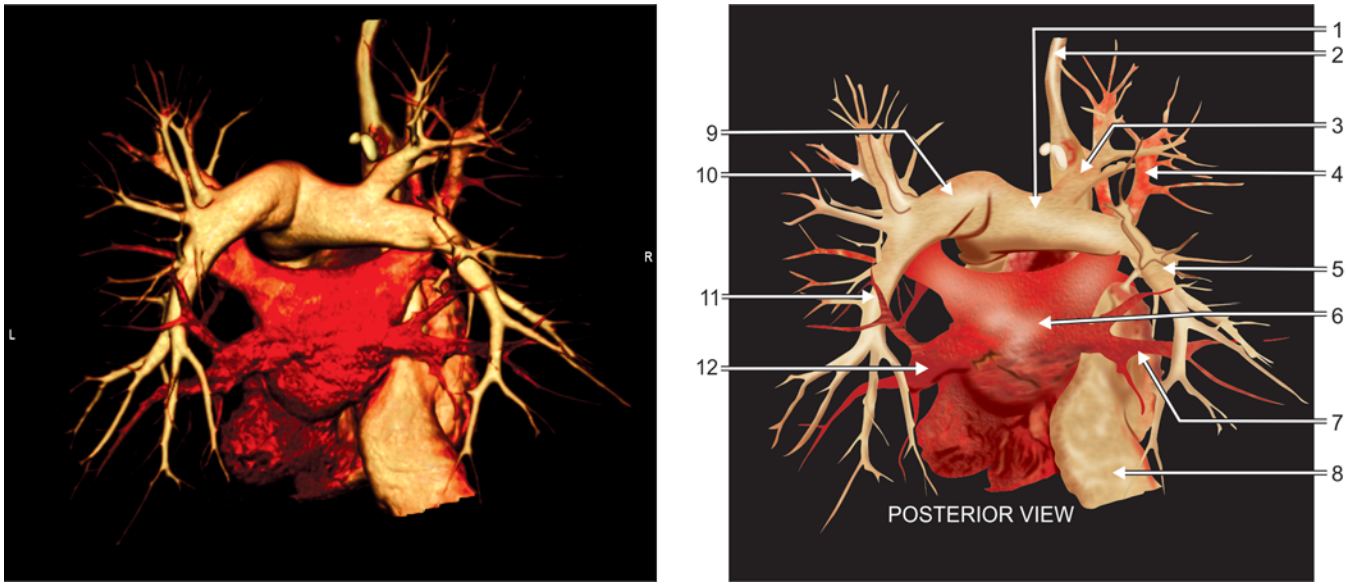

Figure 7.23

1. Right main pulmonary artery
2. SVC
3. RT superior pulmonary artery
4. Superior pulmonary vein
5. Inferior pulmonary artery
6. Left atrium
7. Inferior pulmonary vein
8. IVC
9. Left main pulmonary artery
10. Superior pulmonary vein
11. Inferior pulmonary artery
12. Inferior pulmonary vein

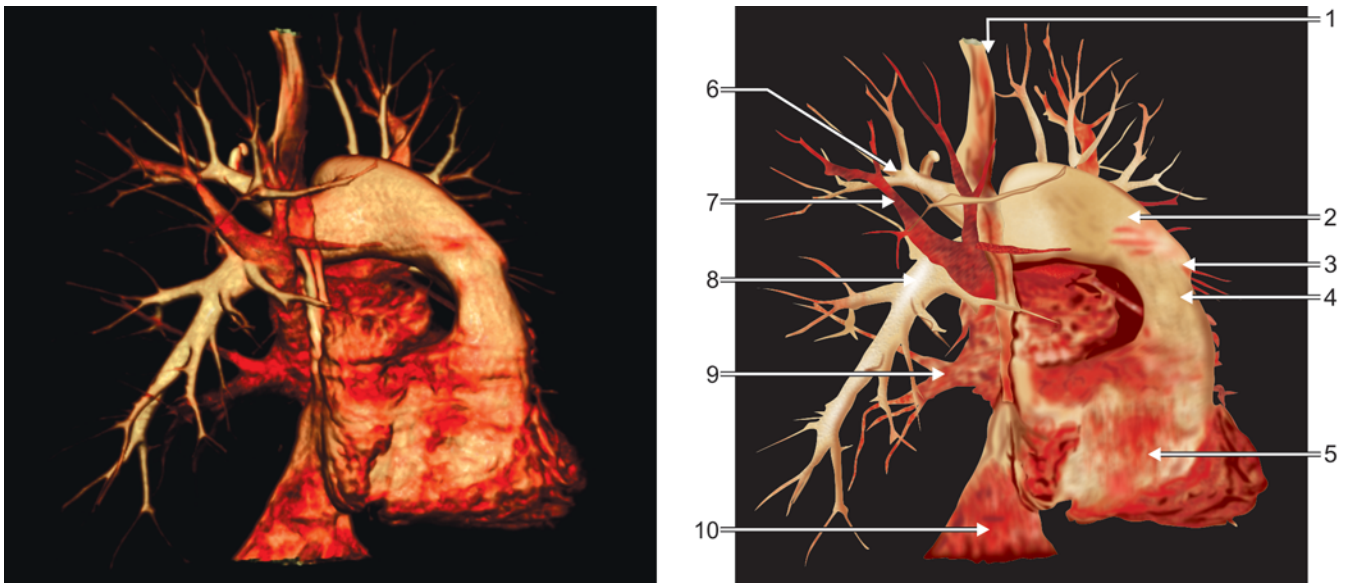

Figure 7.24

1. SVC
2. Main pulmonary artery
3. Pulmonic valve
4. Infundibulum
5. Right ventricle
6. Right superior pulmonary artery
7. Right superior pulmonary vein
8. Inferior pulmonary artery
9. Inferior pulmonary vein
10. IVC

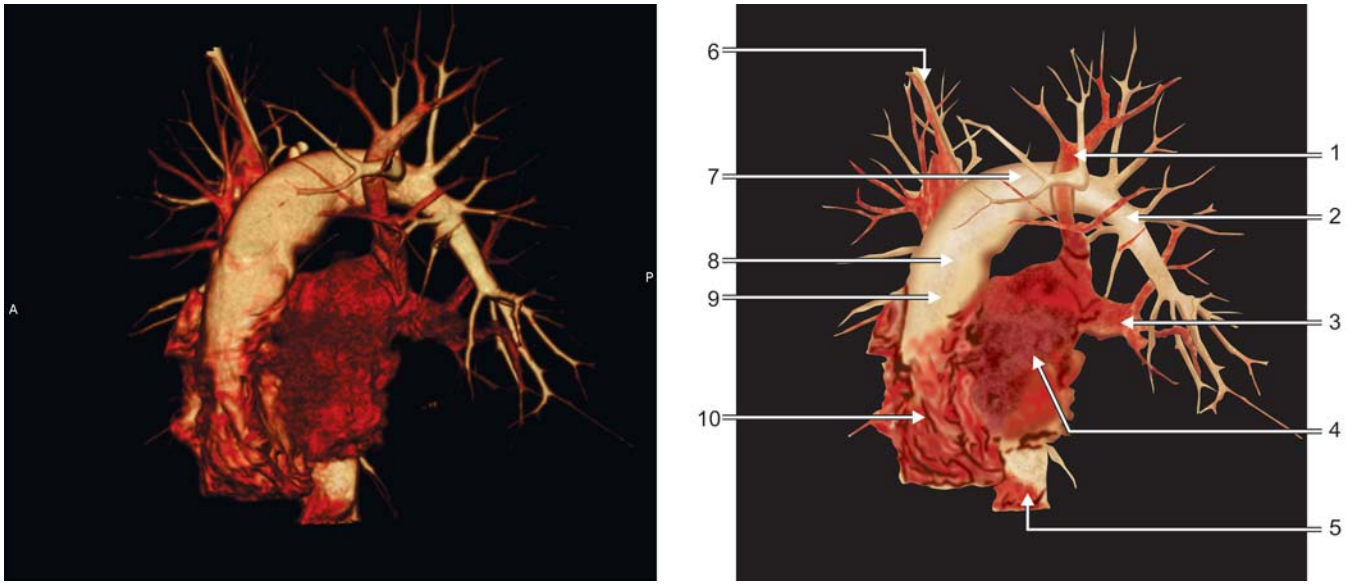

Figure 7.25

1. Left superior pulmonary vein
2. Left inferior pulmonary artery
3. Left inferior pulmonary vein
4. Left atrium
5. IVC
6. SVC
7. Left pulmonary artery
8. Pulmonic valve
9. Infundibulum
10. Right ventricle

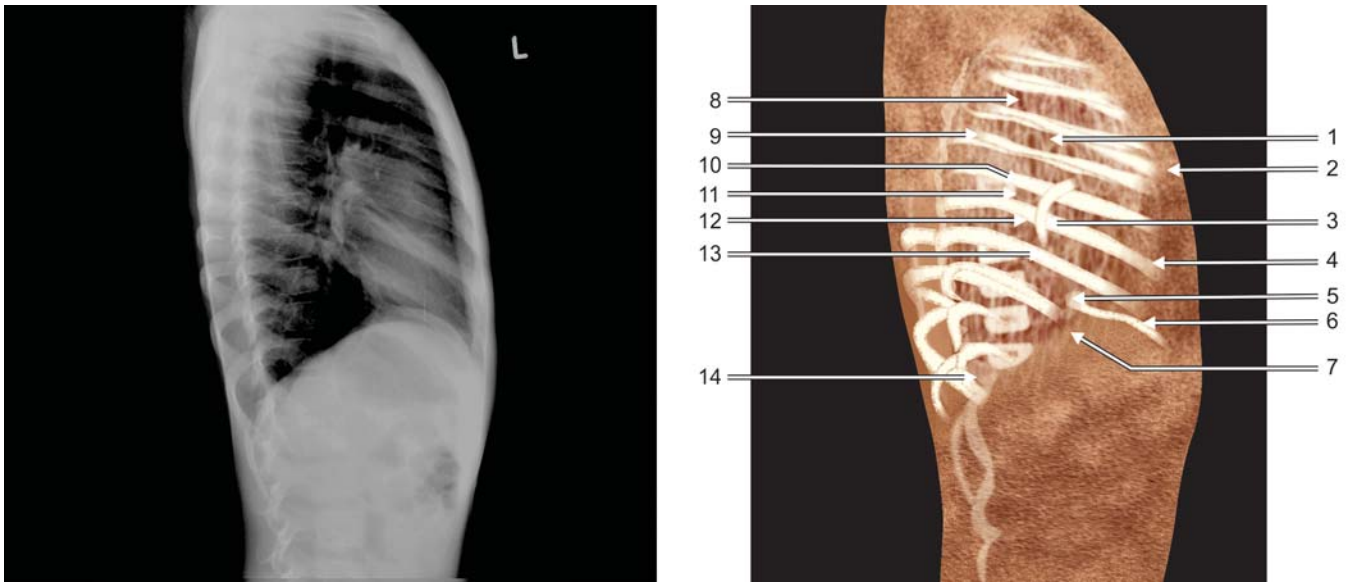

Figure 7.26

1. Arch of aorta
2. Sternum
3. Right pulmonary artery
4. Anterior cardiac border formed by RV
5. IVC
6. Right diaphragm
7. Left dome of diaphragm effaced by heart anteriorly
8. Trachea
9. Scapula
10. Left main pulmonary artery
11. Left main bronchus
12. Right main bronchus
13. Left atrial border
14. Posterior costophrenic recess

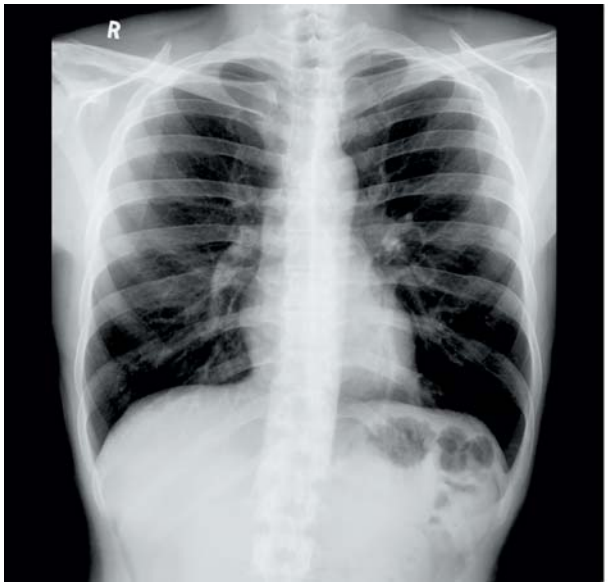

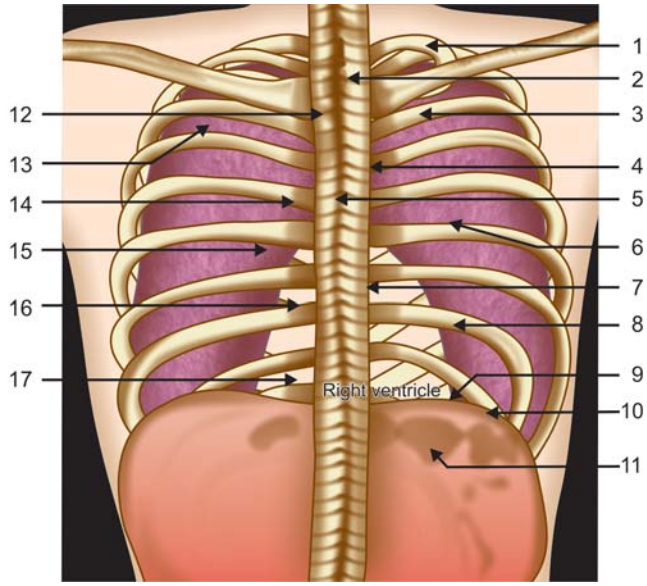

Figure 7.27

1. First rib
2. Spinous process
3. Posterior rib
4. Aortic knuckle
5. Carina
6. Left pulmonary artery
7. Descending aorta
8. Left ventricle
9. Cardiophrenic angle
10. Left dome of diaphragm
11. Fundic gas bubble
12. Trachea
13. Anterior rib
14. Superior vena cava
15. Right pulmonary artery
16. Right atrium
17. IVC

CHAPTER 8

Abdomen

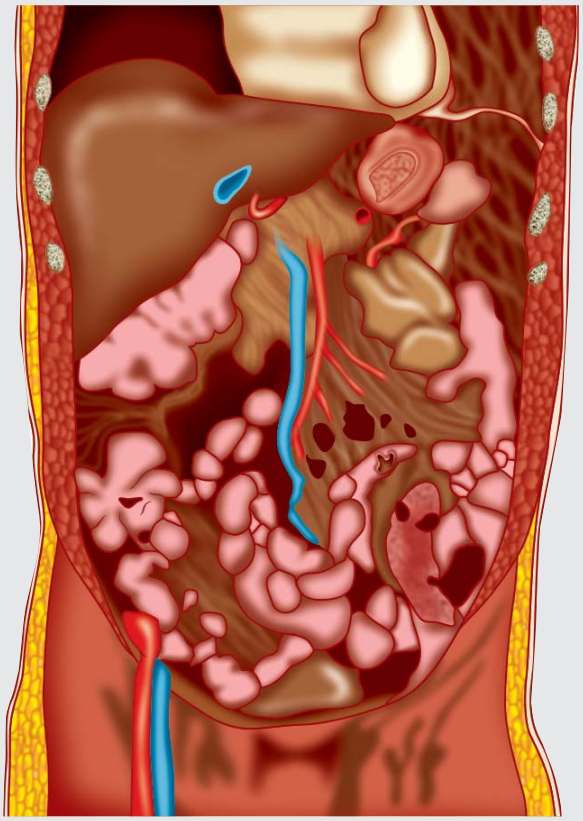

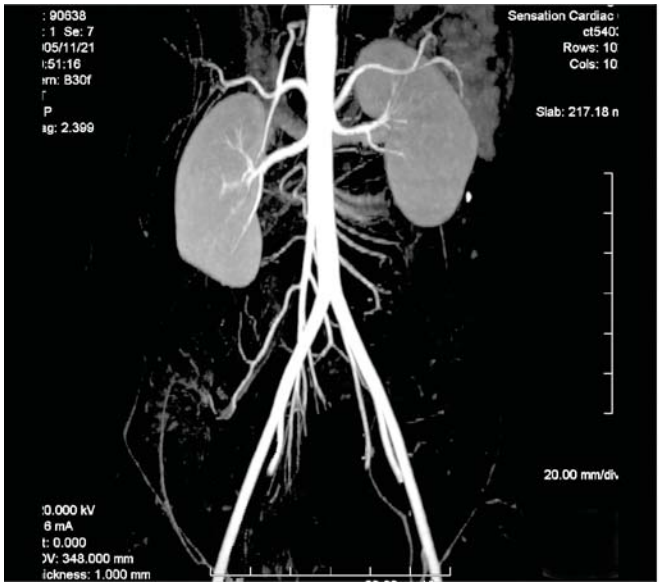

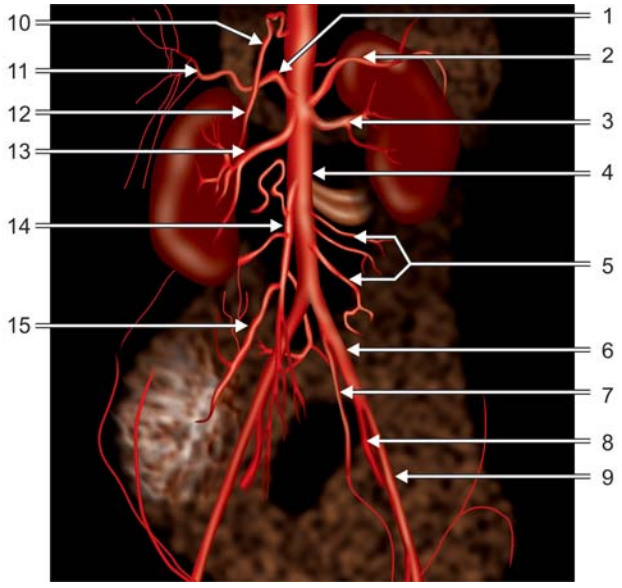

Figure 8.1

1. Hepatic artery
2. Splenic artery
3. Left renal artery
4. Aorta
5. Jejunal branches of SMA
6. Common iliac artery
7. Inferior mesenteric artery
8. Internal iliac artery
9. External iliac artery
10. Left hepatic artery
11. Right hepatic artery
12. Gastroduodenal artery
13. Right renal artery
14. Superior mesenteric artery
15. Ileocolic artery

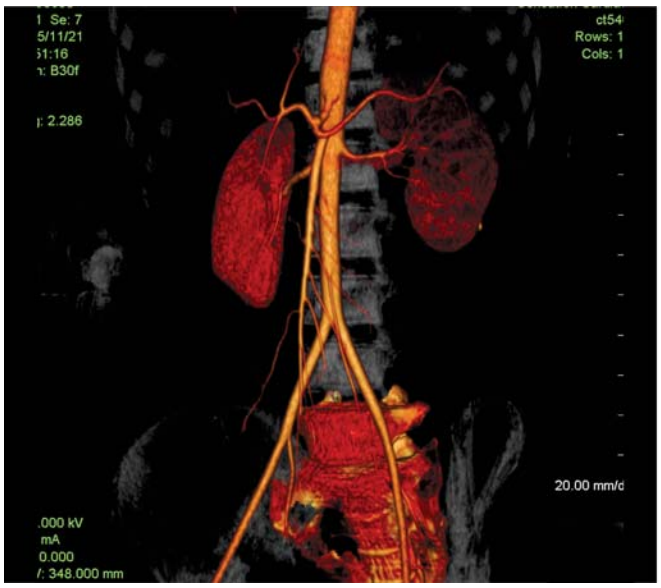

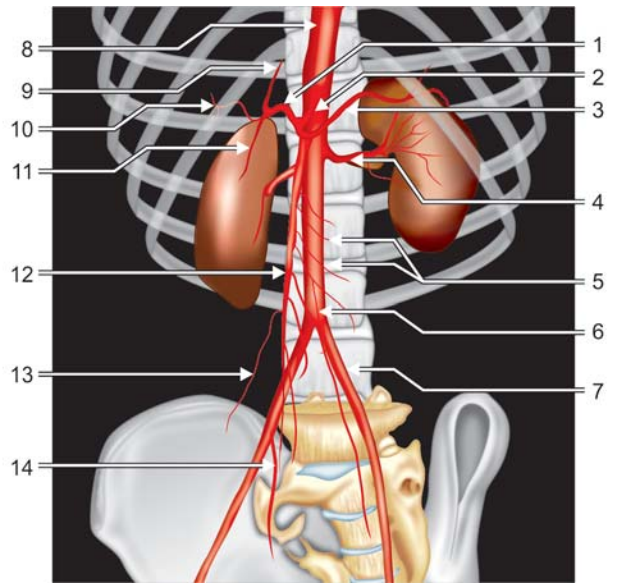

Figure 8.2

1. Hepatic artery
2. Celiac artery
3. Splenic artery
4. Left renal artery
5. Jejunal branches
6. Inferior mesenteric artery
7. Left common iliac artery
8. Aorta
9. Left hepatic artery
10. Right hepatic artery
11. Gastroduodenal artery
12. Superior mesenteric artery
13. Ileocolic artery
14. Right internal iliac artery

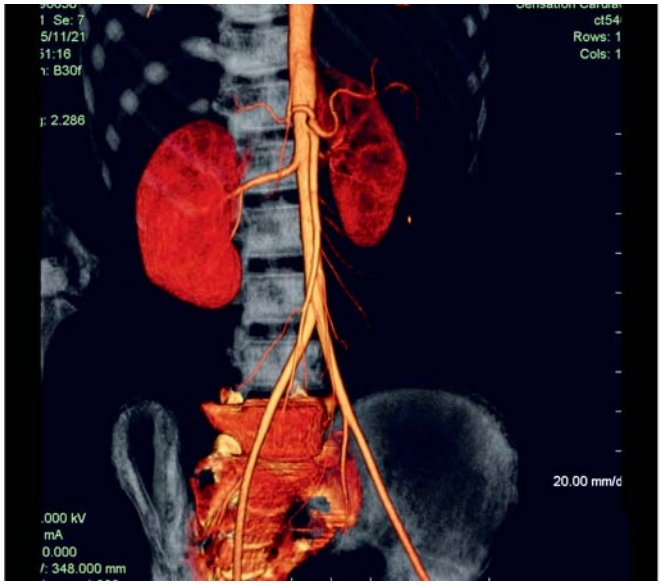

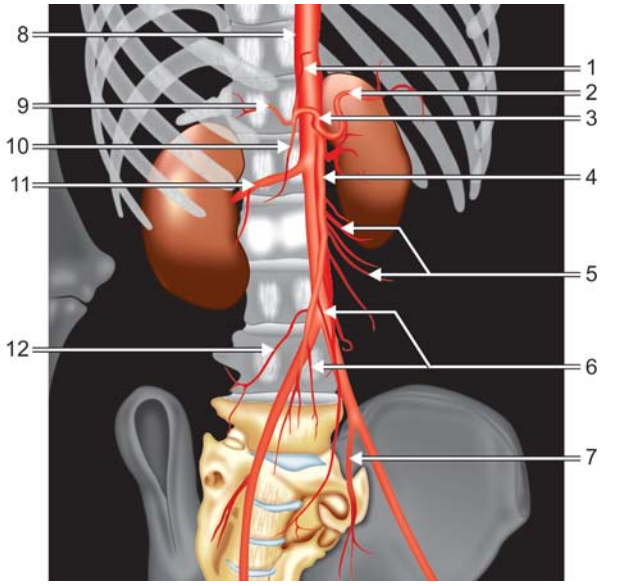

Figure 8.3

1. Left hepatic artery
2. Splenic artery
3. Celiac artery
4. Superior mesenteric artery
5. Jejunal branches
6. Iliac branches
7. Left internal iliac artery
8. Aorta
9. Right hepatic artery
10. Gastroduodenal artery
11. Right renal artery
12. Ileocolic artery



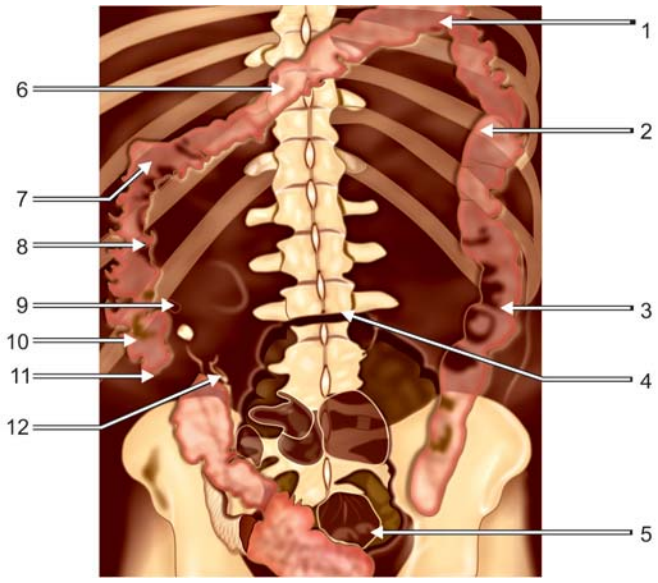

Figure 8.4

Large Intestine

1. Splenic flexure
2. Descending colon
3. Haustra
4. Sigmoid colon
5. Rectum
6. Transverse colon
7. Hepatic flexure
8. Ascending colon
9. IC junction
10. Caecum
11. Appendix
12. Terminal ileum



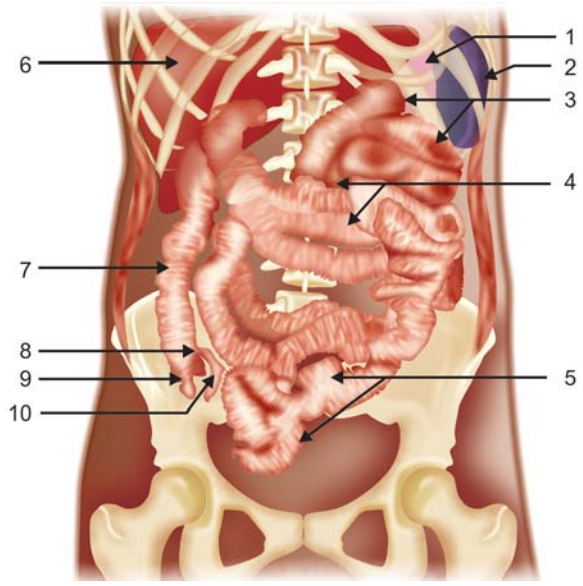

Figure 8.5

Small Intestine

1. Fundic bubble
2. Spleen
3. Jejunal loops
4. Valvulae conniventes
5. Ileal loops
6. Liver
7. Ascending colon
8. Ileocecal junction
9. Cecum
10. Terminal ileum

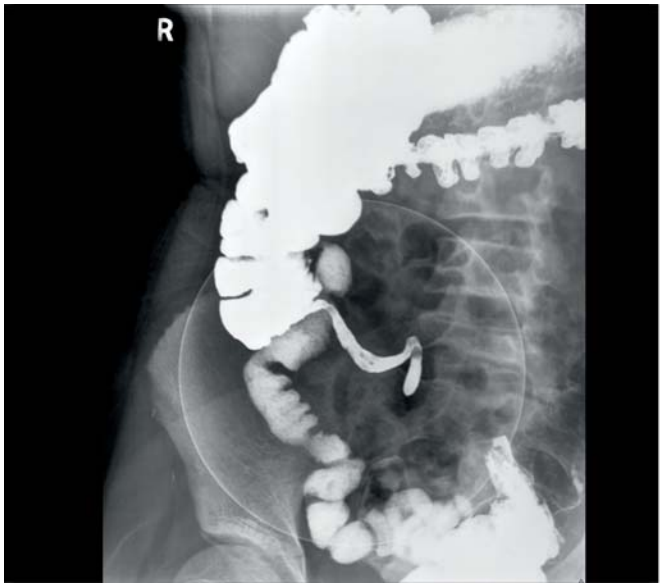

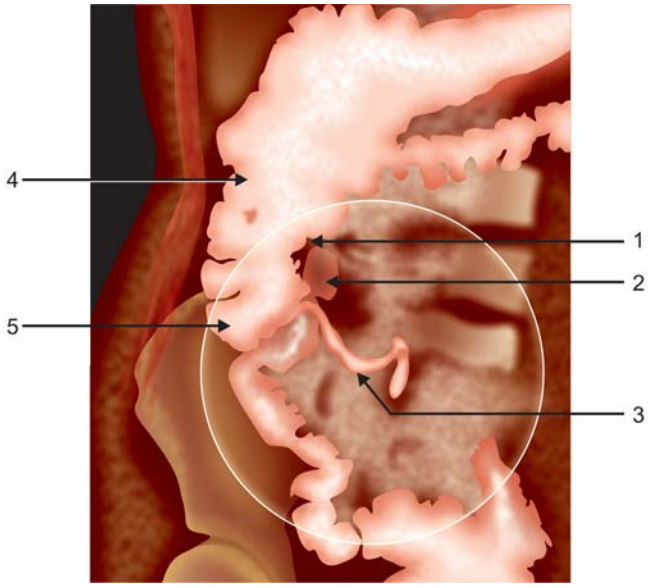

Figure 8.6

1. Ileocecal junction
2. Terminal ileum
3. Appendix
4. Ascending colon
5. Cecum

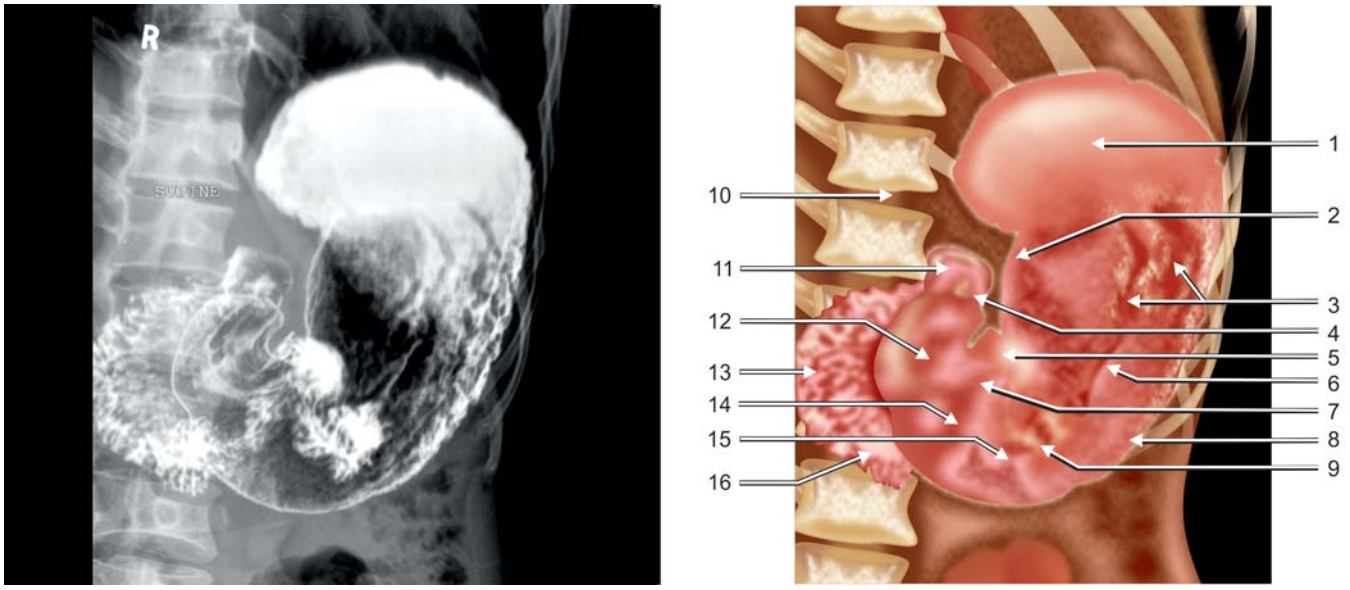

Figure 8.7

1. Fundus
2. Lesser curvature
3. Gastric rugae
4. Pyloric canal
5. Incisura angularis, stomach
6. Stomach, body
7. Duodenojejunal junction
8. Greater curvature
9. Jejunum
10. Disk space
11. Duodenal cap (D1)
12. Pyloric antrum
13. Duodenum, D2
14. D4
15. Antrum
16. Duodenum, D3

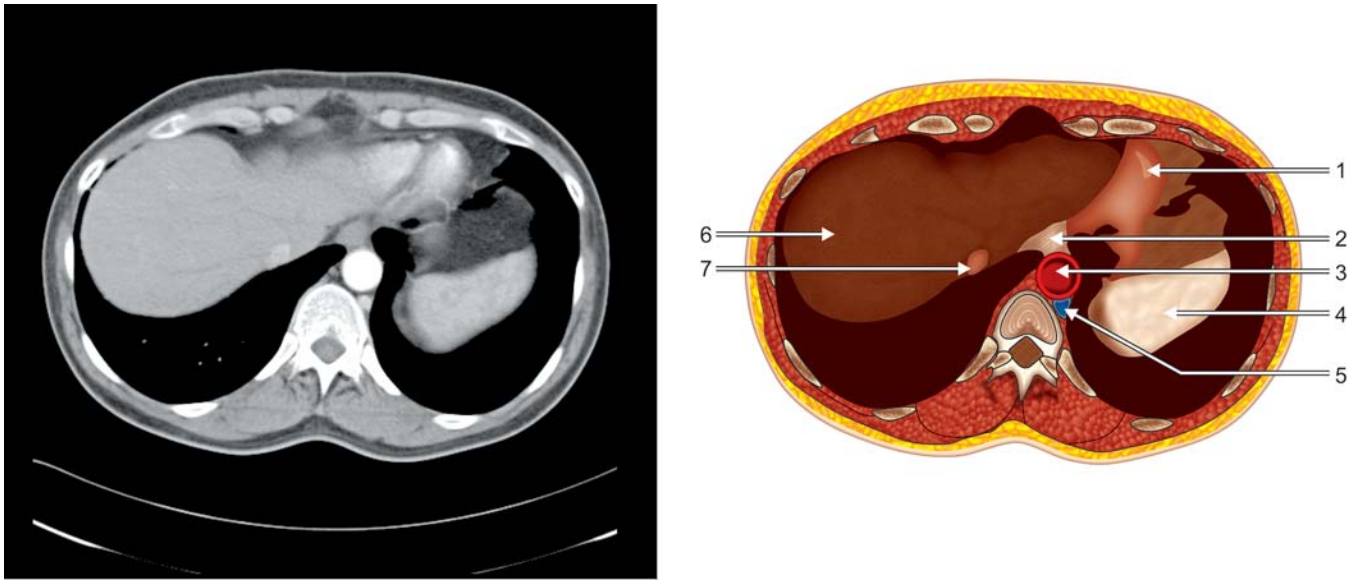

Figure 8.8

1. Heart
2. Esophagus
3. Aorta
4. Spleen
5. Azygos vein
6. Liver
7. IVC

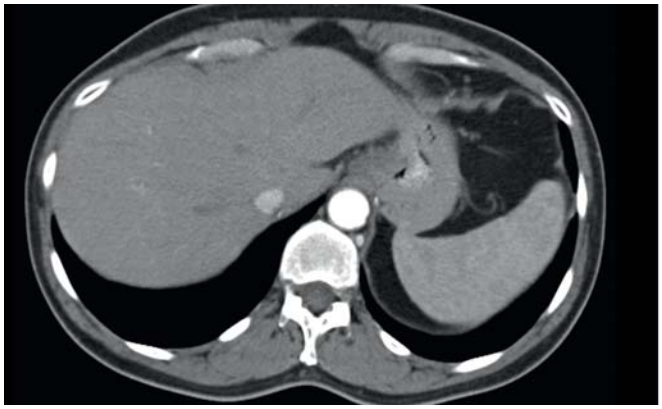

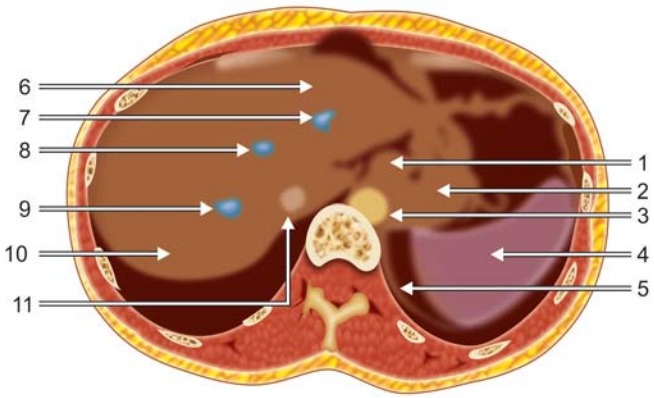

Figure 8.9

1. GE junction
2. Stomach
3. Descending aorta
4. Spleen
5. Diaphragm
6. Left hepatic lobe
7. Left hepatic vein
8. Middle hepatic vein
9. Right hepatic vein
10. Liver
11. IVC

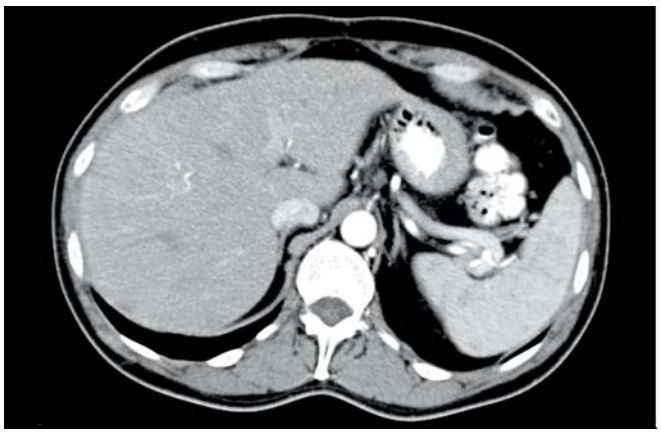

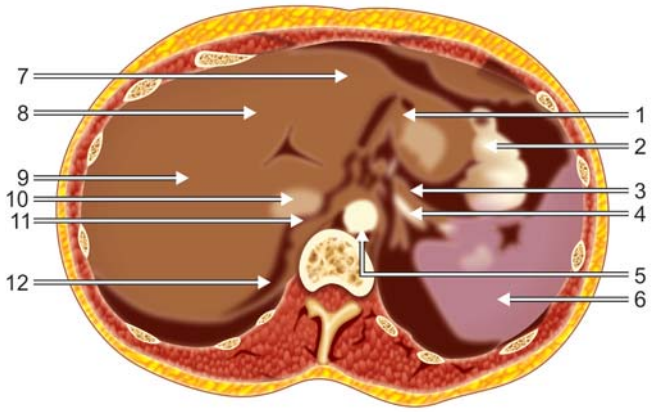

Figure 8.10

1. Stomach
2. Splenic flexure of colon
3. Splenic vein
4. Splenic artery
5. Aorta
6. Spleen
7. Left lobe of liver
8. Left portal vein
9. Right lobe of liver
10. IVC
11. Crura of diaphragm
12. Diaphragm

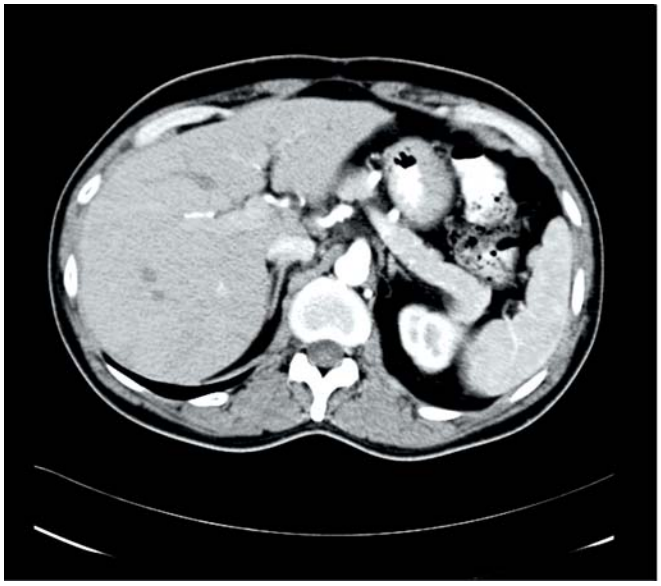

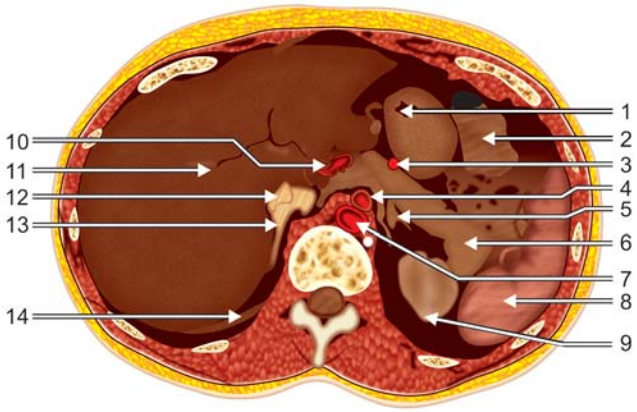

Figure 8.11

1. Stomach
2. Splenic flexure
3. Splenic artery
4. Celiac trunk
5. Left adrenal gland
6. Tail of pancreas
7. Aorta
8. Spleen
9. Left kidney
10. Hepatic artery
11. Right portal vein
12. IVC
13. Right adrenal gland
14. Diaphragm

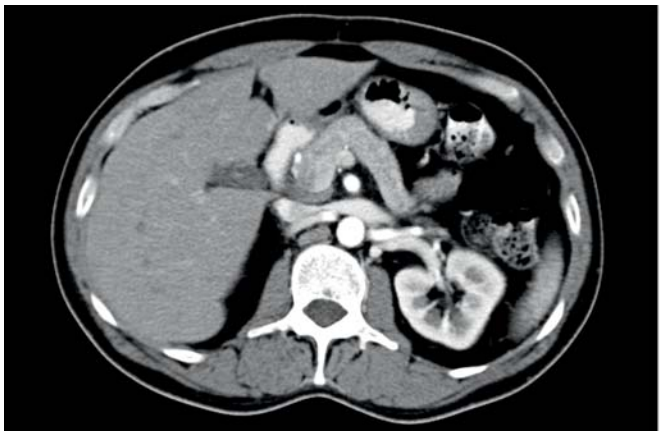

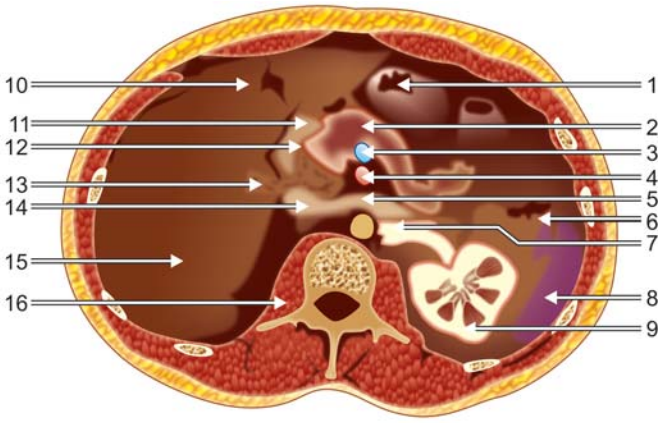

Figure 8.12

1. Stomach
2. Body of pancreas
3. Superior mesenteric vein
4. Superior mesenteric artery
5. Left renal vein
6. Descending colon
7. Left renal artery
8. Spleen
9. Left kidney
10. Fissure for ligamentum venosum
11. Duodenum
12. Gastroduodenal artery
13. Gallbladder neck
14. IVC
15. Right lobe of liver
16. Psoas

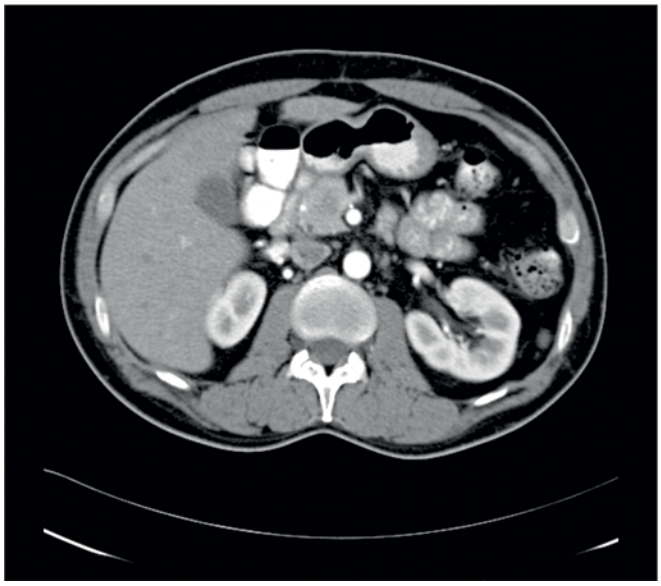

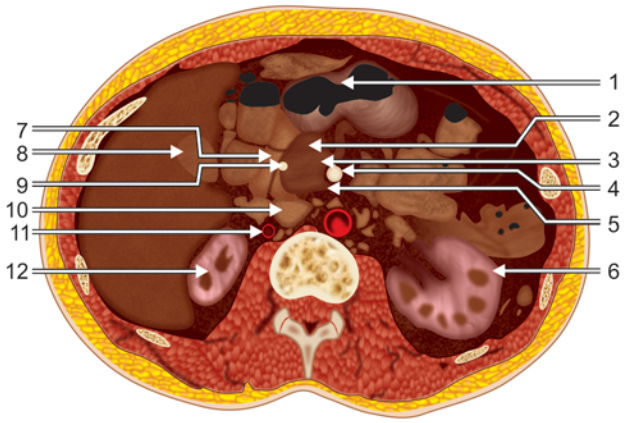

Figure 8.13

1. Stomach
2. Head of pancreas
3. SMV
4. SMA
5. Uncinate process, pancreas
6. Left kidney
7. Duodenum
8. Gallbladder
9. Gastroduodenal artery
10. IVC
11. Right renal artery
12. Right kidney



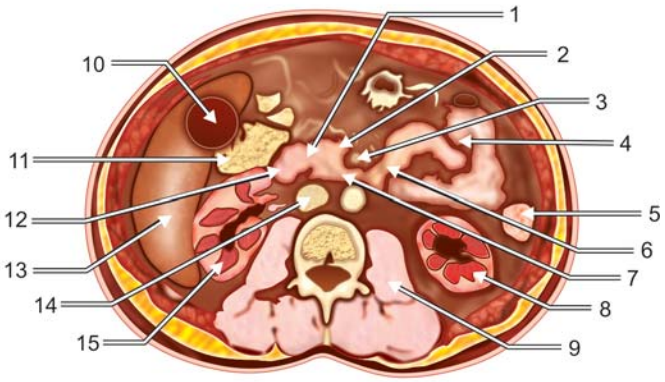

Figure 8.14

1. Head of pancreas
2. SMV
3. SMA
4. Jejunal loops
5. Descending colon
6. Duodenojejunal flexure
7. Uncinate process
8. Left kidney
9. Psoas
10. Gallbladder
11. Hepatic flexure
12. Duodenum
13. Liver
14. IVC
15. Right kidney

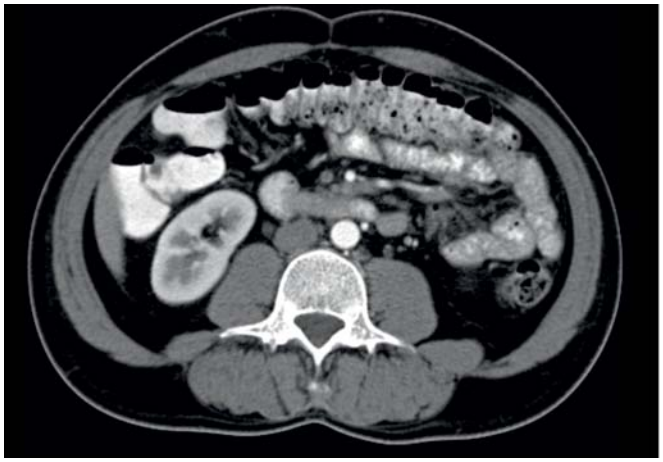

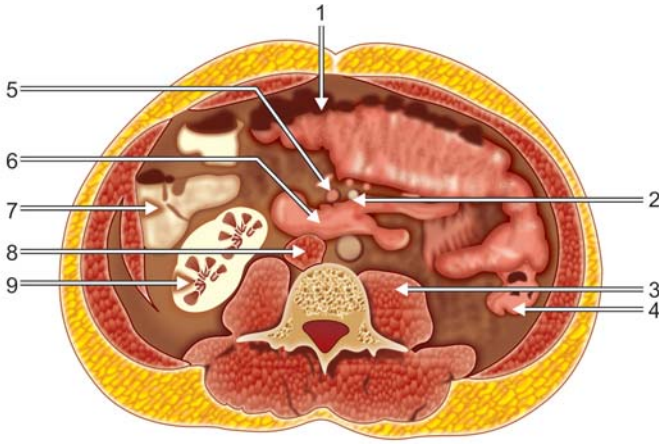

Figure 8.15

1. Transverse colon
2. SMA
3. Psoas
4. Descending colon
5. SMV
6. Duodenum, third part
7. Ascending colon
8. IVC
9. Right kidney

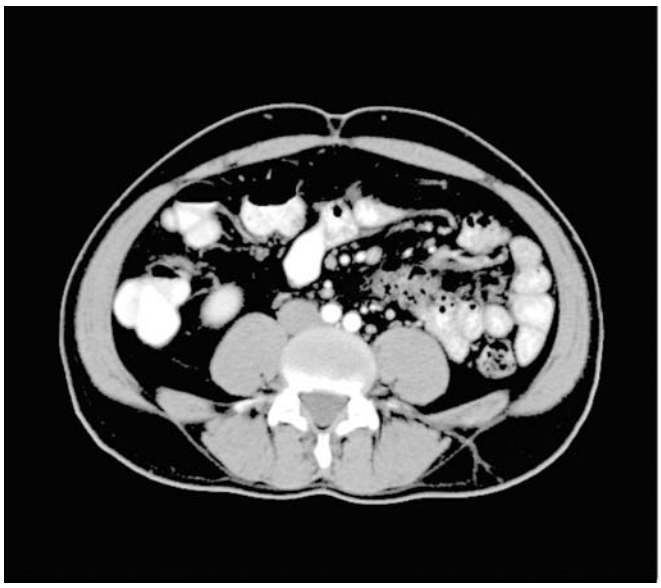

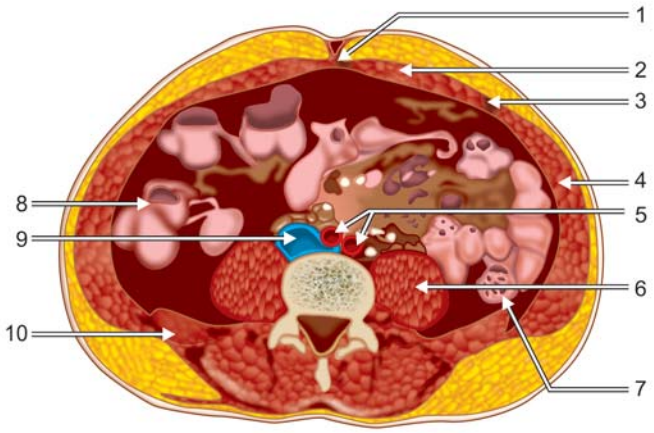

Figure 8.16

1. Linea alba
2. Rectus abdominis
3. Linea semilunaris
4. Oblique muscle
5. RT & LT common iliac arteries
6. Psoas
7. Descending colon
8. Ascending colon
9. IVC
10. Quadratus lumborum



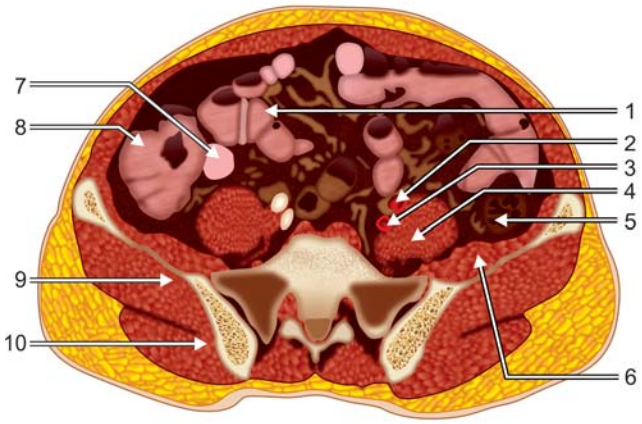

Figure 8.17

1. Iliac loops
2. Left external iliac artery
3. Left internal iliac artery
4. Psoas
5. Descending colon
6. Iliacus
7. Terminal ileum
8. caecum
9. Gluteus medius
10. Gluteus maximus



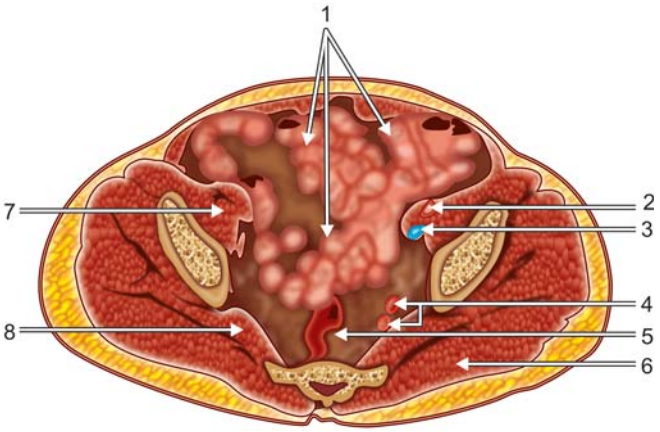

Figure 8.18

1. Ileal loops
2. External iliac artery
3. External iliac vein
4. Internal iliac branches
5. Rectum
6. Gluteus maximus
7. Iliopsoas
8. Piriformis muscle

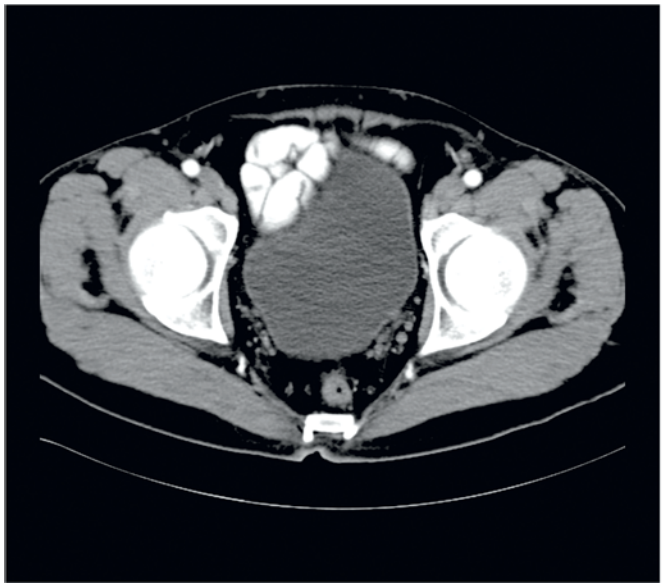

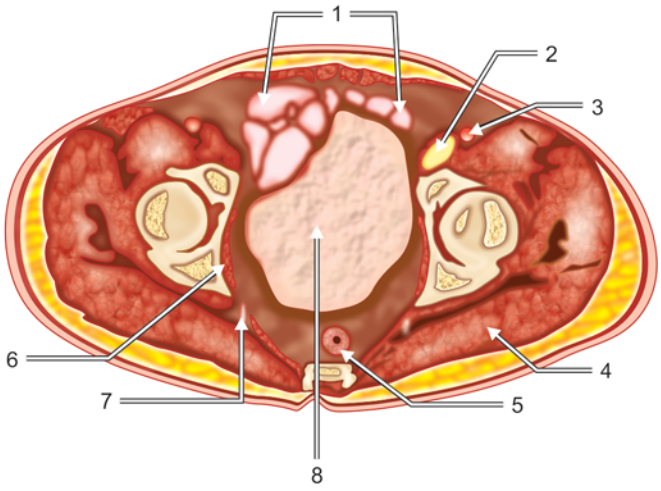

Figure 8.19

1. Iliac loops
2. Femoral vein
3. Femoral artery
4. Gluteus maximus
5. Rectum
6. Obturator internus
7. Inferior gluteal artery
8. Urinary bladder

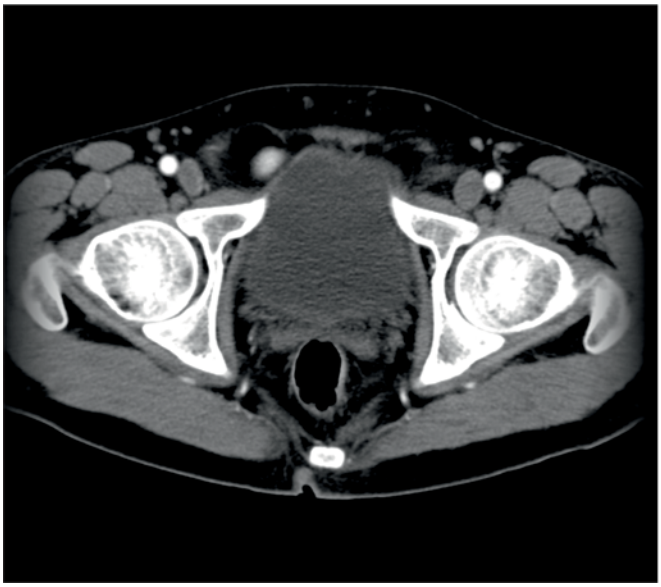

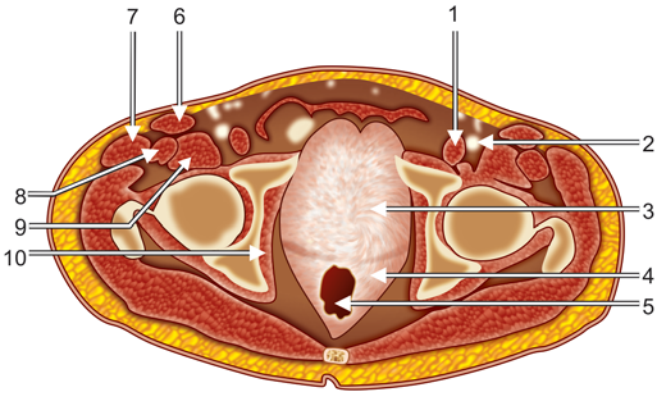

Figure 8.20

1. Femoral vein
2. Femoral artery
3. Urinary bladder
4. Seminal vesicle
5. Rectum
6. Sartorius
7. Tensor fascia lata muscle
8. Rectus femoris
9. Iliopsoas
10. Obturator internus



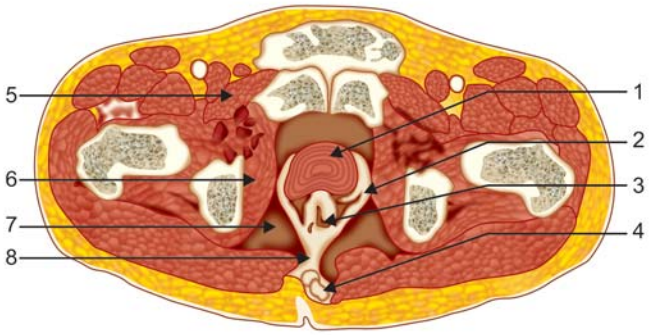

Figure 8.21

1. Prostate gland
2. Levator ani muscle
3. Anal canal
4. Coccyx
5. Pectineus muscle
6. Obturator internus
7. Ischiorectal fossa
8. Coccygeus

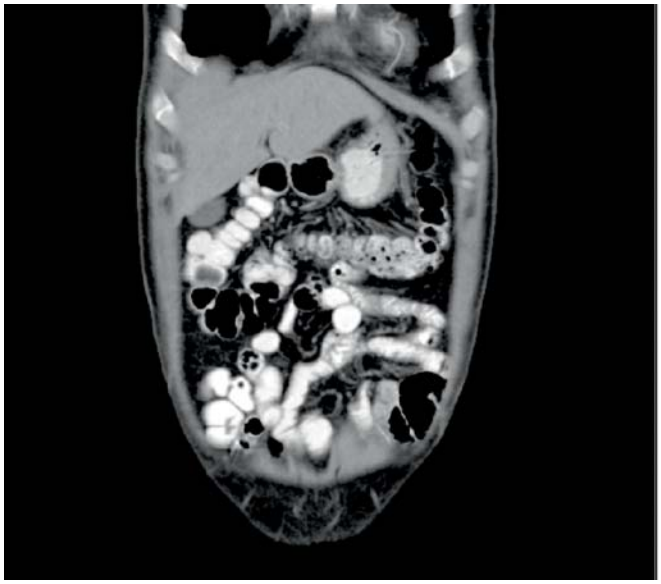

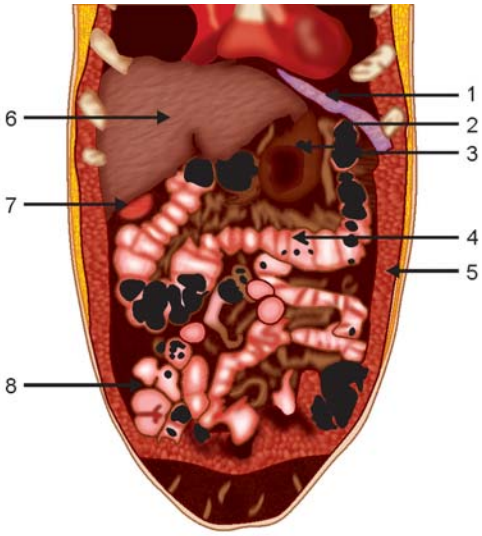

Figure 8.22

1. Diaphragm
2. Splenic flexure
3. Stomach
4. Transverse colon
5. Abdominal wall
6. Liver
7. Gallbladder
8. Ileal loops

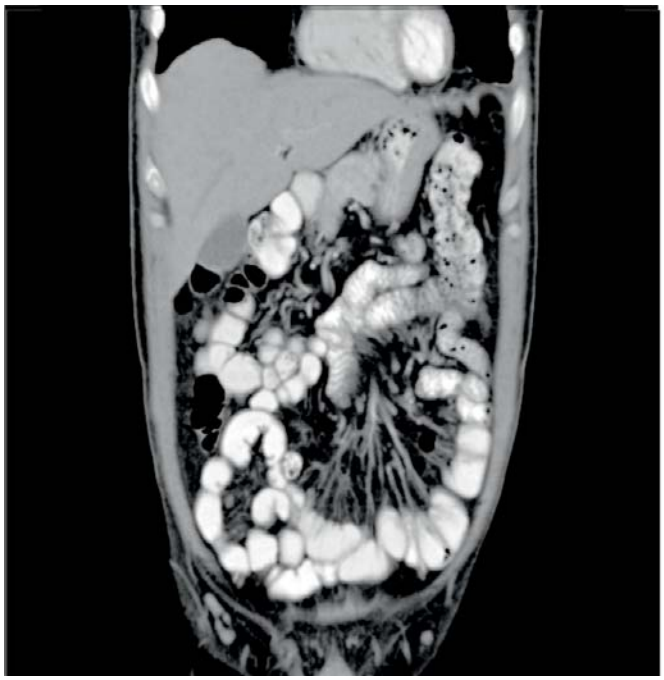

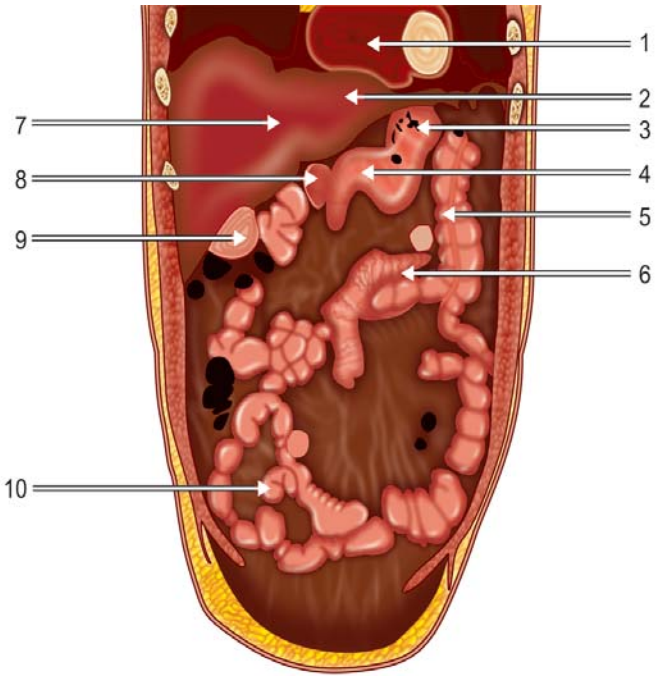

Figure 8.23

1. Heart
2. Liver, left lobe
3. Stomach
4. Pancreas, body
5. Transverse colon
6. Jejunal loops
7. Liver, right lobe
8. Duodenum
9. Gallbladder
10. Ileal loops

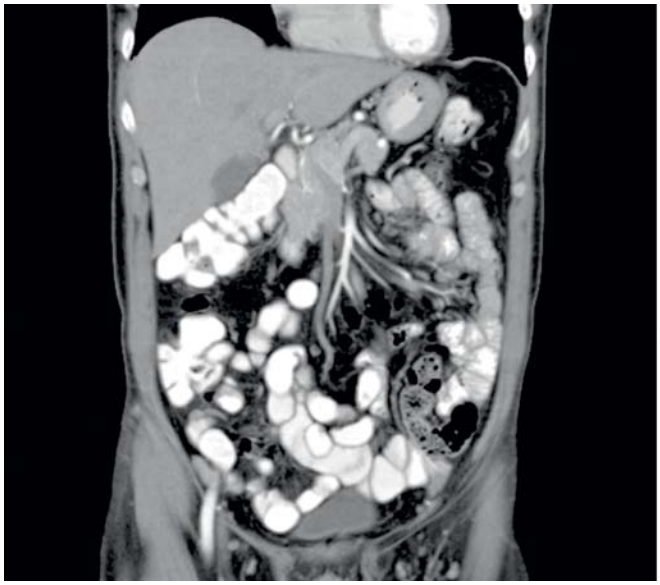

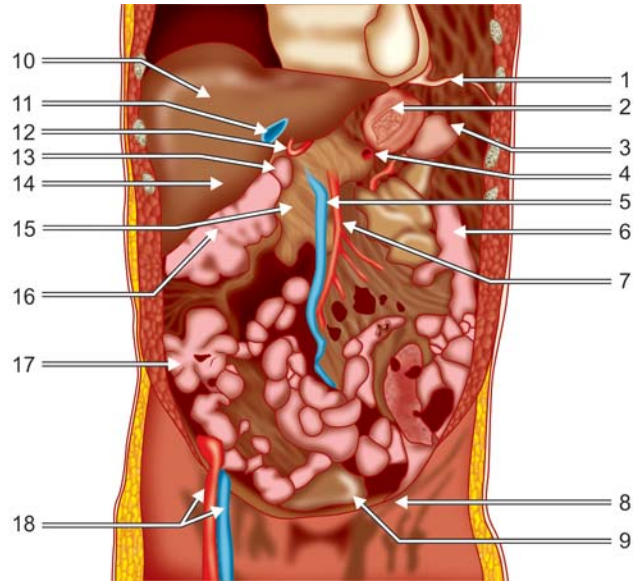

Figure 8.24

1. Diaphragm
2. Stomach
3. Splenic flexure
4. Splenic artery
5. SMV
6. Jejunal loops
7. SMA
8. Inguinal ligament
9. Urinary bladder
10. Liver
11. Portal vein
12. Hepatic artery
13. Duodenum
14. Gallbladder
15. Pancreas, head
16. Hepatic flexure
17. Caecum
18. Femoral vessels



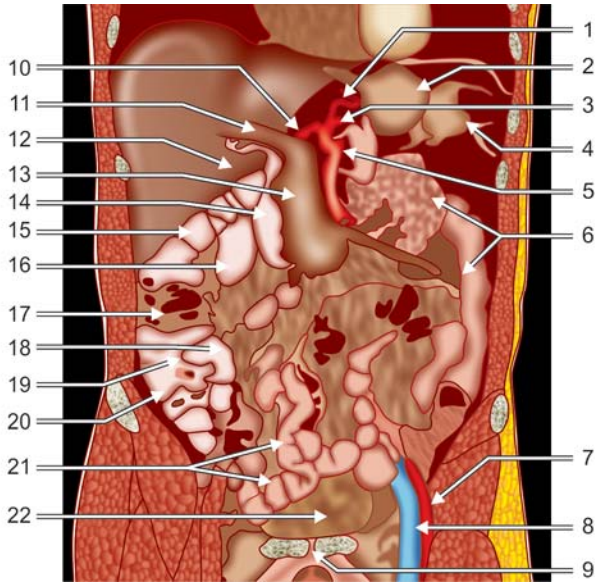

Figure 8.25

1. Left gastric artery
2. Stomach, fundus
3. Splenic artery
4. Splenic flexure
5. Coeliac artery
6. Jejunal loops
7. Femoral artery
8. Femoral vein
9. Pubic symphysis
10. Hepatic artery
11. Portal vein
12. Gallbladder
13. Pancreas
14. Duodenum
15. Hepatic flexure
16. Right kidney
17. Ascending colon
18. Terminal ileum
19. Ileocecal valve
20. Caecum
21. Ileal loops
22. Urinary bladder



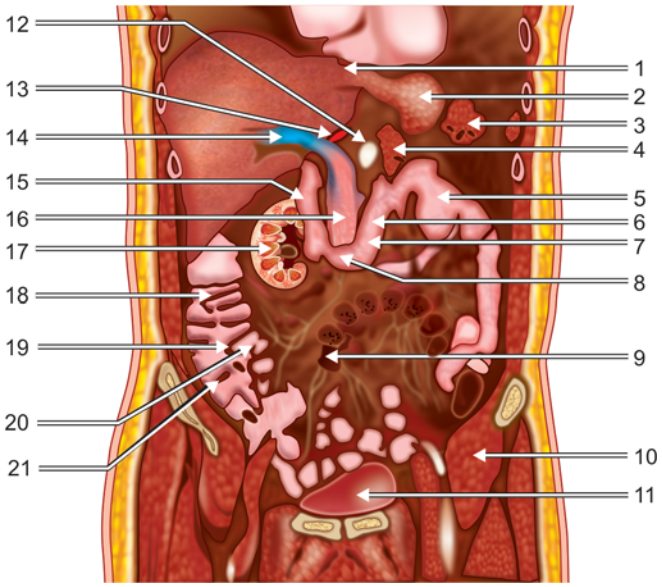

Figure 8.26

1. Gastroesophageal junction
2. Stomach
3. Splenic flexure
4. Pancreas, body
5. Jejunal loops
6. Duodeno-jejunal flexure
7. Duodenum, D4
8. Duodenum, D3
9. Iliocolic artery
10. Iliopsoas
11. Urinary bladder
12. Celiac
13. Hepatic artery
14. Portal vein
15. Duodenum, D2
16. Pancreas, head
17. Right kidney
18. Ascending colon
19. IC valve
20. Terminal ileum
21. Caecum



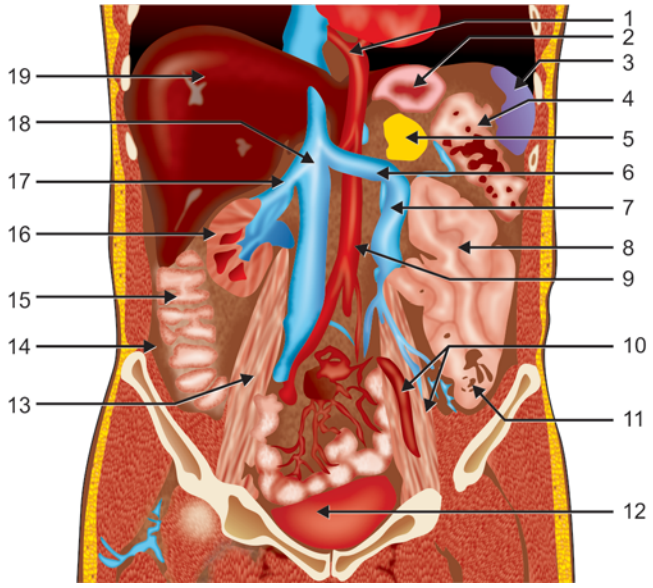

Figure 8.27

1. Esophagus
2. Stomach
3. Spleen
4. Splenic flexure
5. Pancreas
6. Left renal vein
7. Inferior mesenteric vein
8. Jejunal loops
9. Aorta
10. External iliac vessels
11. Descending colon
12. Urinary bladder
13. Psoas
14. Paracolic gutter
15. Ascending colon
16. Right kidney
17. Right renal vein
18. IVC
19. Liver

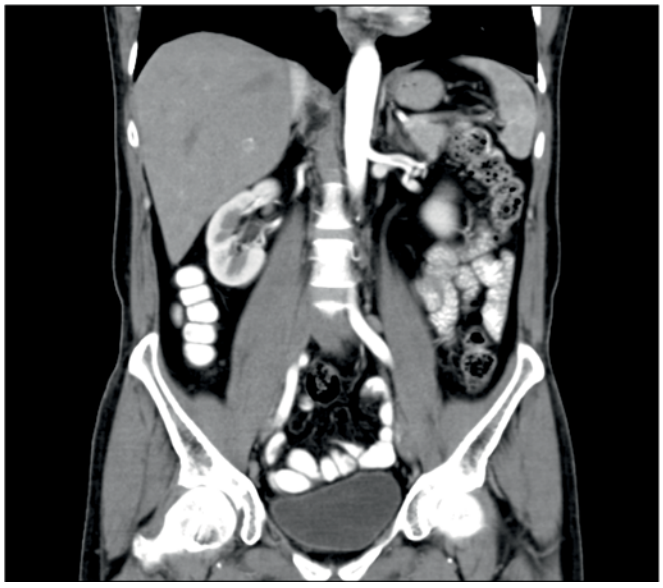

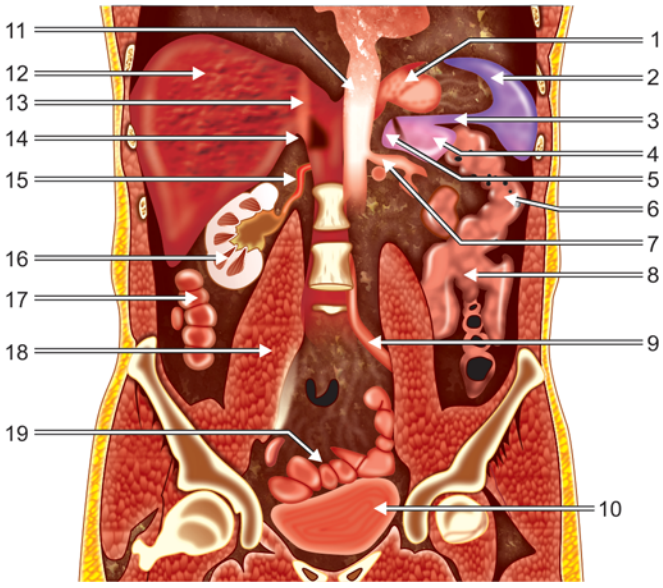

Figure 8.28

1. Stomach
2. Spleen
3. Splenic vein
4. Pancreas, tail
5. Left adrenal gland
6. Descending colon
7. Left renal artery
8. Jejunal loops
9. Left common iliac artery
10. Urinary bladder
11. Aorta
12. Liver
13. IVC
14. Right adrenal gland
15. Right renal artery
16. Right kidney
17. Ascending colon
18. Psoas
19. Ileal loops

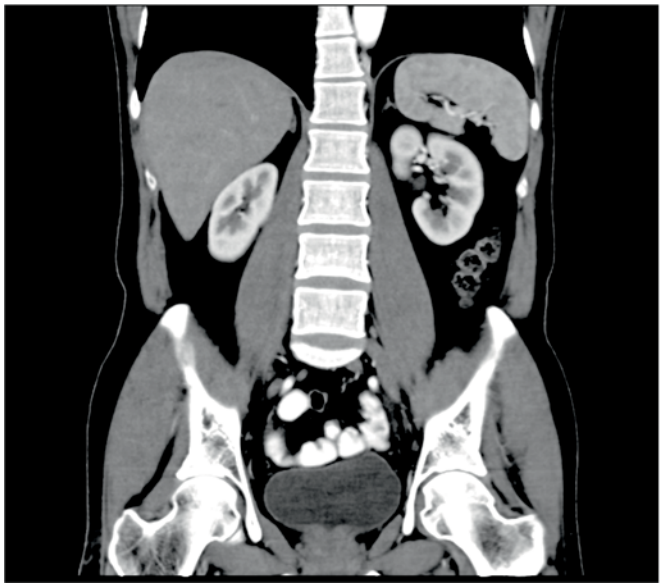

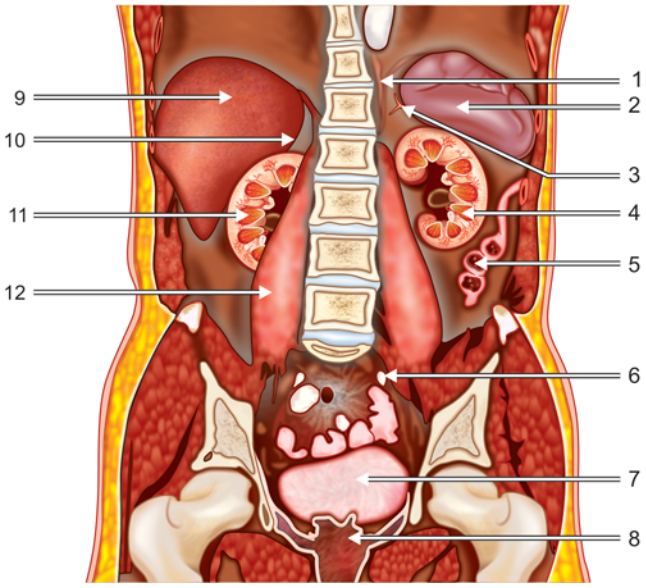

Figure 8.29

1. Crus, diaphragm
2. Spleen
3. Left adrenal gland
4. Left kidney
5. Descending colon
6. Internal iliac artery
7. Urinary bladder
8. Prostate
9. Liver
10. Right adrenal gland
11. Right kidney
12. Psoas



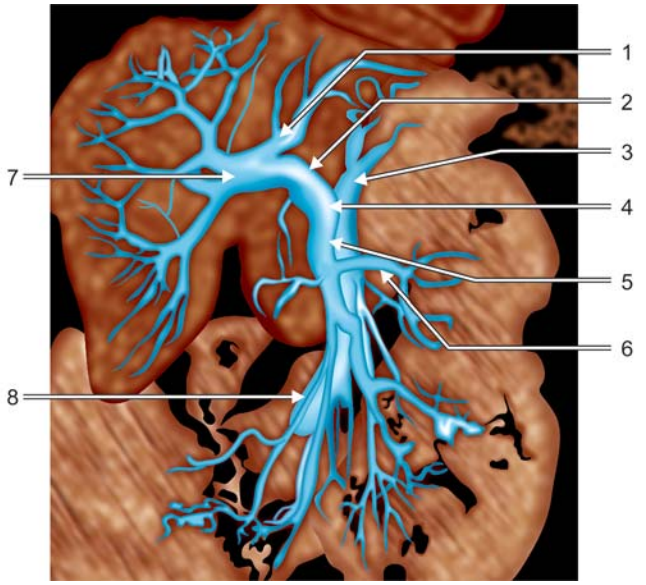

Figure 8.30

1. Left portal vein
2. Portal vein
3. Splenic vein
4. Portal confluence
5. Superior mesenteric vein
6. Jejunal vein
7. Right portal vein
8. Ileocolic veins



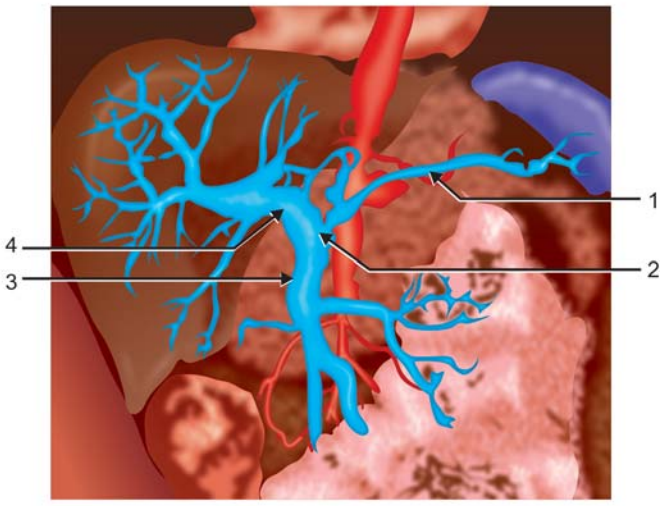

Figure 8.31

1. Splenic vein
2. Portal confluence
3. Portal vein
4. Superior mesenteric vein

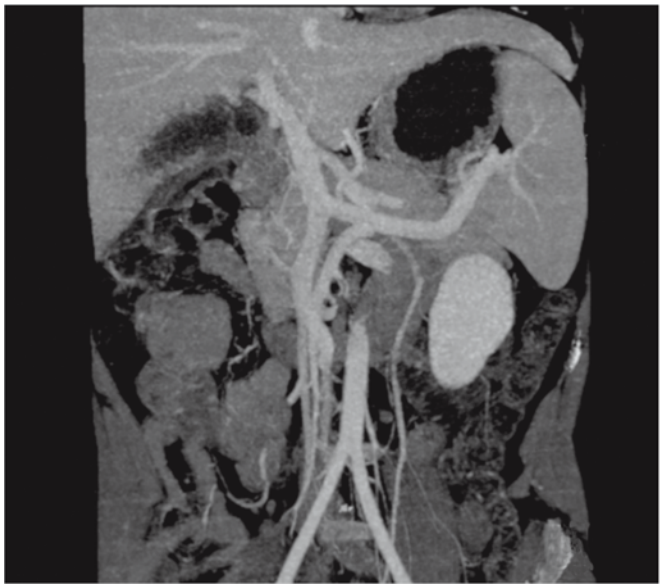

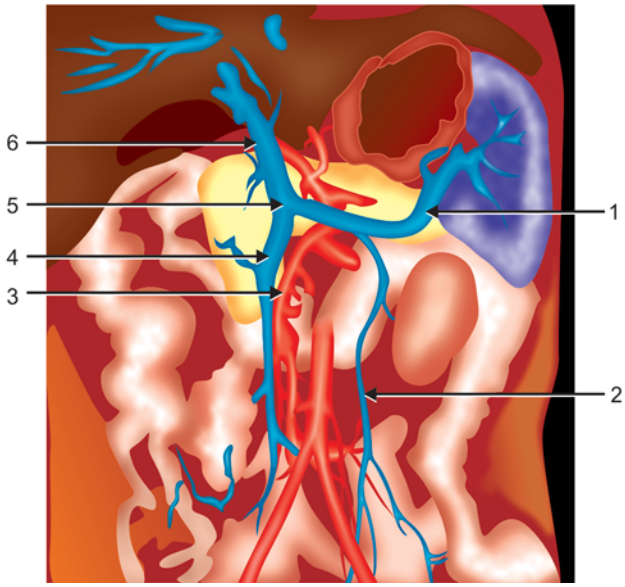

Figure 8.32

1. Splenic vein
2. Inferior mesenteric vein
3. Portal vein
4. Portal confluence
5. Superior mesenteric vein
6. Superior mesenteric artery

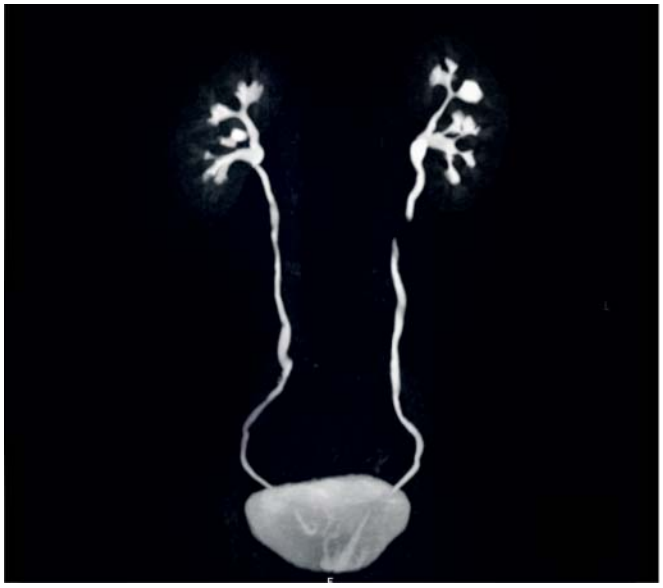

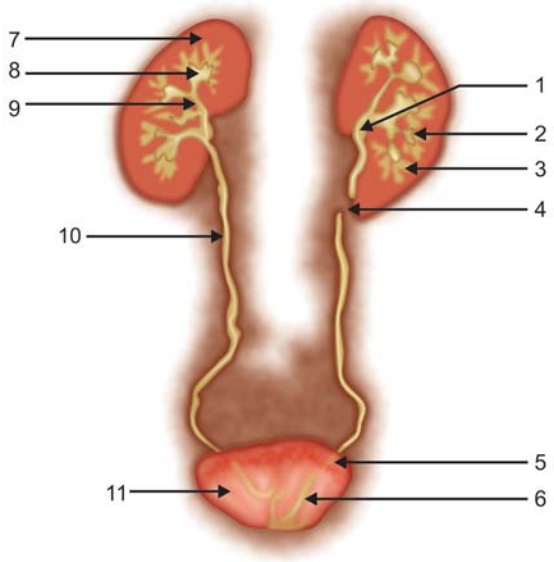

Figure 8.33

1. Renal pelvis
2. Papilla
3. Pyramid
4. Vascular impression
5. UV junction
6. Ureteric jet
7. Renal cortex
8. Minor calyx
9. Major calyx
10. Ureter
11. Urinary bladder

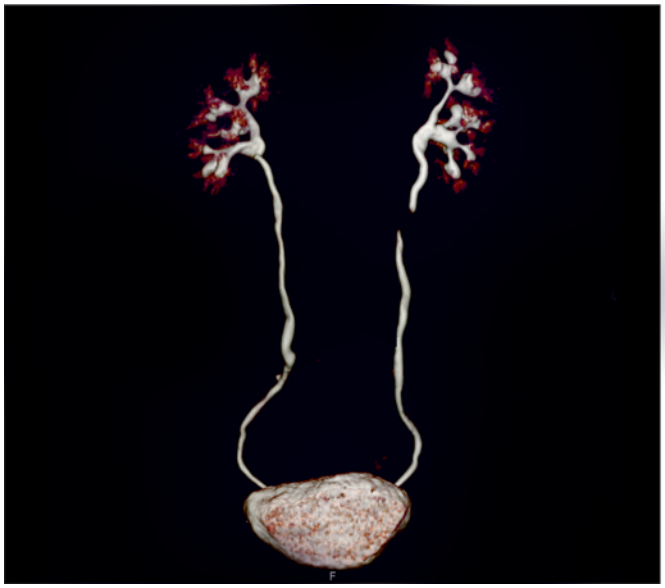

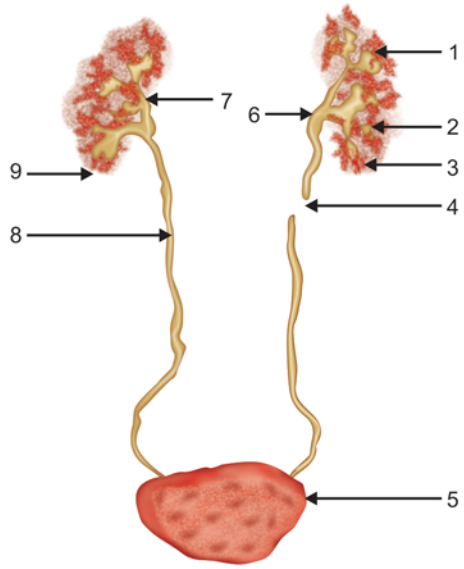

Figure 8.34

1. Papilla
2. Minor calyx
3. Medullary pyramid
4. Vascular impression
5. Urinary bladder
6. Pelvis
7. Major calyx
8. Renal cortex
9. Ureter

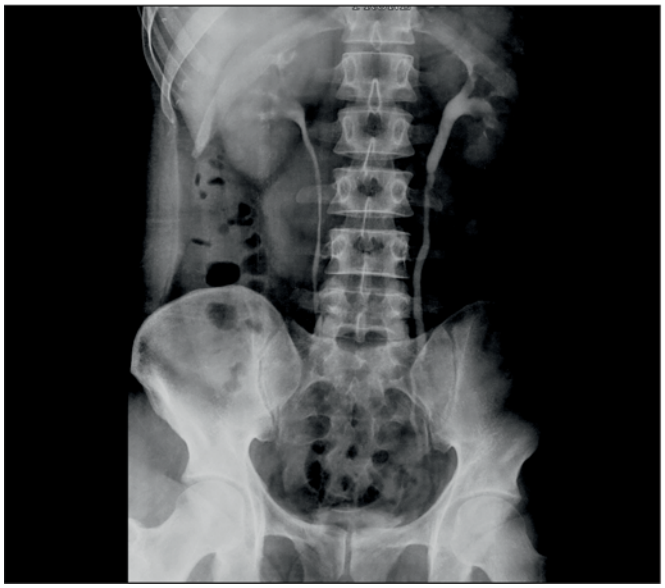

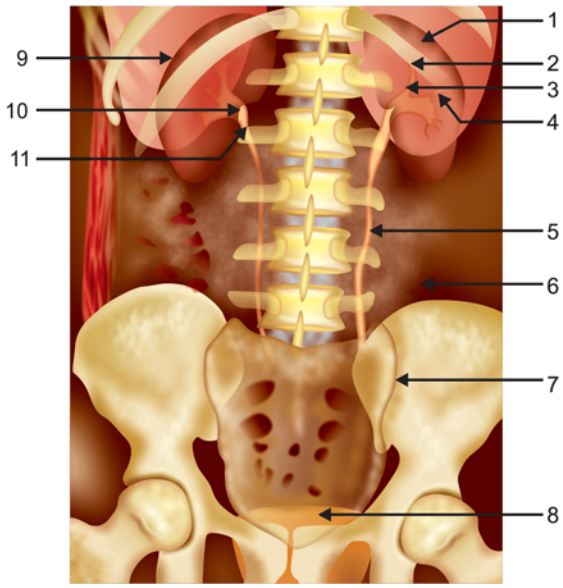

Figure 8.35

Intravenous Urogram (IVU)

1. Left kidney
2. Minor calyx
3. Major calyx
4. Papilla
5. Ureter
6. Psoas shadow
7. Sacroiliac joint
8. Bladder
9. Right kidney
10. Pelvis
11. Pelviureteric junction

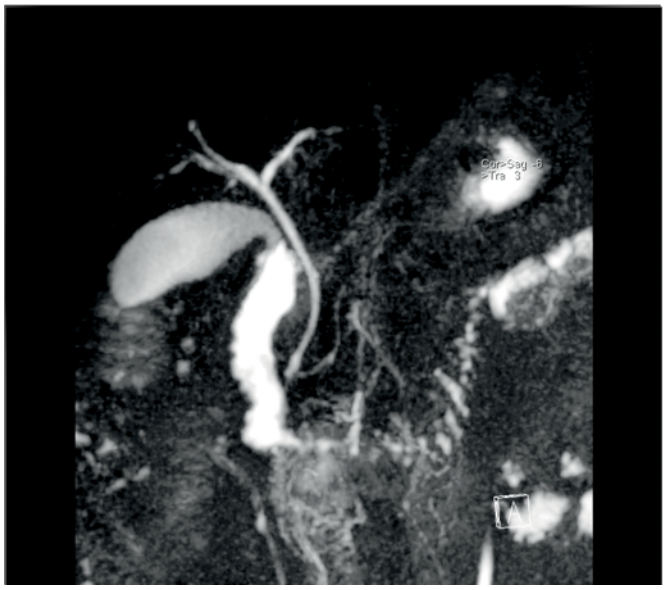

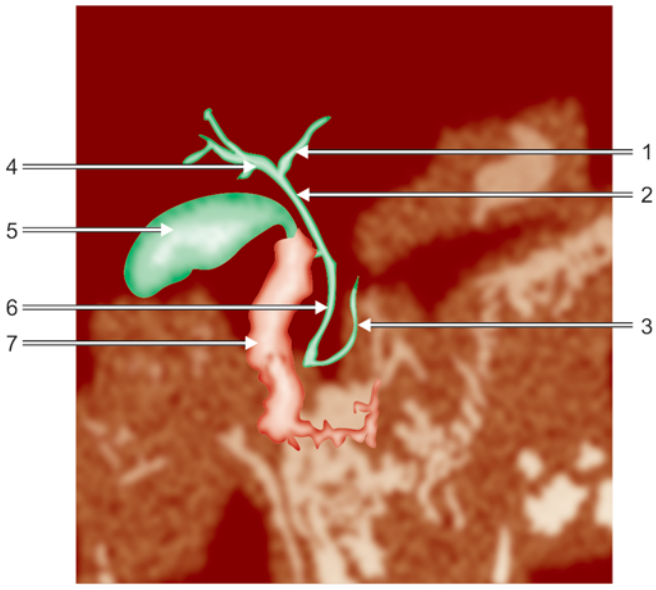

Figure 8.36

MRCP

1. Left hepatic duct
2. Common hepatic duct
3. Pancreatic duct
4. Right hepatic duct
5. Gallbladder
6. Common bile duct
7. Duodenum



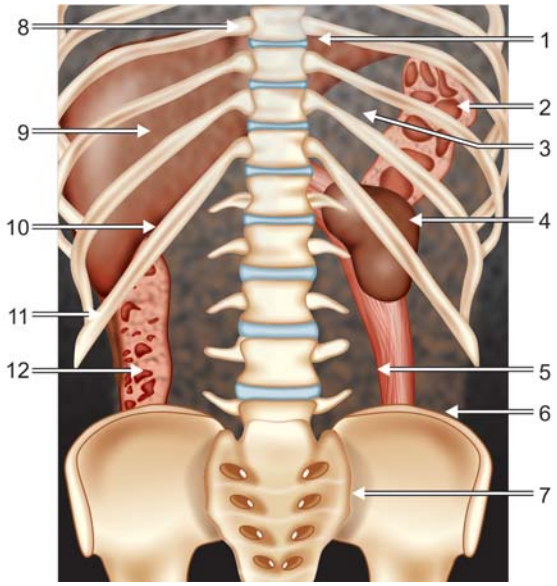

Figure 8.37

1. Descending aorta
2. Splenic flexure
3. Fundic bubble
4. Left kidney
5. Left psoas muscle
6. Iliac crest
7. Left sacroiliac joint
8. IVC
9. Liver
10. Hepatic flexure
11. Fat stripe
12. Ascending colon

CHAPTER 9

Pelvis

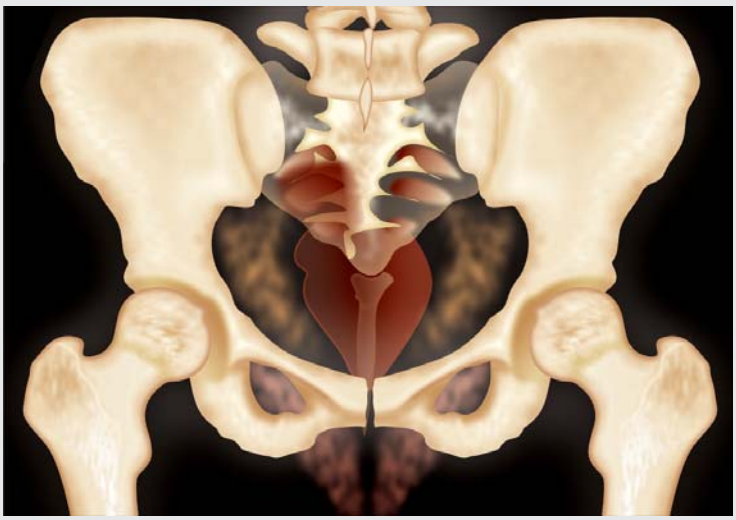

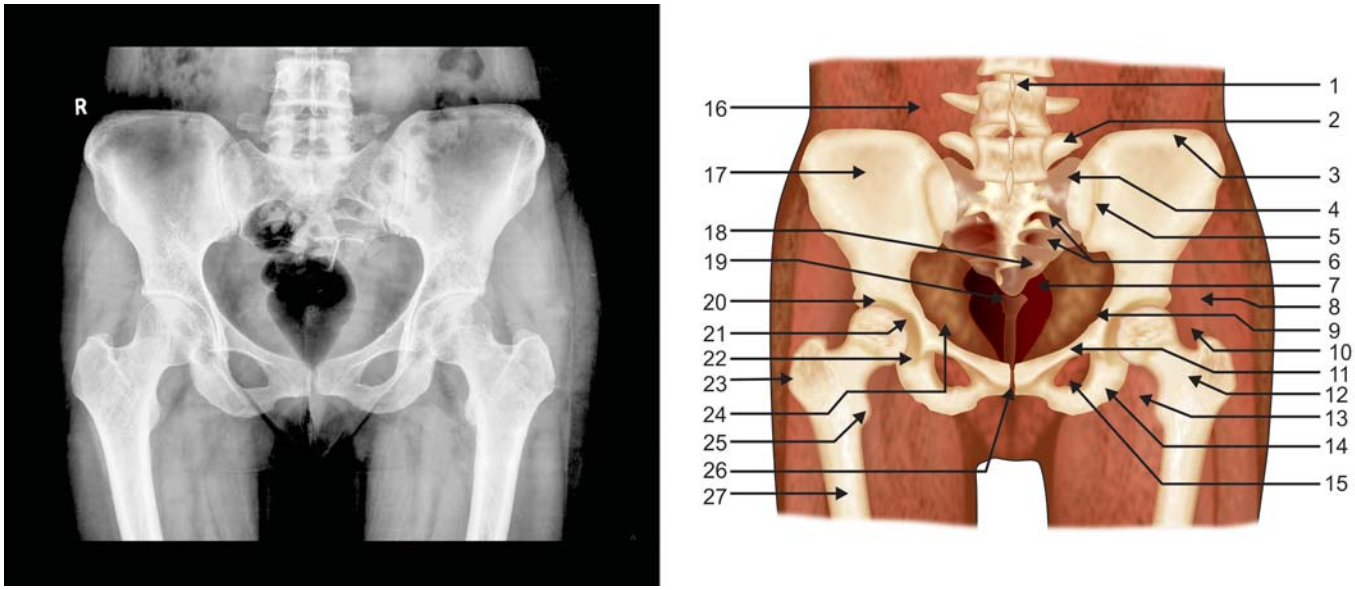

Figure 9.1

1. Spinous process
2. L5 transverse process
3. Iliac crest
4. Sacral ala
5. Sacroiliac joint
6. Sacral foramina
7. Rectal gas shadow
8. Gluteus medius fat plane
9. Ischial spine
10. Supracapsular fat plane
11. Superior pubic ramus
12. Intertrochanteric line
13. Psoas fat plane
14. Ischial tuberosity
15. Obturator foramen
16. Psoas
17. Iliac bone
18. Copper-T
19. Coccyx
20. Superior compartment of hip joint
21. Axial compartment of hip joint
22. Medial compartment of hip joint
23. Greater trochanter
24. Obturator internus fat plane
25. Lesser trochanter
26. Pubic symphysis
27. Femur

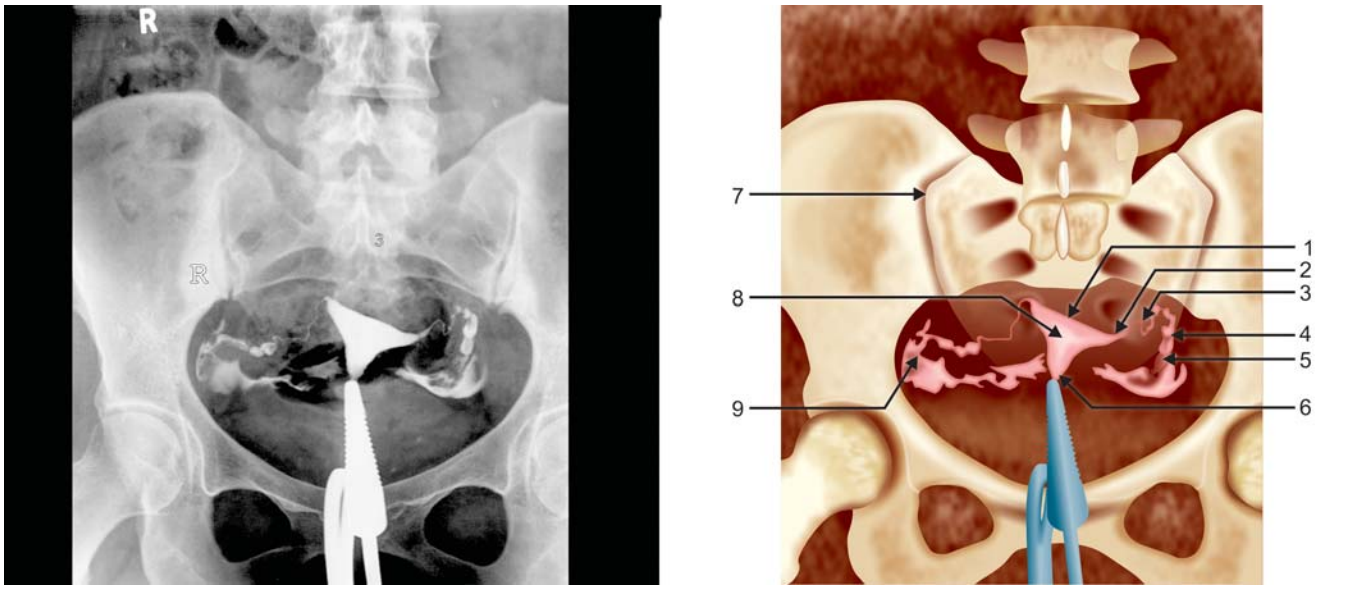

Figure 9.2

1. Fundus of uterus
2. Cornu of uterus
3. Isthmus of fallopian tube
4. Ampullary part
5. Infundibulum
6. Cervix
7. Sacroiliac joint
8. Body of uterus
9. Free spill of contrast in the pelvis

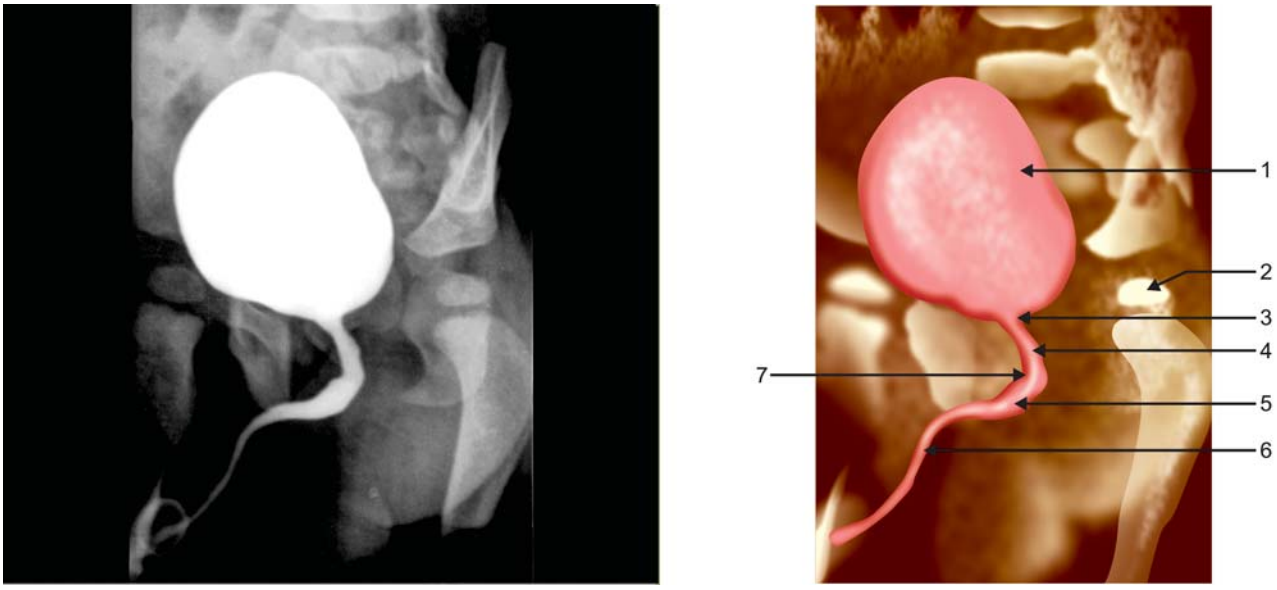

Figure 9.3

1. Urinary bladder
2. Femur head
3. Bladder neck
4. Prostatic urethra
5. Bulbous urethra
6. Penile (anterior) urethra
7. Membranous urethra

FEMALE PELVIS

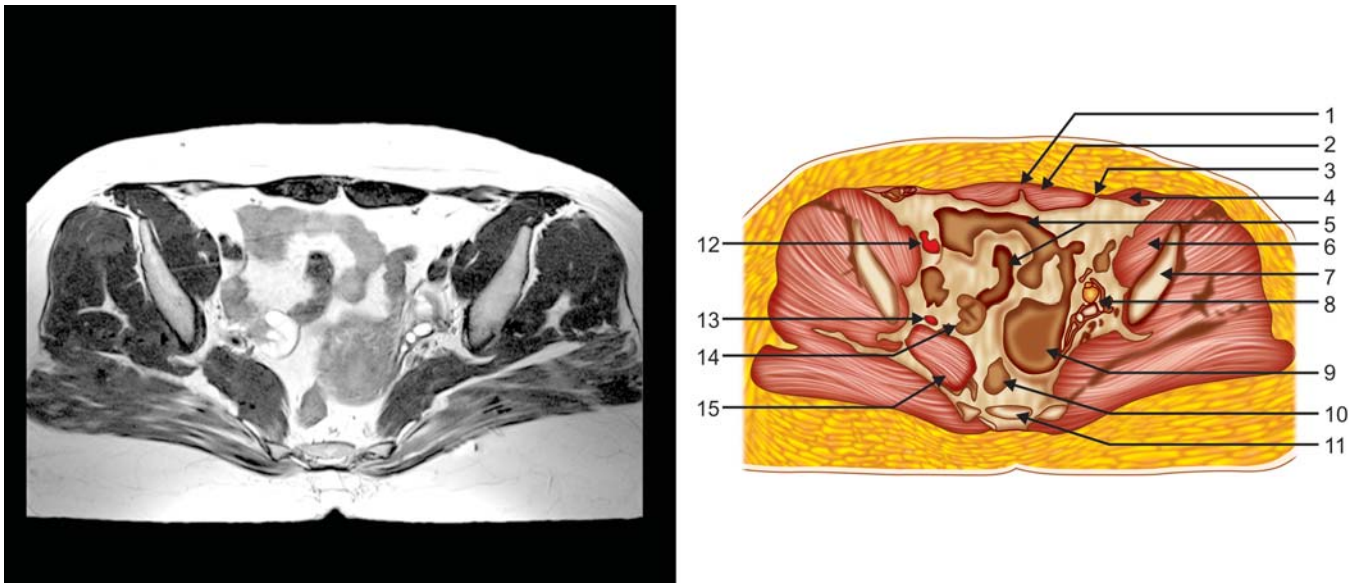

Figure 9.4

1. Linea alba
2. Rectus abdominis muscle
3. Linea semilunaris
4. Oblique muscles
5. Bowel loops
6. Iliopsoas muscle
7. Hip bone
8. Left ovary
9. Uterine fundus
10. Rectosigmoid
11. Sacrum
12. External iliac vessels
13. Internal iliac branches
14. Right ovary with follicles
15. Piriformis

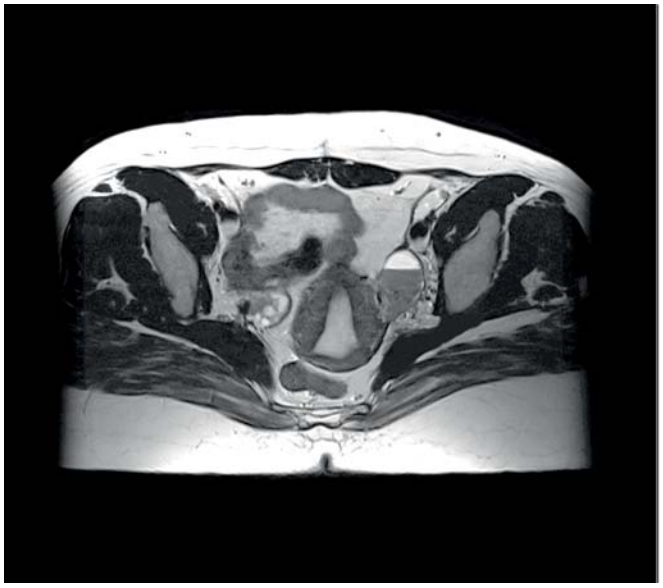

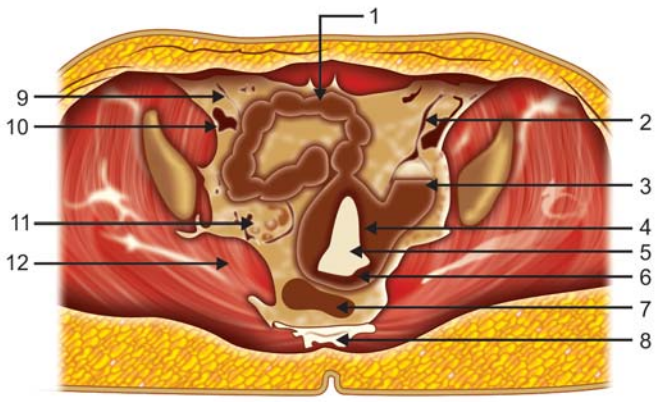

Figure 9.5

1. Bowel loops
2. Round ligament
3. Left ovarian cyst with fluid level
4. Junctional zone
5. Uterine cavity
6. Uterine fundus
7. Rectum
8. Sacrum
9. Right round ligament
10. External iliac vessels
11. Right ovary
12. Piriformis

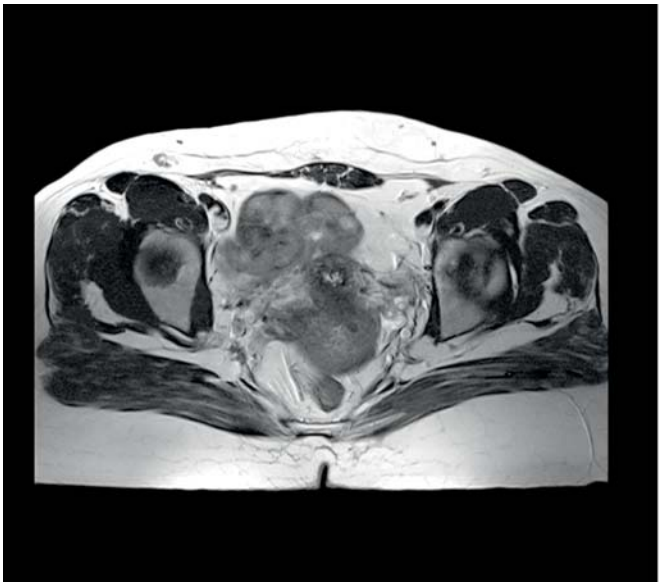

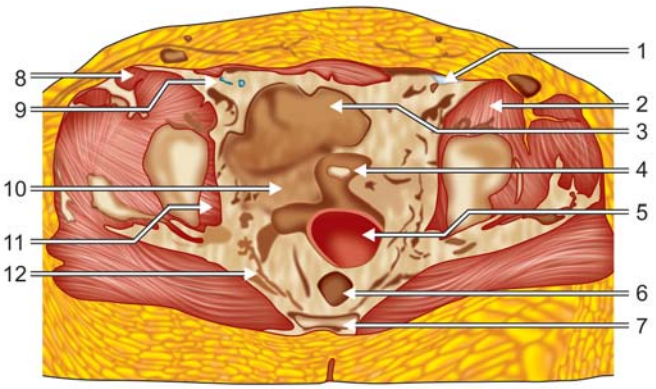

Figure 9.6

1. Round ligament
2. Iliopsoas
3. Bowel loops
4. Cervix
5. Uterus
6. Rectum
7. Sacrum
8. Sartorius
9. Round ligament
10. Parametrium
11. Obturator internus
12. Uterosacral ligament



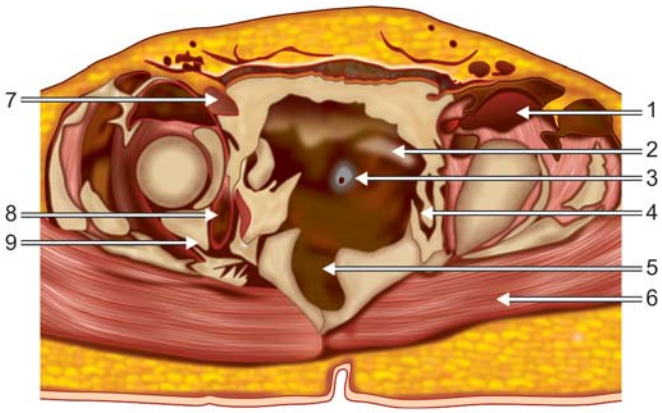

Figure 9.7

1. Iliopsoas
2. Urinary bladder
3. Cervical canal
4. Venous plexus
5. Rectum
6. Gluteus maximus
7. External iliac vessels
8. Obturator internus
9. Ischium

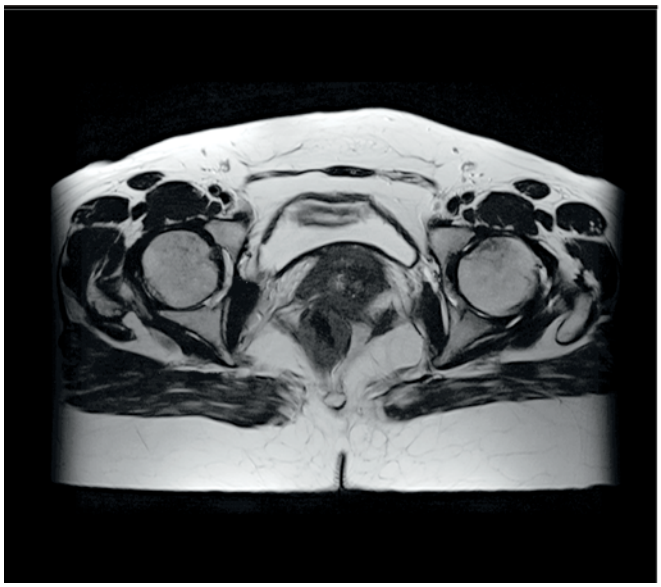

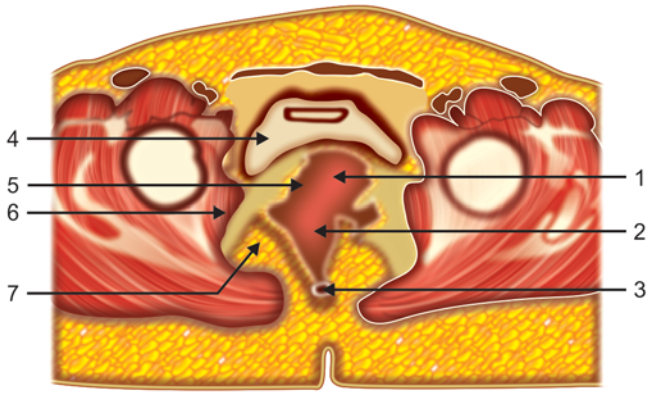

Figure 9.8

1. External OS, cervix
2. Rectum
3. Coccyx
4. Urinary bladder
5. Vaginal fornix
6. Obturator internus
7. Levator ani muscle

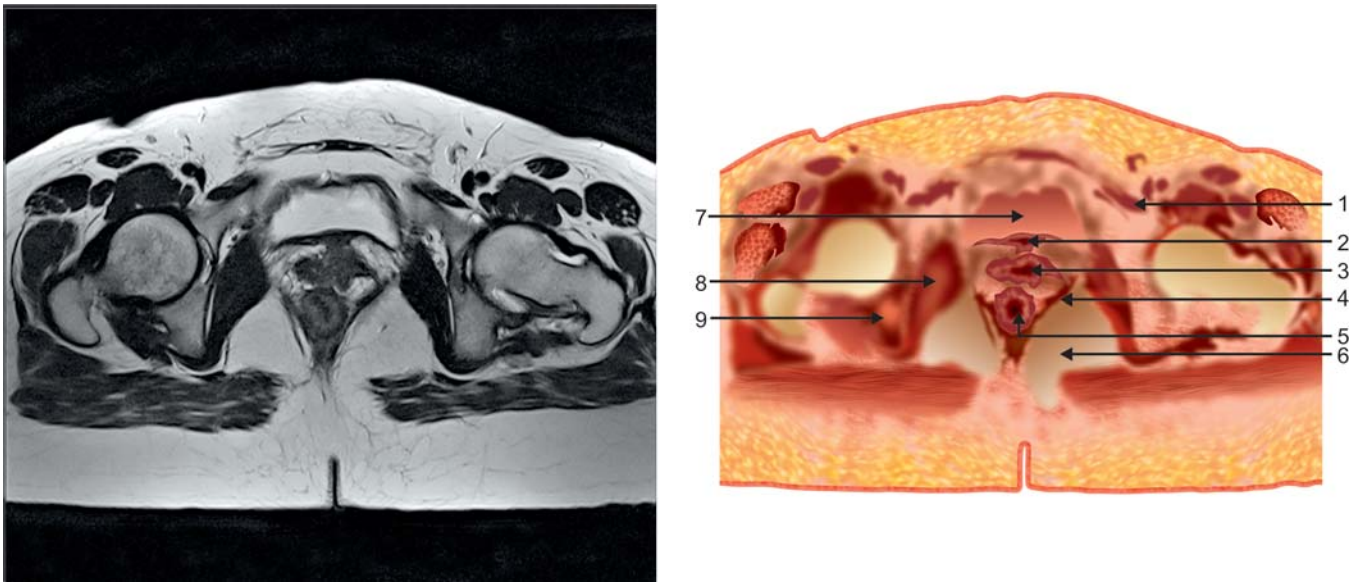

Figure 9.9

1. Pectineus muscle
2. Urethra
3. Vagina, fornix
4. Levator ani muscle
5. Anal canal
6. Ischioanal fossa
7. Urinary bladder
8. Obturator internus
9. Ischium

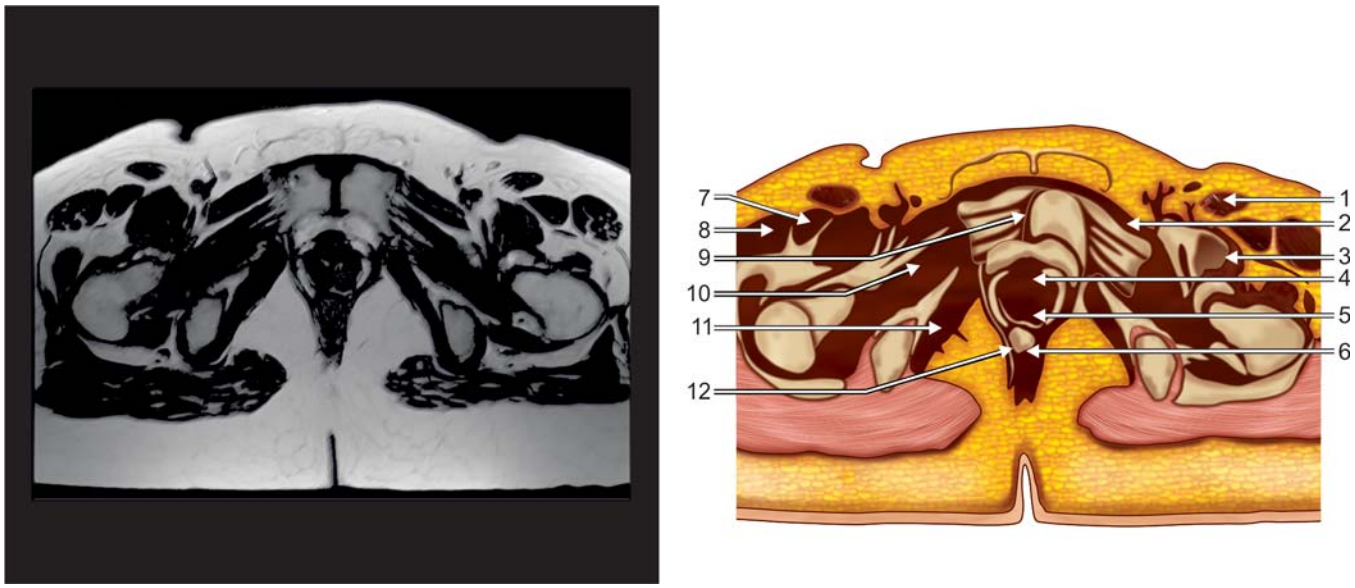

Figure 9.10

1. Sartorius
2. Pectineus muscle
3. Iliopsoas
4. Urethra
5. Vagina
6. Anal canal
7. Rectus femoris muscle
8. Tensor fascia lata muscle
9. Pubic symphysis
10. Obturator externus
11. Obturator internus
12. Levator ani

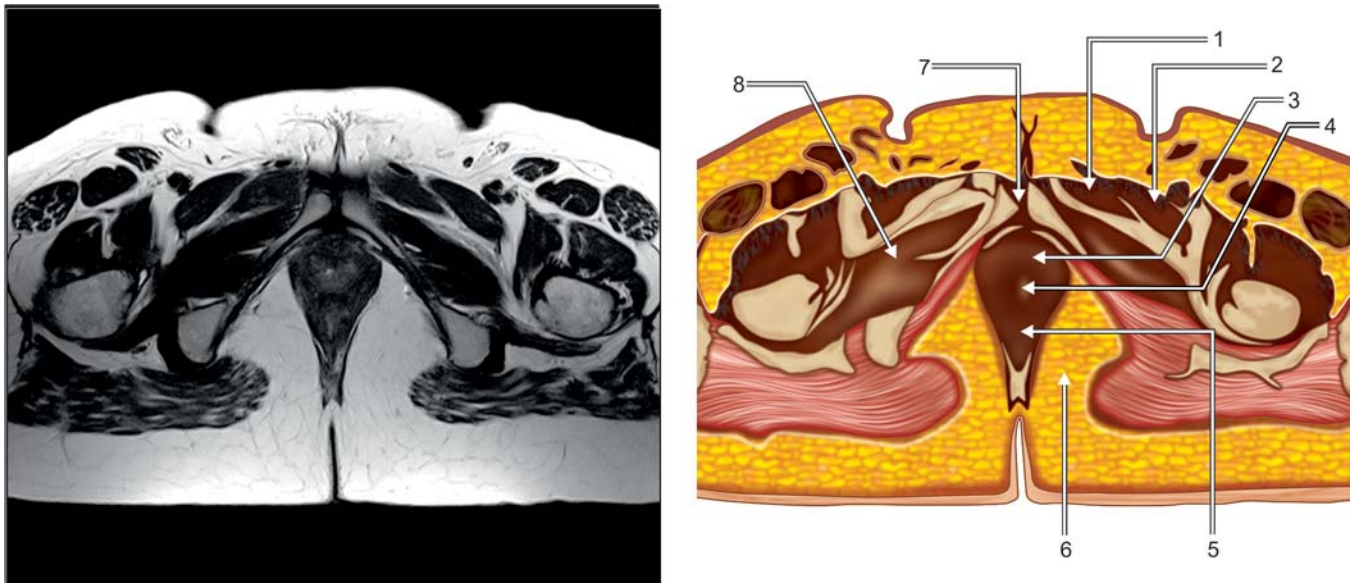

Figure 9.11

1. Adductor brevis
2. Pectineus
3. Urethra
4. Vagina
5. Anus
6. Ischioanal fossa
7. Pubic symphysis
8. Obturator externus

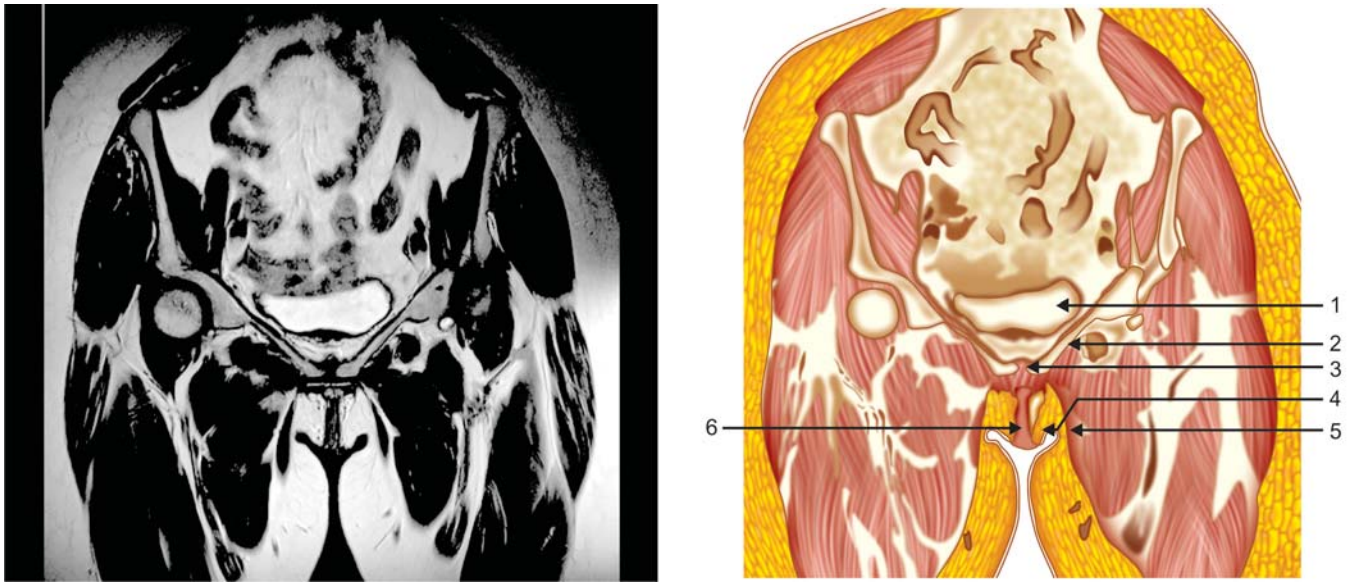

Figure 9.12

1. Urinary bladder
2. Superior pubic ramus
3. Pubic symphysis
4. Labium majora
5. Gracilis muscle
6. Clitoris

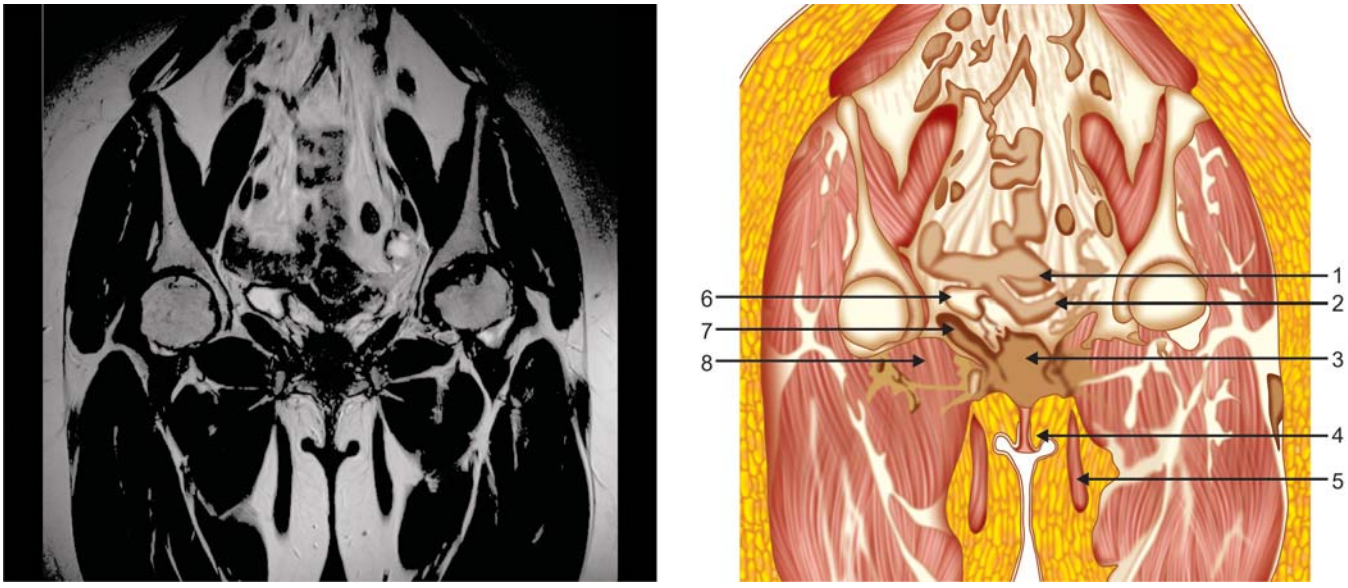

Figure 9.13

1. Part of uterus
2. Vagina, fornix
3. Urethra
4. Labium majora
5. Gracilis
6. Urinary bladder
7. Obturator internus
8. Obturator externus

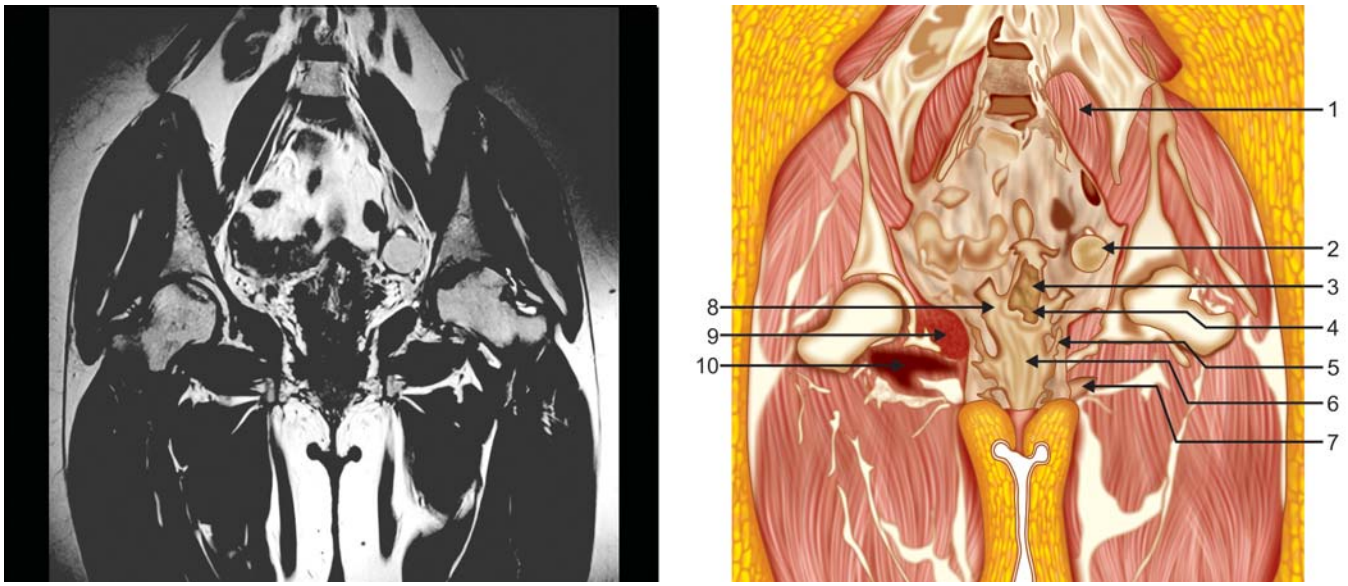

Figure 9.14

1. Psoas
2. Cyst in left ovary
3. Cervical canal
4. External os
5. Levator ani muscle
6. Vagina
7. Ischiopubic ramus
8. Vaginal fornix
9. Obturator internus
10. Obturator externus

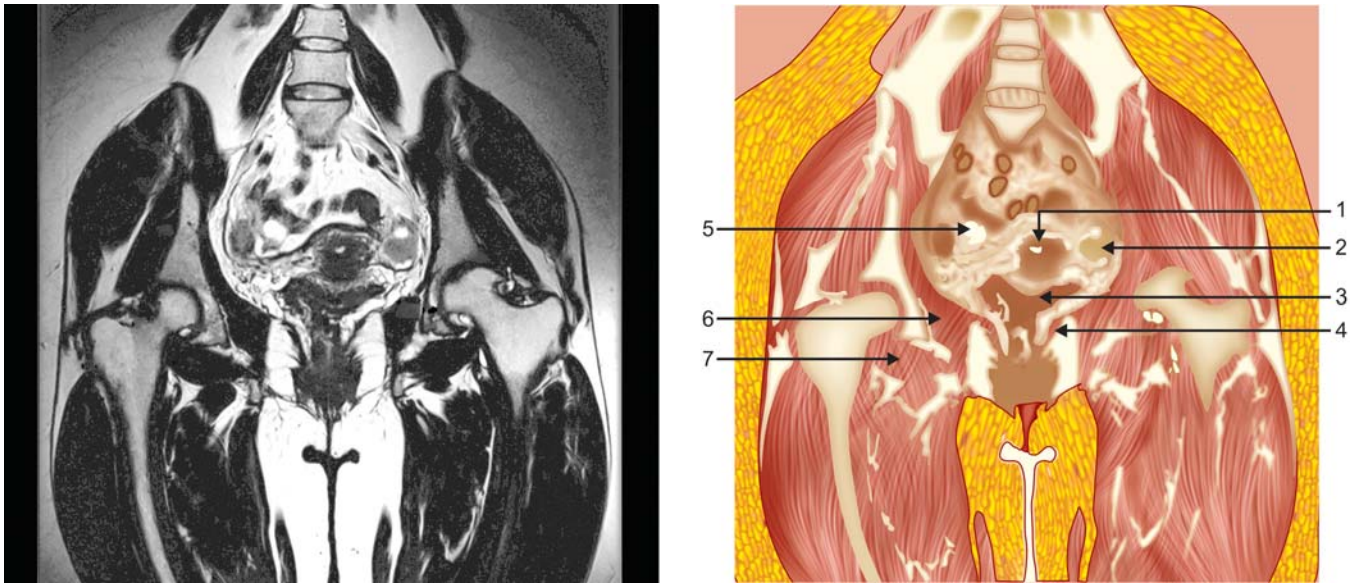

Figure 9.15

1. Uterus
2. Left ovary
3. Posterior fornix, vagina
4. Levator ani muscle
5. Right ovary
6. Obturator internus
7. Obturator externus

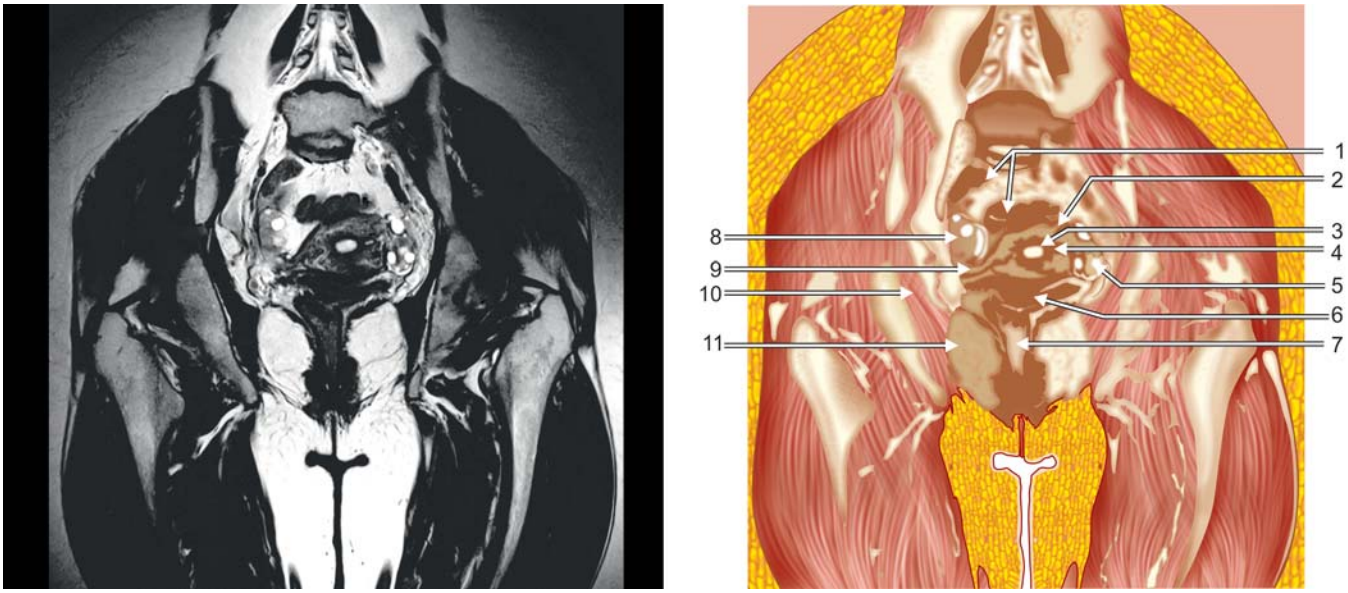

Figure 9.16

1. Bowel loops
2. Uterus
3. Endometrial cavity
4. Junctional zone
5. Left ovary
6. Posterior fornix, vagina
7. Anal canal
8. Right ovary
9. Fallopian tube
10. Obturator internus
11. Ischioanal fossa

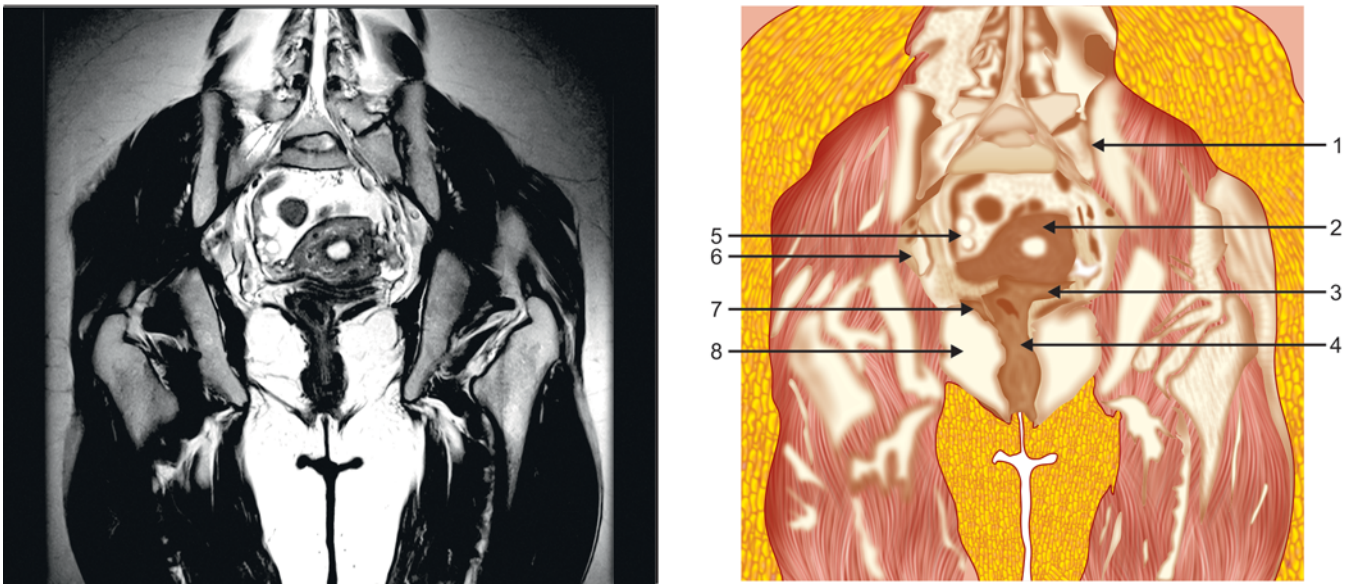

Figure 9.17

1. SI joint
2. Uterus
3. Posterior fornix, vagina
4. Anal canal
5. Right ovary
6. Sciatic nerve
7. Levator ani muscle
8. Ischioanal fossa

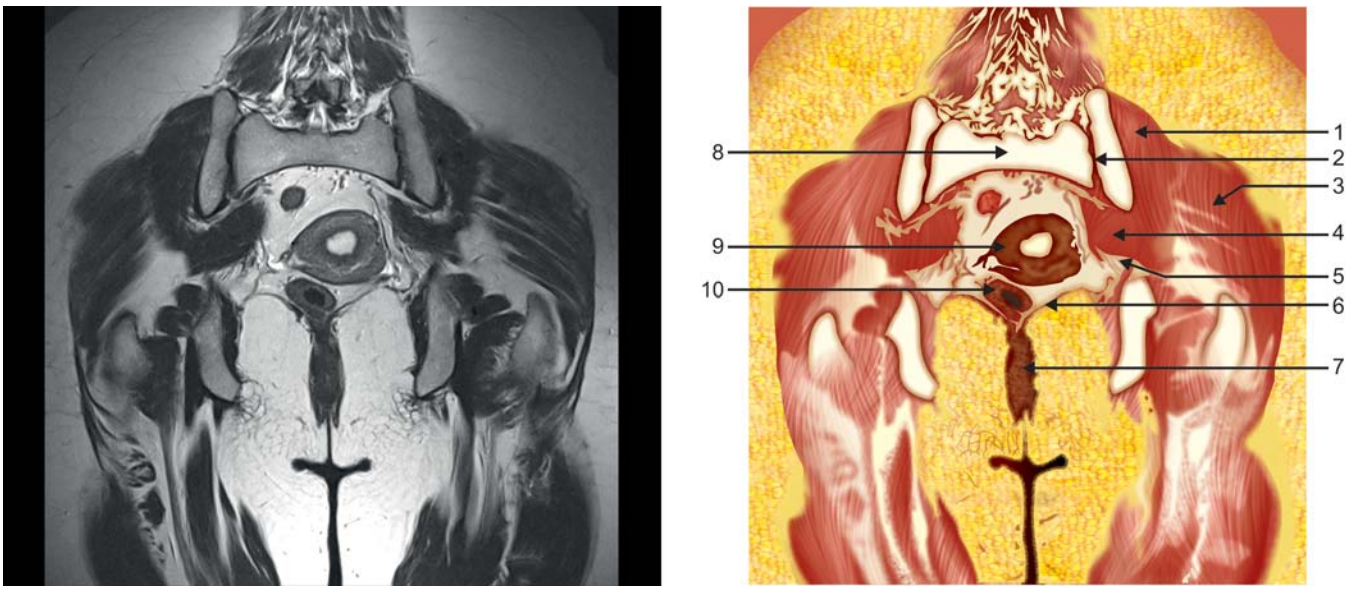

Figure 9.18

1. Gluteus medius
2. SI joint
3. Gluteus maximus
4. Piriformis
5. Sciatic nerve
6. Levator ani muscle
7. Anal canal
8. Sacrum
9. Uterus
10. Rectum

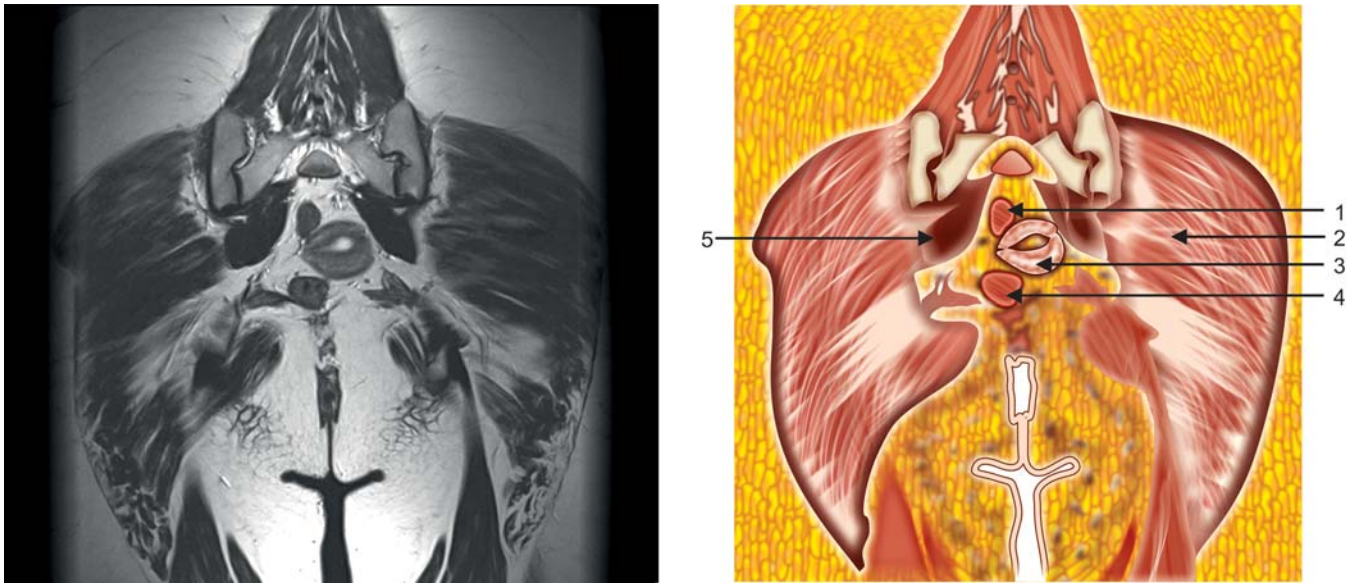

Figure 9.19

1. Rectum
2. Gluteus maximus
3. Uterus, fundus
4. Rectum
5. Piriformis

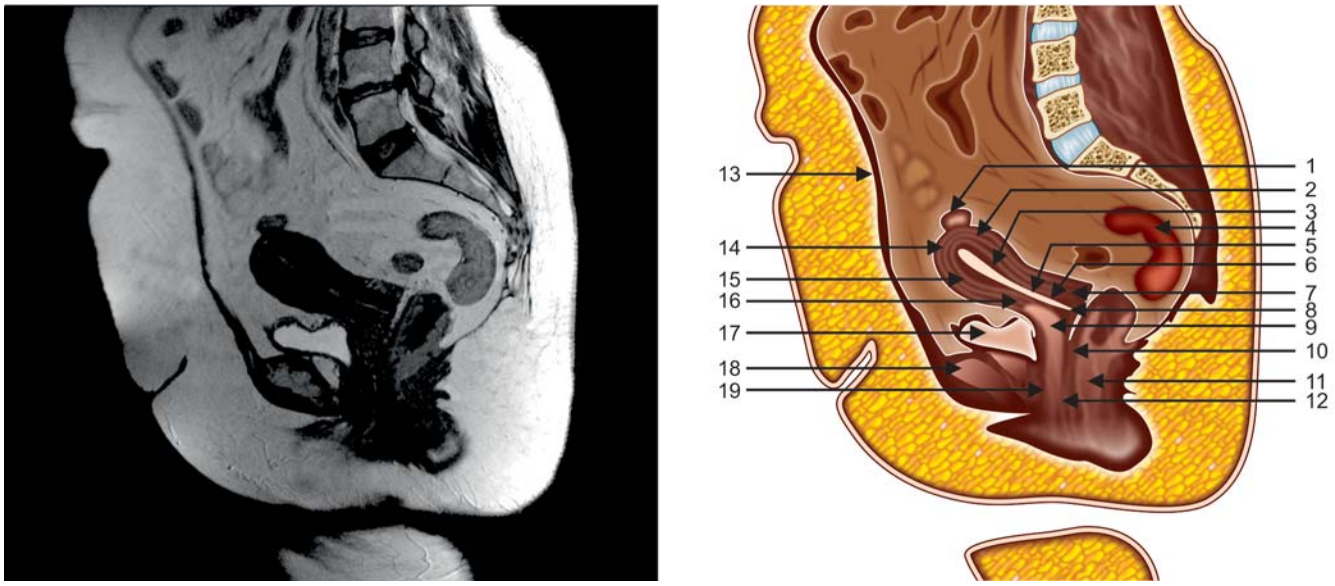

Figure 9.20

1. Bowel loop
2. Myometrium
3. Endometrium
4. Rectum
5. Internal os of cervix
6. Cervical canal
7. Posterior fornix of vagina
8. External os, cervix
9. Anterior fornix, vagina
10. Rectovaginal pouch
11. Anal canal
12. Vagina
13. Rectus abdominis
14. Fundus of uterus
15. Body of uterus
16. Cervix
17. Urinary bladder
18. Pubis bone
19. Urethra



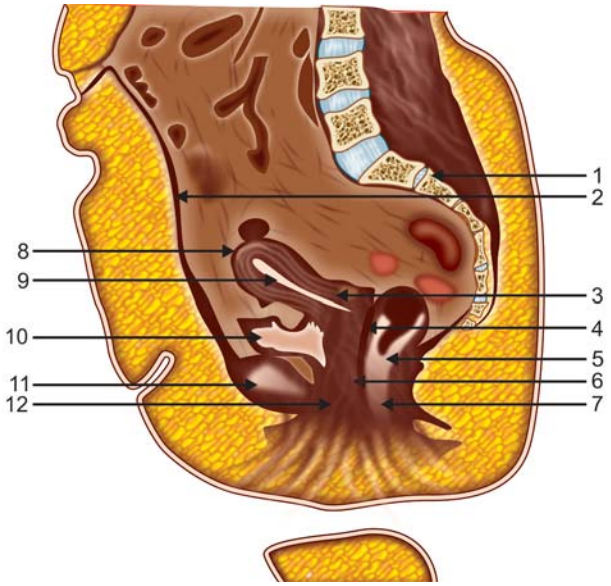

Figure 9.21

1. Sacrum
2. Rectus abdominis muscle
3. Cervix
4. Rectovaginal pouch
5. Rectum
6. Vagina
7. Anal canal
8. Uterus, fundus
9. Uterus, body
10. Urinary bladder
11. Symphysis pubis
12. Urethra

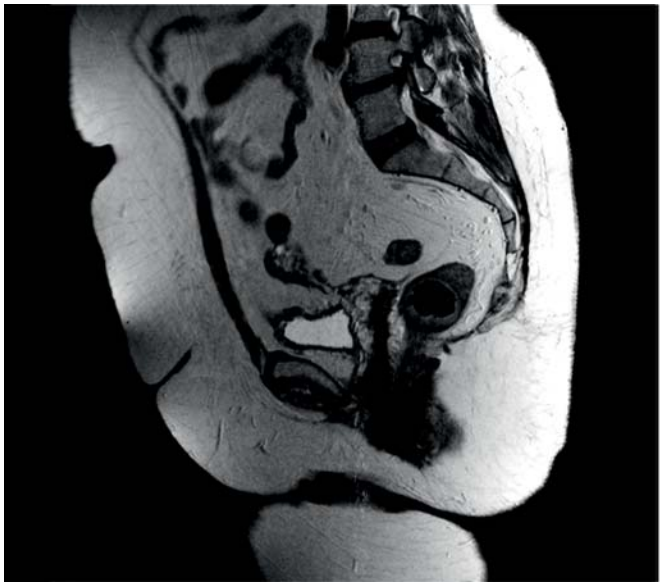

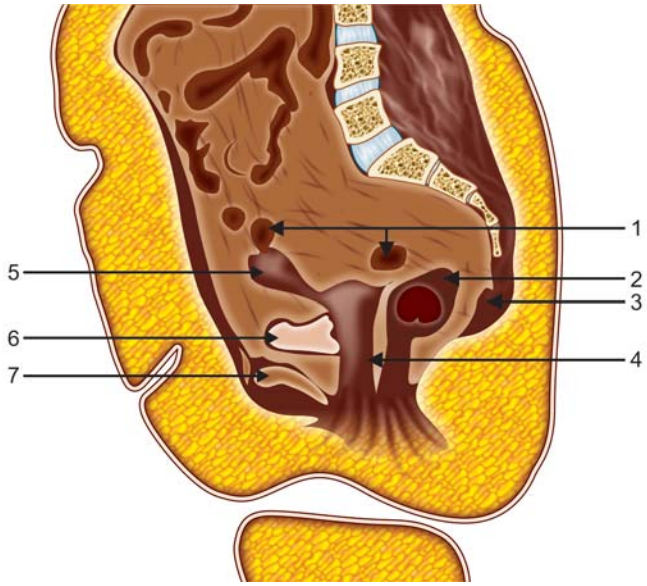

Figure 9.22

1. Bowel loops
2. Rectum
3. Coccyx
4. Vagina, Lateral wall
5. Uterus, cornu
6. Urinary bladder
7. Pubis bone

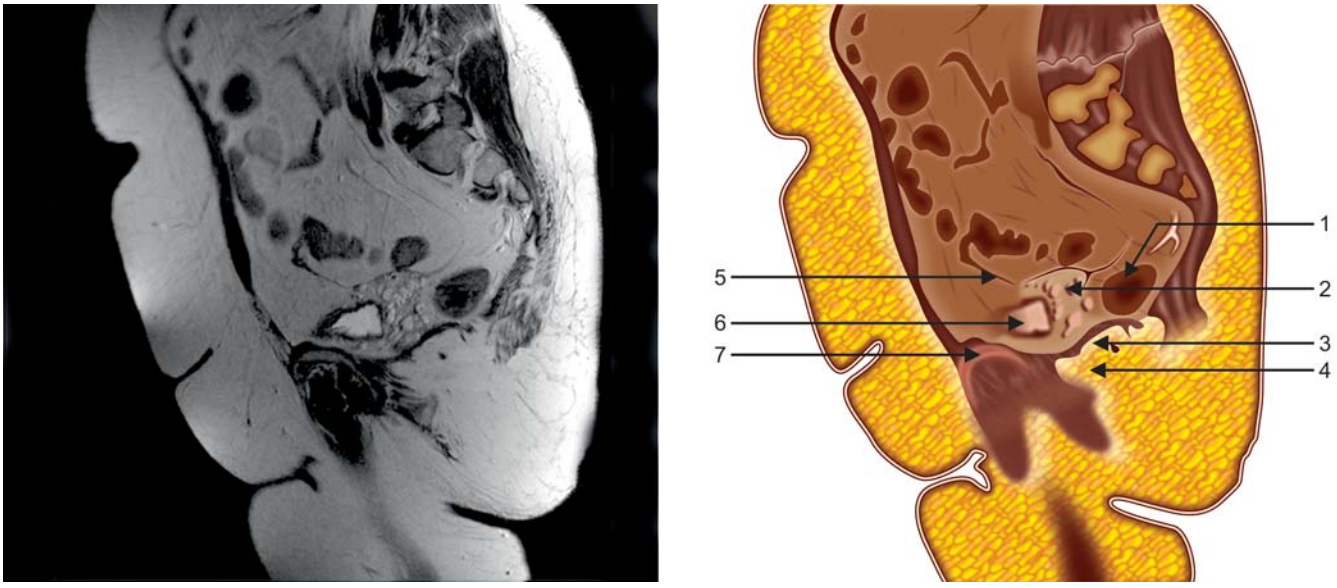

Figure 9.23

1. Rectum
2. Ovary
3. Levator ani muscle
4. Ischioanal fossa
5. Fallopian tube
6. Bladder
7. Pubis

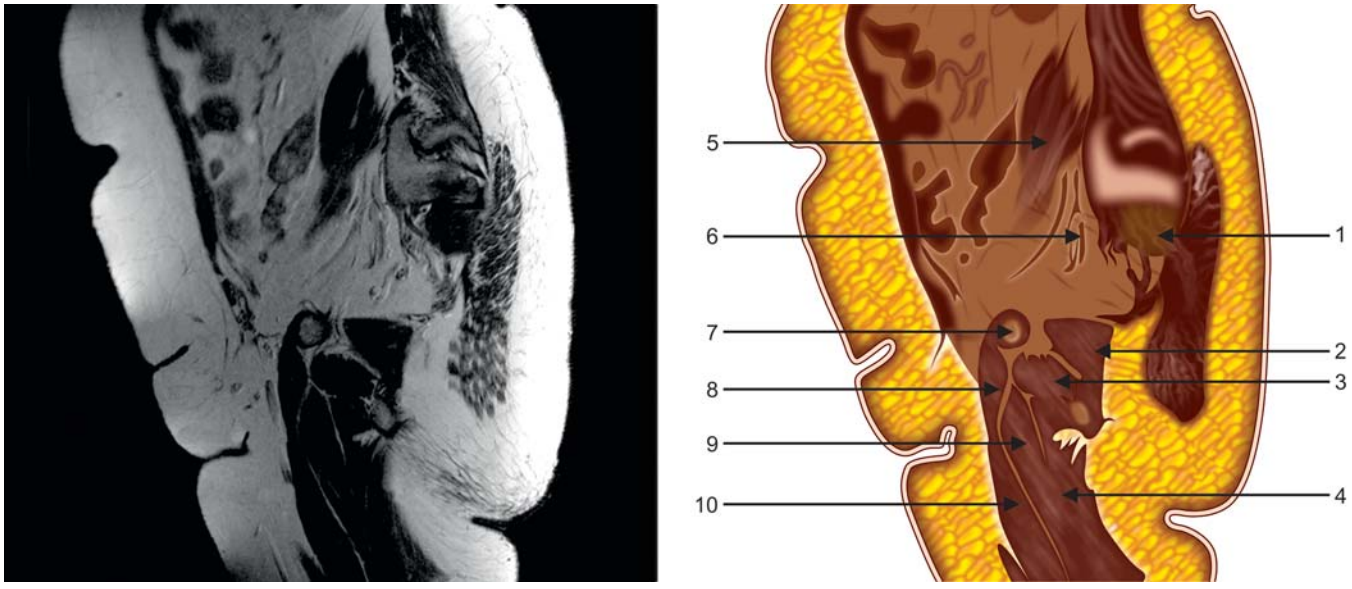

Figure 9.24

1. Piriformis muscle
2. Obturator internus muscle
3. External obturator muscle
4. Adductor magnus
5. Psoas muscle
6. Internal iliac vessels
7. Superior pubic ramus
8. Pectineus muscle
9. Adductor brevis
10. Adductor longus



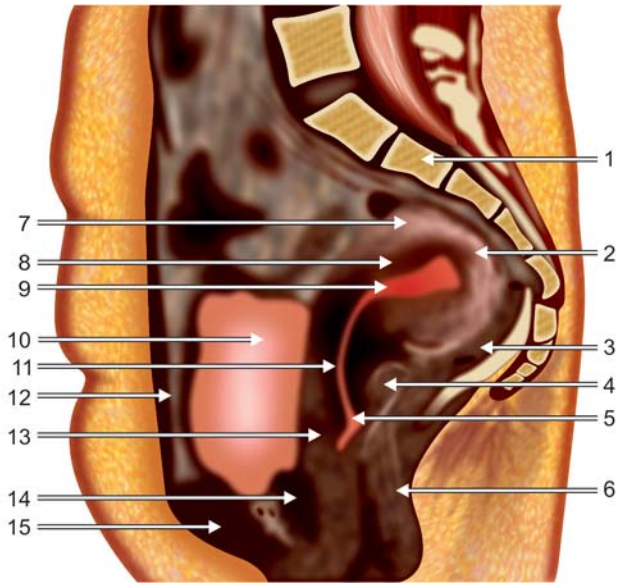

Figure 9.25

TRILAMINAR PATTERN OF UTERUS

1. Sacrum
2. Fundus of uterus
3. Rectum
4. Posterior fornix, vagina
5. External os
6. Anal canal
7. Outer zone: Outer myometrium
8. Junctional zone: Endometrium and inner myometrium
9. Inner zone: Endometrial cavity
10. Urinary bladder
11. Cervix
12. Rectus abdominis
13. Anterior fornix, vagina
14. Urethra
15. Pubic symphysis

MALE PELVIS

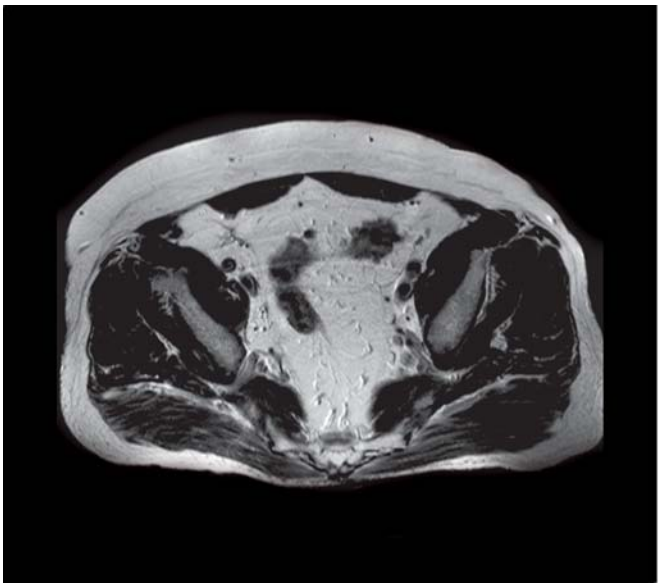

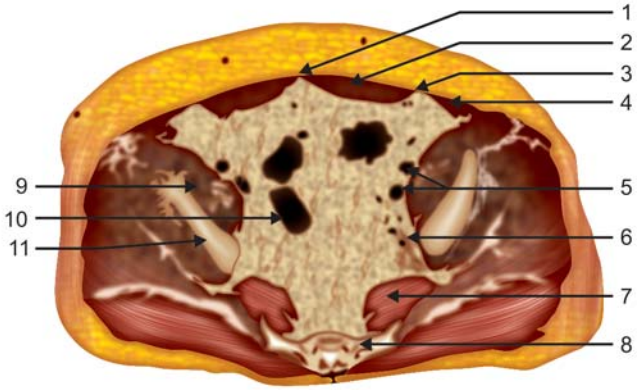

Figure 9.26

1. Linea alba
2. Rectus abdominis muscle
3. Linea semilunaris
4. Oblique abdominal muscles
5. External iliac vessels
6. Internal iliac vessels
7. Pyriformis muscle
8. Sacrum
9. Iliopsoas muscle
10. Sigmoid colon
11. Iliac bone

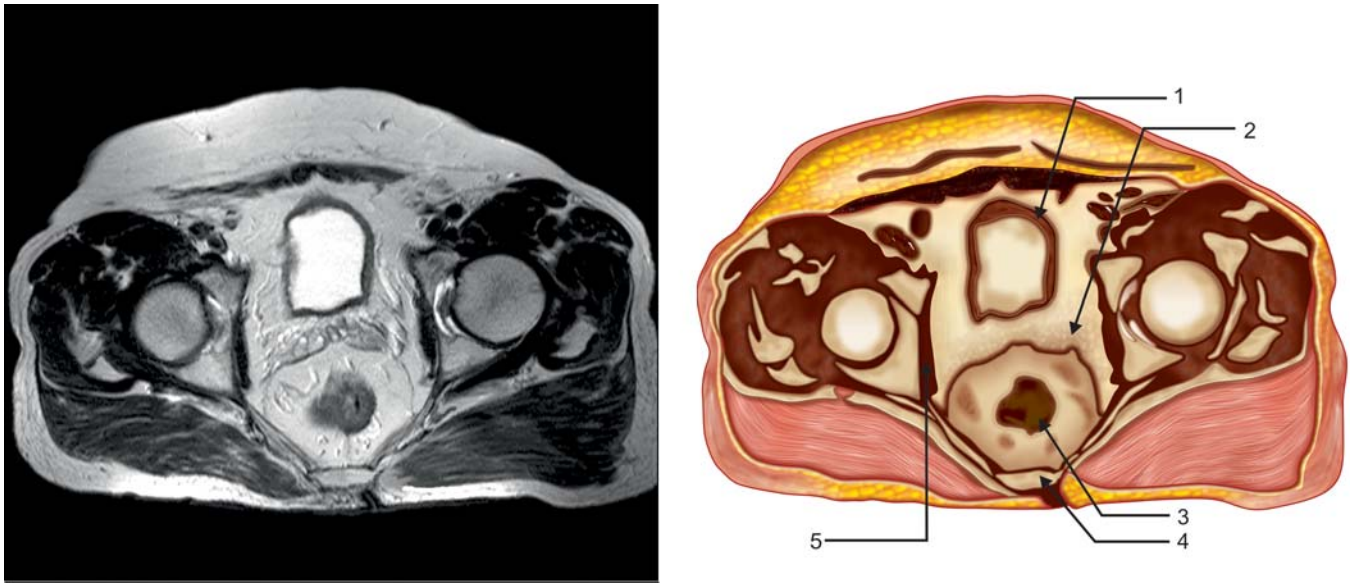

Figure 9.27

1. Urinary bladder
2. Seminal vesicle
3. Rectum
4. Sacrum
5. Obturator internus muscle

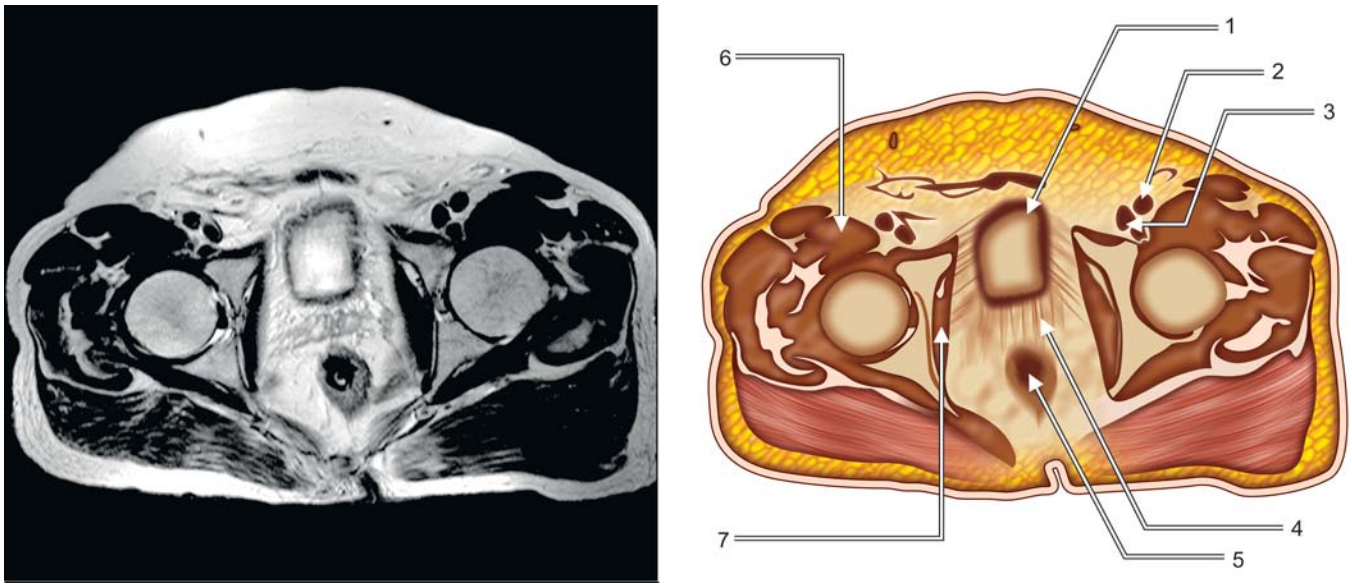

Figure 9.28

1. Urinary bladder
2. Femoral artery
3. Femoral vein
4. Seminal vesicle
5. Rectum
6. Iliopsoas muscle
7. Obturator internus muscle

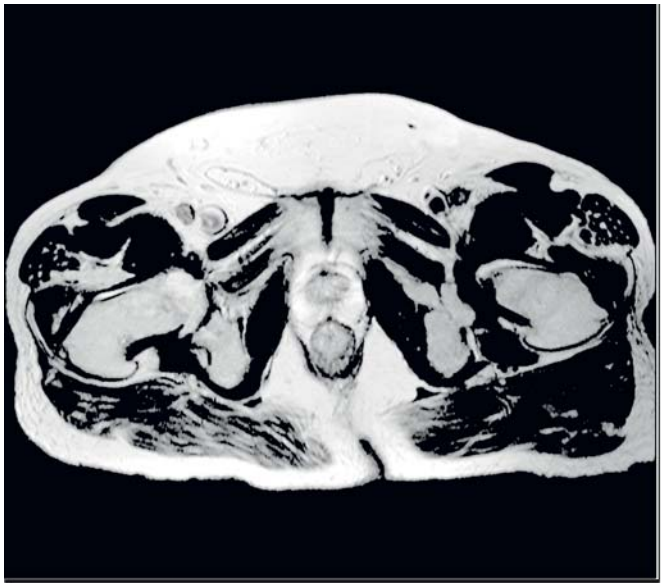

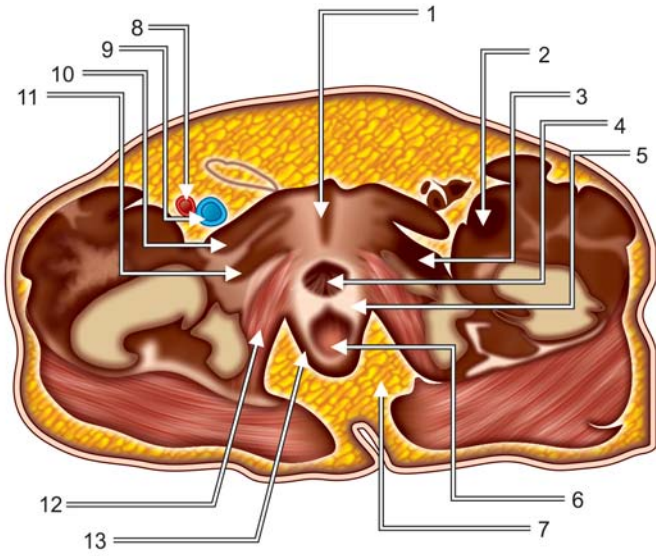

Figure 9.29

1. Pubic symphysis
2. Iliopsoas muscle
3. Obturator externus
4. Prostate-central (fibromuscular) zone
5. Prostate peripheral zone
6. Anal canal
7. Fat in ischiorectal fossa
8. Femoral artery
9. Femoral vein
10. Pectineus muscle
11. Obturator externus
12. Obturator internus muscle
13. Levator ani muscle

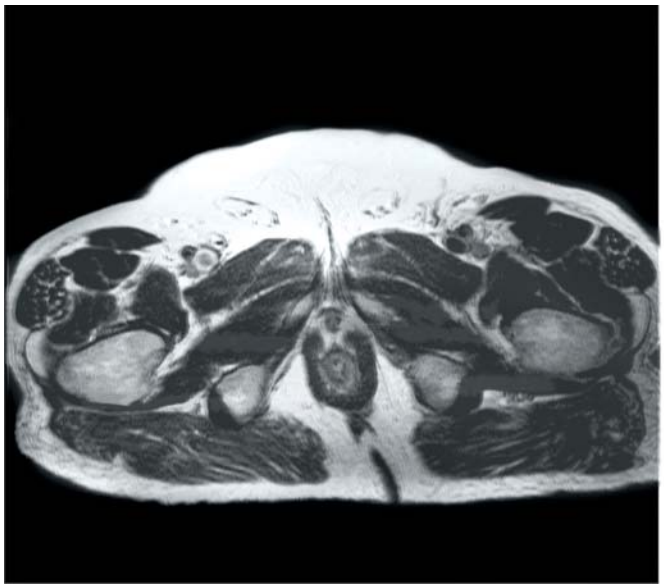

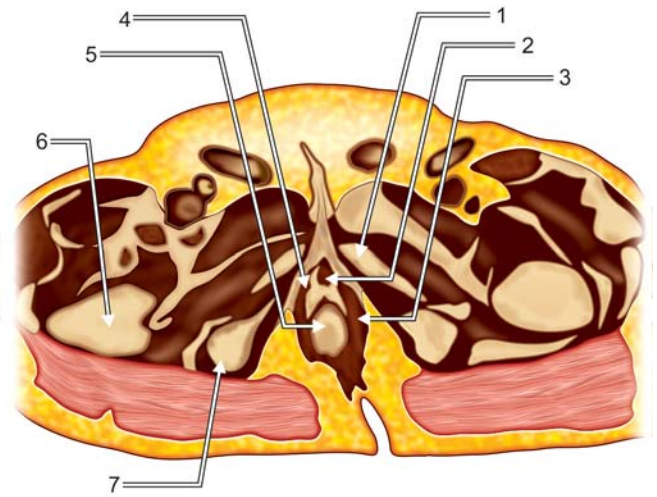

Figure 9.30

1. Pubic ramus
2. Urethra, membranous segment
3. Levator ani muscle
4. Urogenital diaphragm
5. Anus
6. Femur
7. Ischial tuberosity

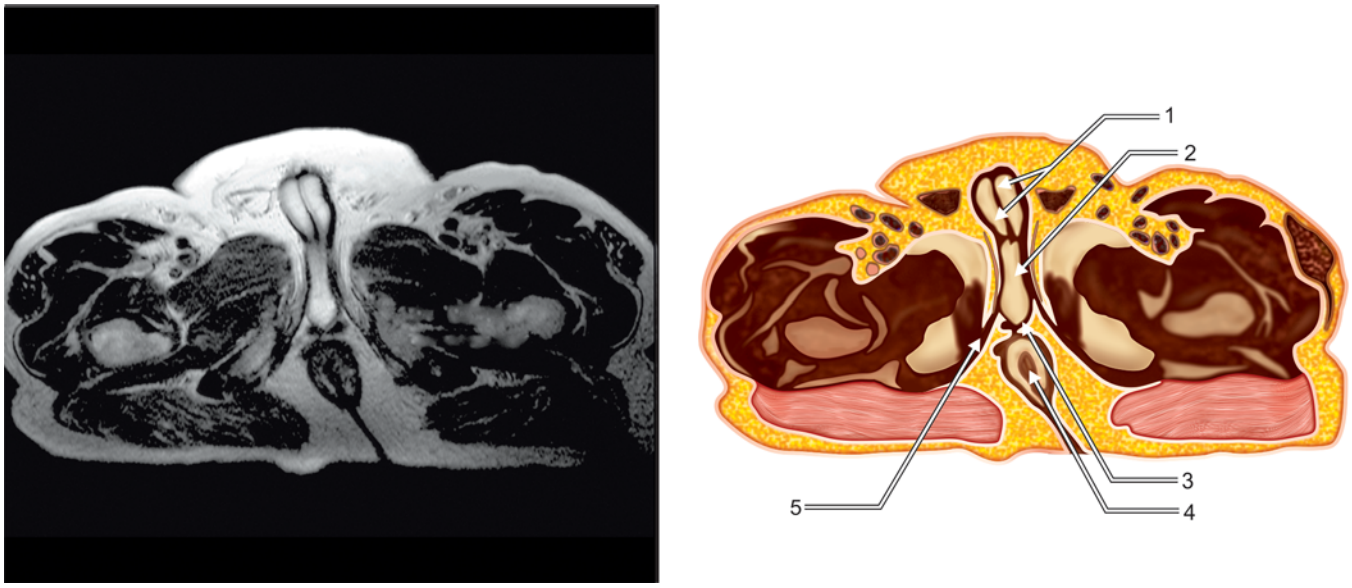

Figure 9.31

1. Corpora cavernosa, penis
2. Corpus spongiosum, penis
3. Bulbospongiosus muscle
4. Anus
5. Ischiocavernosus muscle

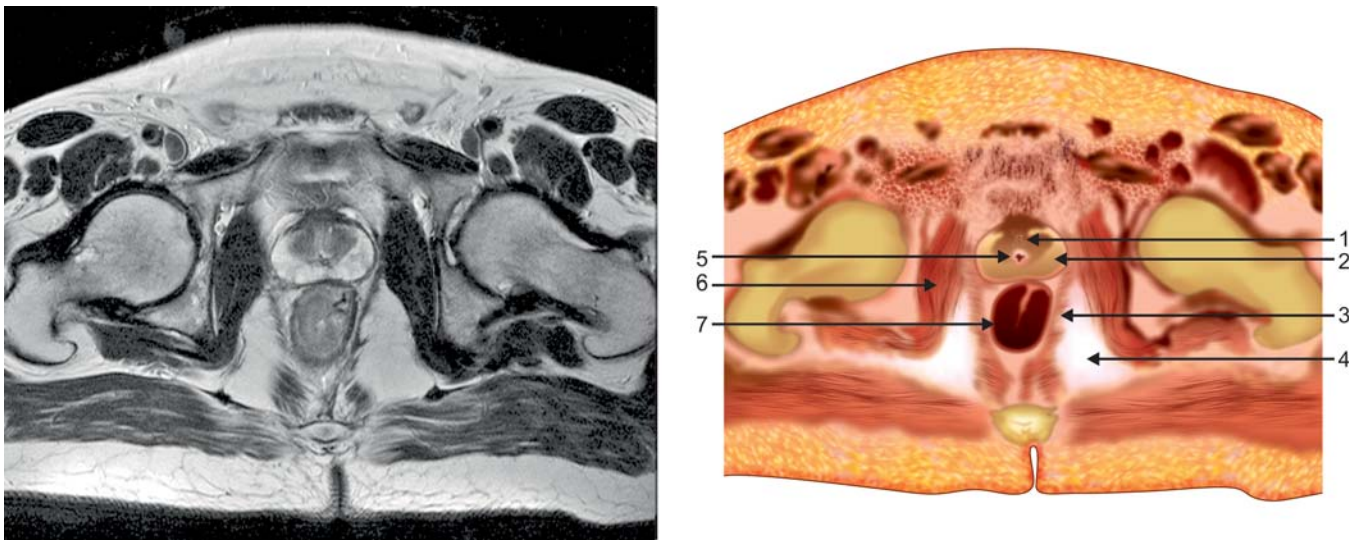

Figure 9.32

1. Prostate-central zone
2. Prostate-peripheral zone
3. Levator ani muscle
4. Ischiorectal fossa
5. Prostatic urethra
6. Obturator internus
7. Rectum

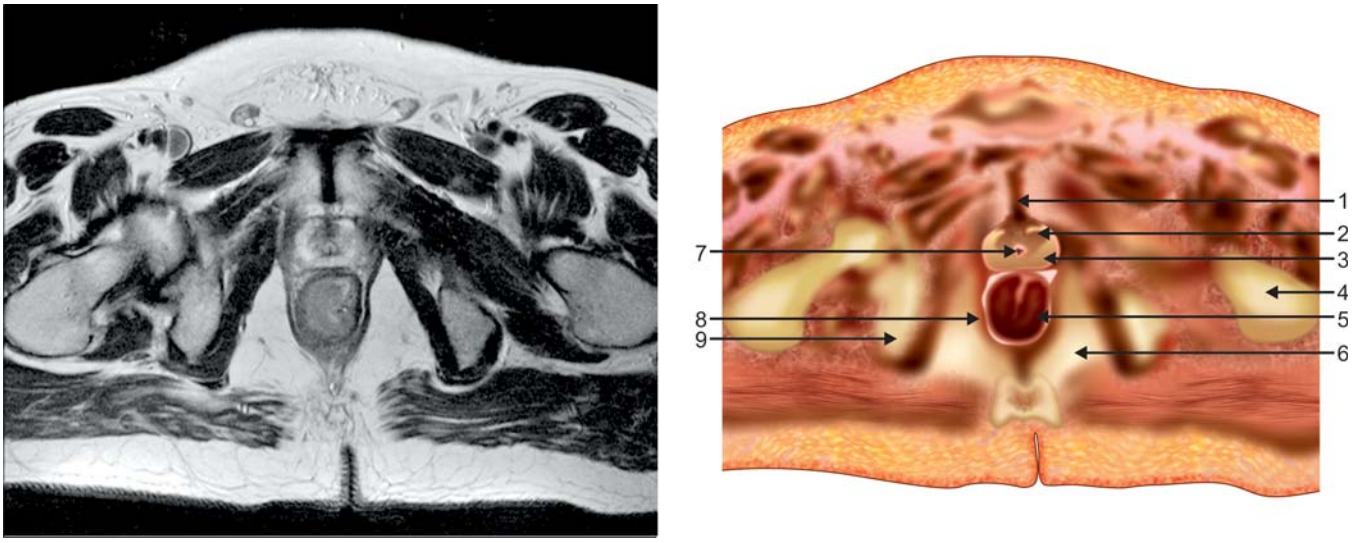

Figure 9.33

1. Pubic symphysis
2. Central zone
3. Peripheral zone
4. Femur
5. Anal canal
6. Ischiorectal fossa
7. Urethra
8. Levator ani muscle
9. Ischial tuberosity

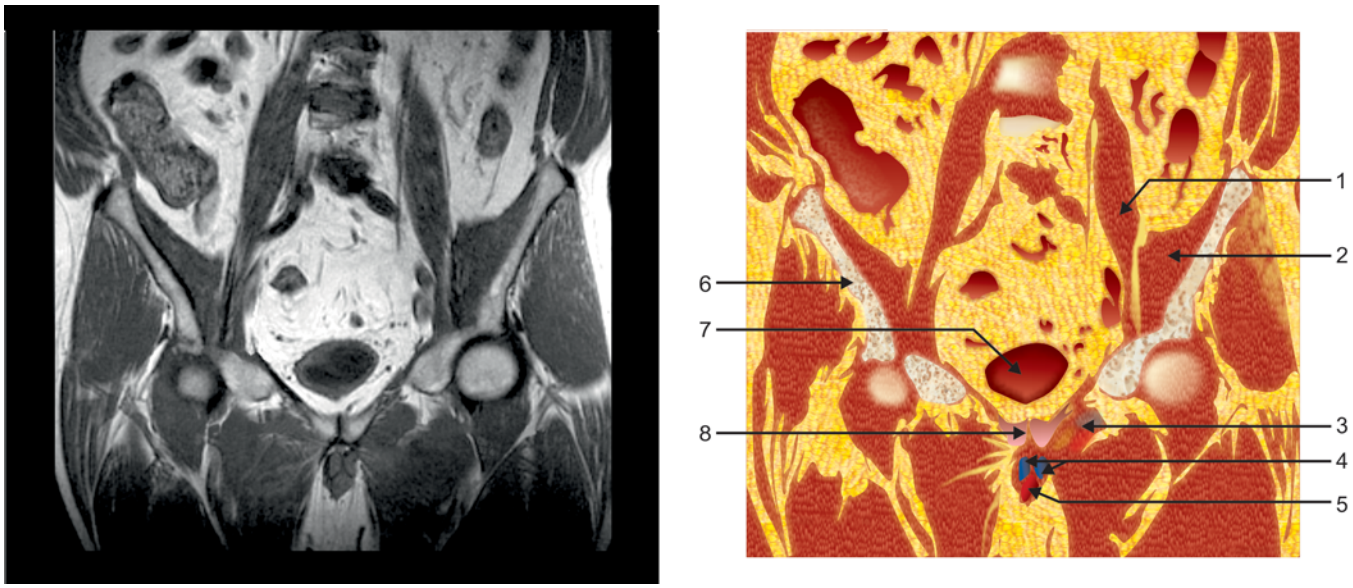

Figure 9.34

1. Psoas
2. Iliacus
3. Obturator externus
4. Corpora cavernosa
5. Corpus spongiosum
6. Ilium
7. Urinary bladder
8. Pubic symphysis

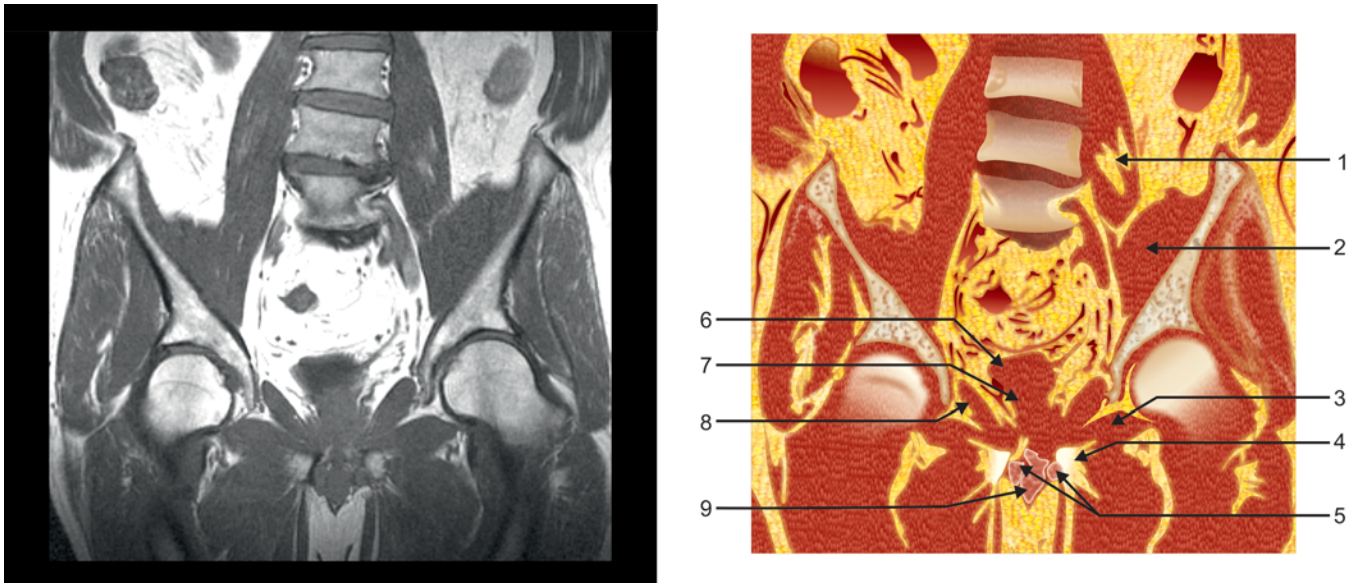

Figure 9.35

1. Psoas
2. Iliacus
3. Obturator externus
4. Pubic ramus
5. Corpora cavernosa
6. Urinary bladder
7. Prostate
8. Obturator internus
9. Corpus spongiosum

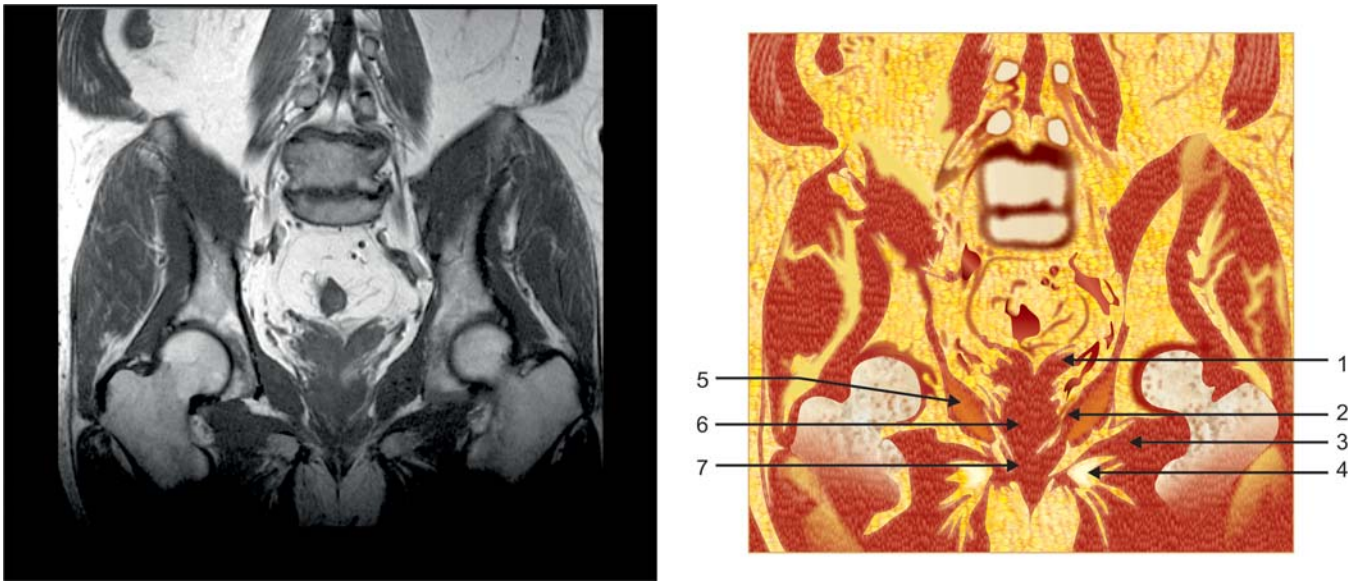

Figure 9.36

1. Seminal vesicle
2. Levator ani muscle
3. Obturator externus
4. Pubic ramus
5. Obturator internus
6. Prostate gland
7. Urogenital diaphragm

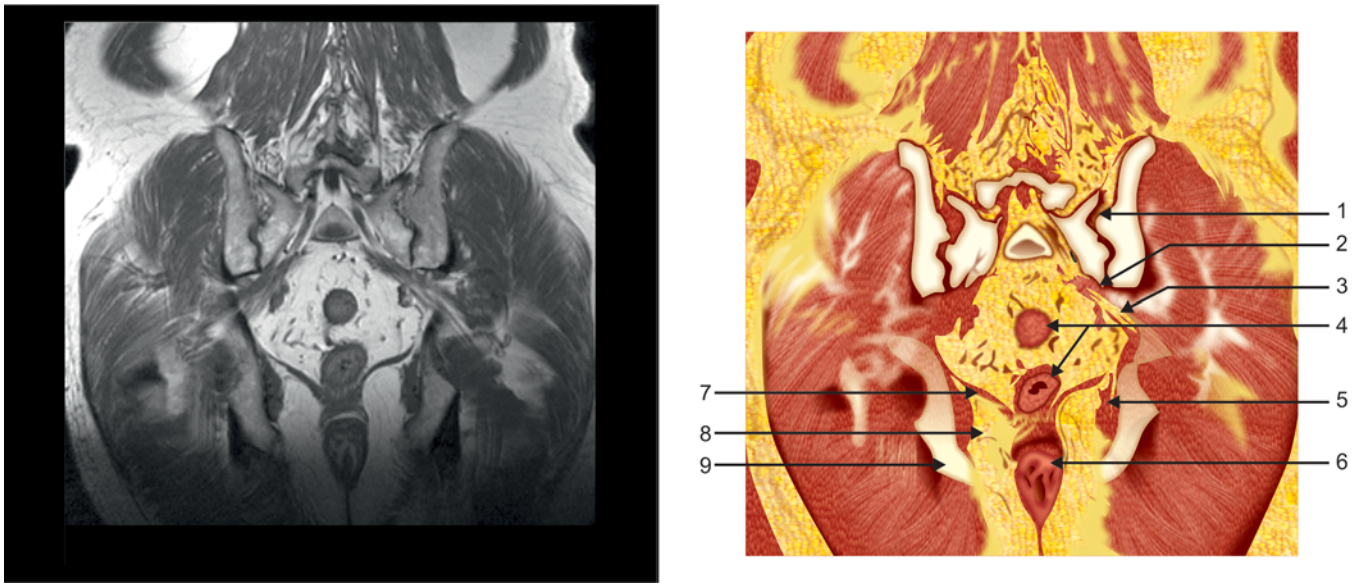

Figure 9.37

1. SI joint
2. Piriformis muscle
3. Lumbosacral plexus
4. Rectum
5. Obturator internus muscle
6. Anal canal
7. Levator ani muscle
8. Ischiorectal fossa
9. Ischium

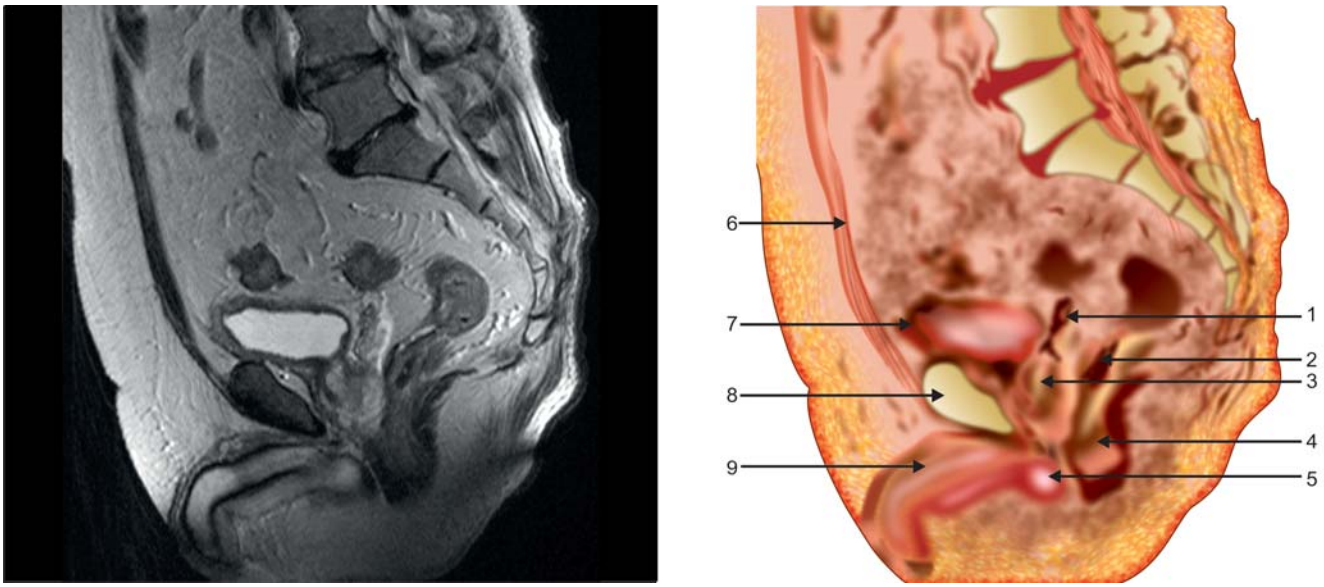

Figure 9.38

1. Seminal vesicle
2. Rectum
3. Prostate
4. Anal canal
5. Bulb of penis
6. Rectus abdominis
7. Urinary bladder
8. Pubic bone
9. Corpus cavernosum

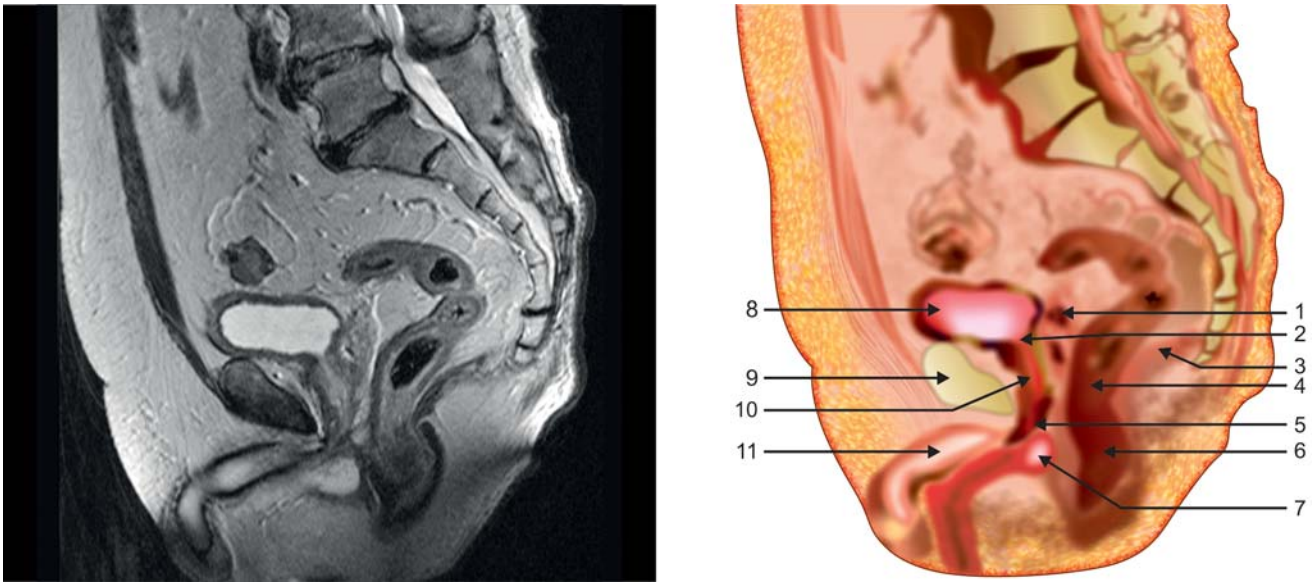

Figure 9.39

1. Seminal vesicle
2. Bladder neck
3. Levator ani muscle
4. Rectum
5. Urogenital diaphragm
6. Anal canal
7. Bulb of penis
8. Urinary bladder
9. Pubis bone
10. Prostatic urethra
11. Penis

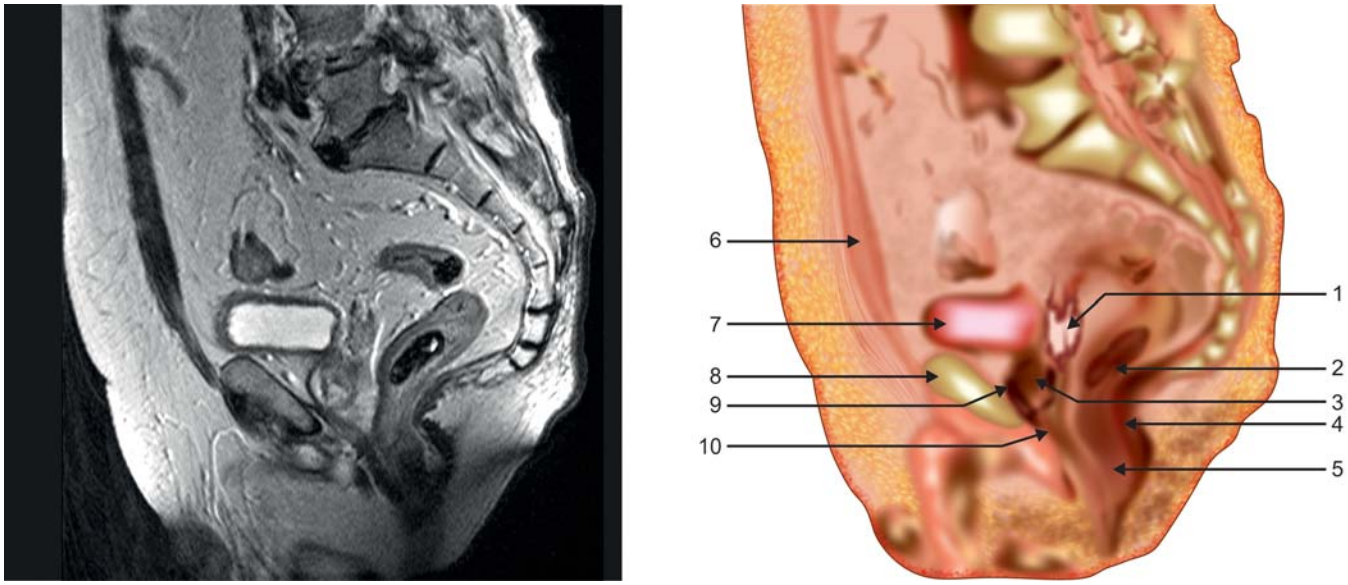

Figure 9.40

1. Seminal vesicle
2. Rectum
3. Prostate, central zone
4. Levator ani & coccygeus muscle
5. Anal canal
6. Rectus abdominis muscle
7. Urinary bladder
8. Pubic ramus
9. Prostate, peripheral zone
10. Obturator internus

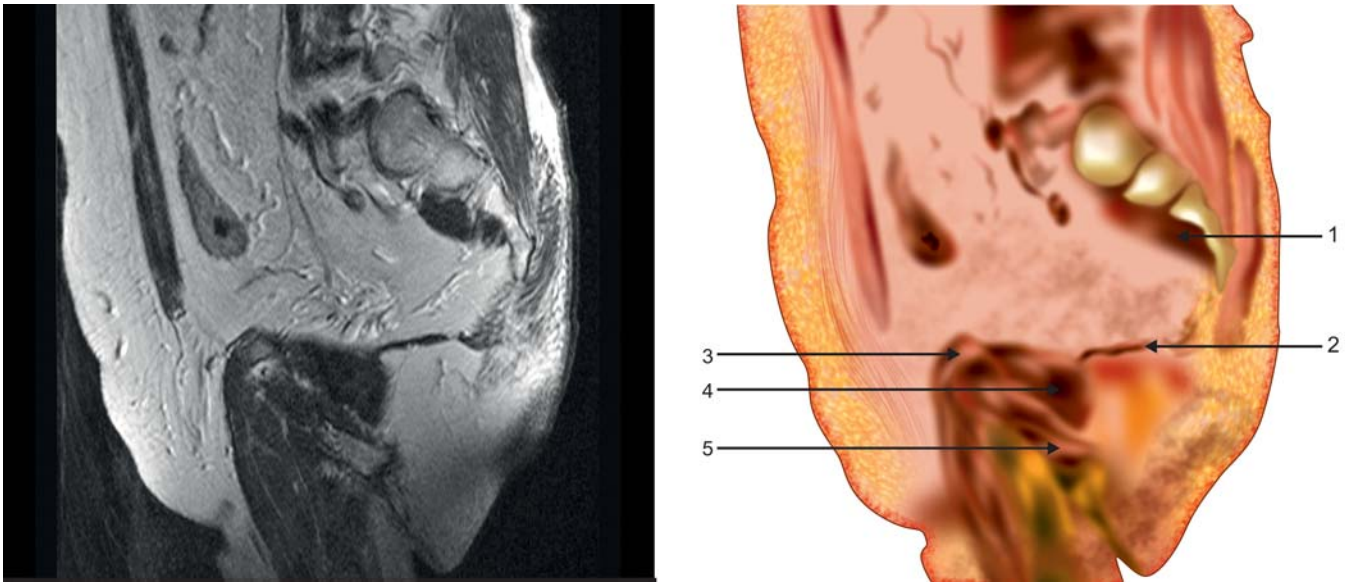

Figure 9.41

1. Pyriformis
2. Levator ani muscle
3. Pubic ramus
4. Obturator internus
5. Ischium

Section 4

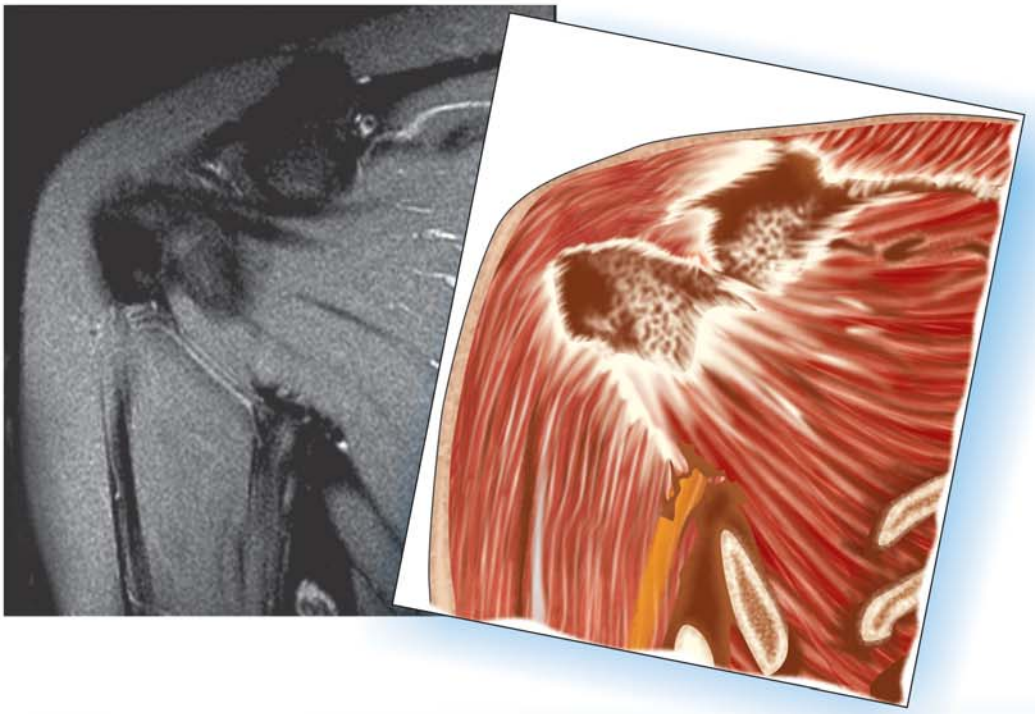

Upper Extremity

- **Shoulder**
- **Arm and Forearm**
- **Elbow**
- **Wrist**
- **Upper Extremity Vessels**

CHAPTER 10

Shoulder

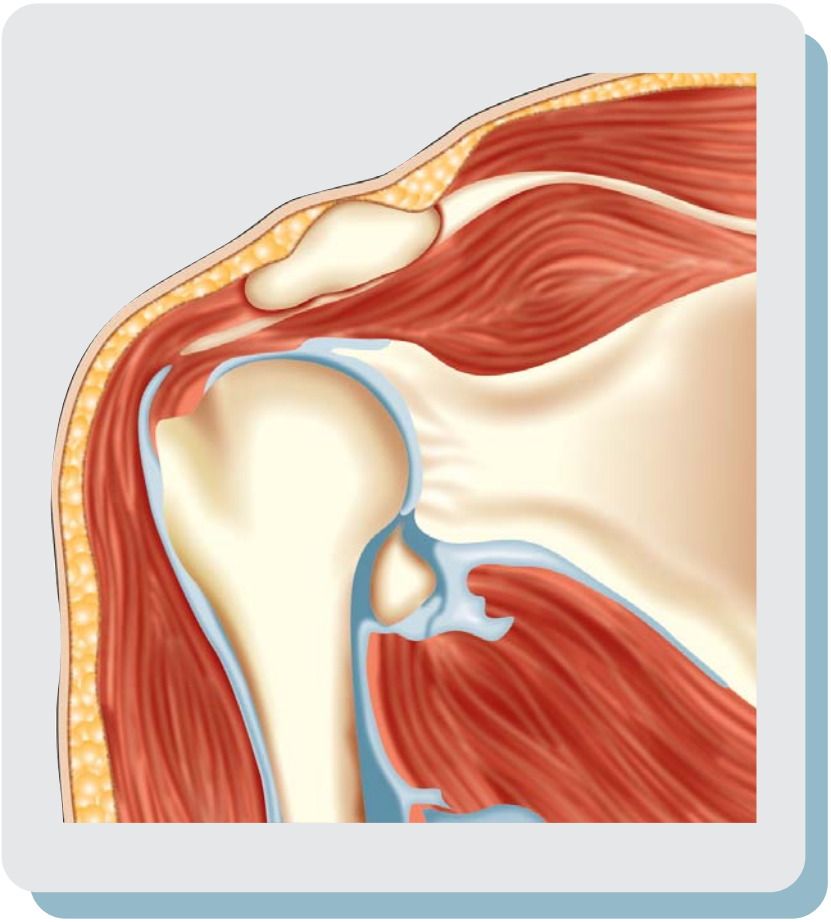

X-RAYS

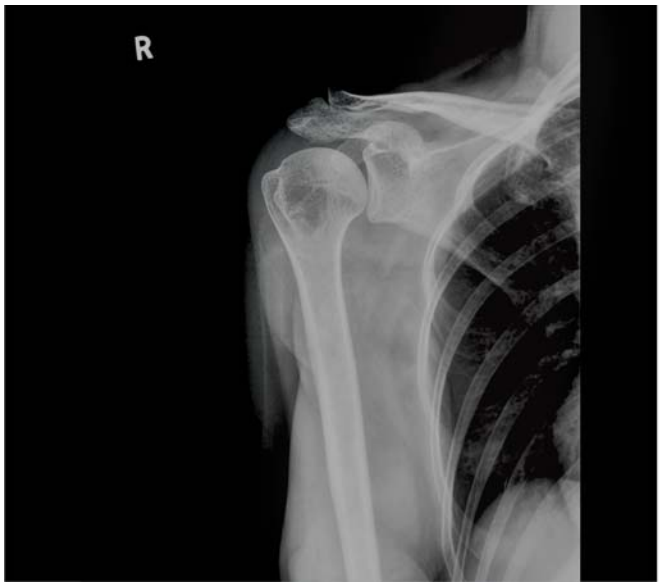

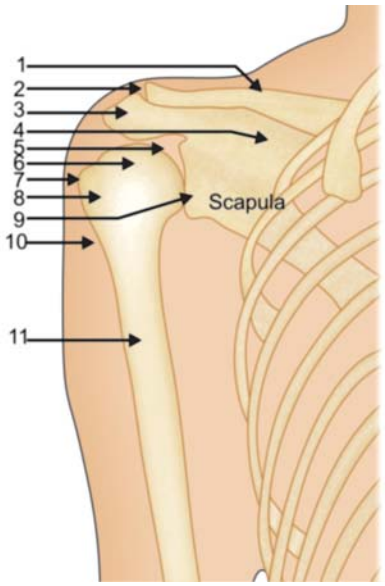

Figure 10.1

1. Clavicle
2. Acromio-clavicular joint
3. Acromion process
4. Scapula spine
5. Coracoid process
6. Humerus, head
7. Greater tuberosity
8. Lesser tuberosity
9. Glenoid fassa
10. Surgical neck
11. Humerus shaft

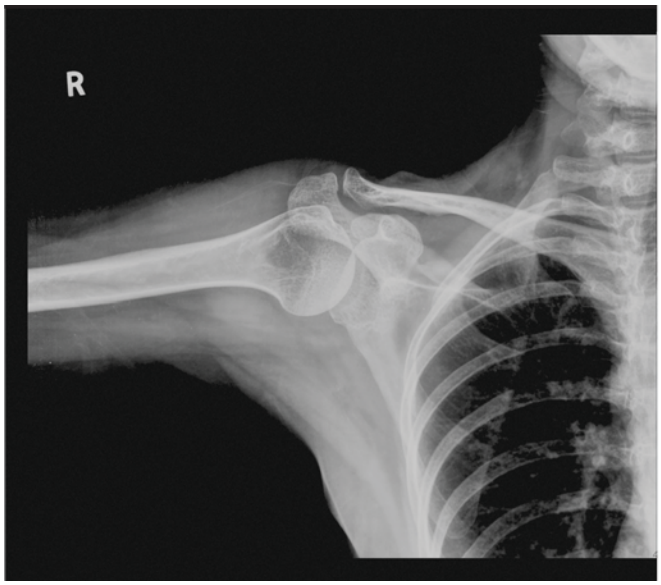

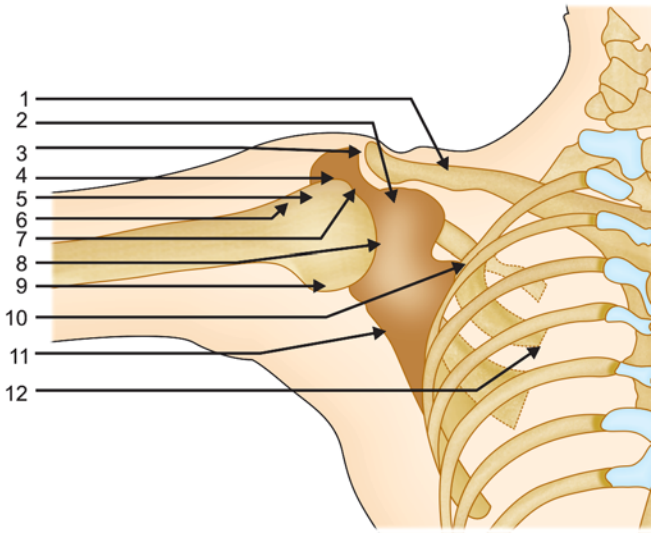

Figure 10.2

1. Clavicle
2. Coracoid process
3. Acromio-clavicular joint
4. Greater tuberosity
5. Lesser tuberosity
6. Intertubercular sulcus
7. Acromion process
8. Glenoid fassa
9. Humerus, head
10. Scapular spine
11. Scapula, lateral border
12. Scapula, medial border

MR ARTHROGRAM SHOULDER JOINT: CORONAL IMAGES—ANTERIOR TO POSTERIOR

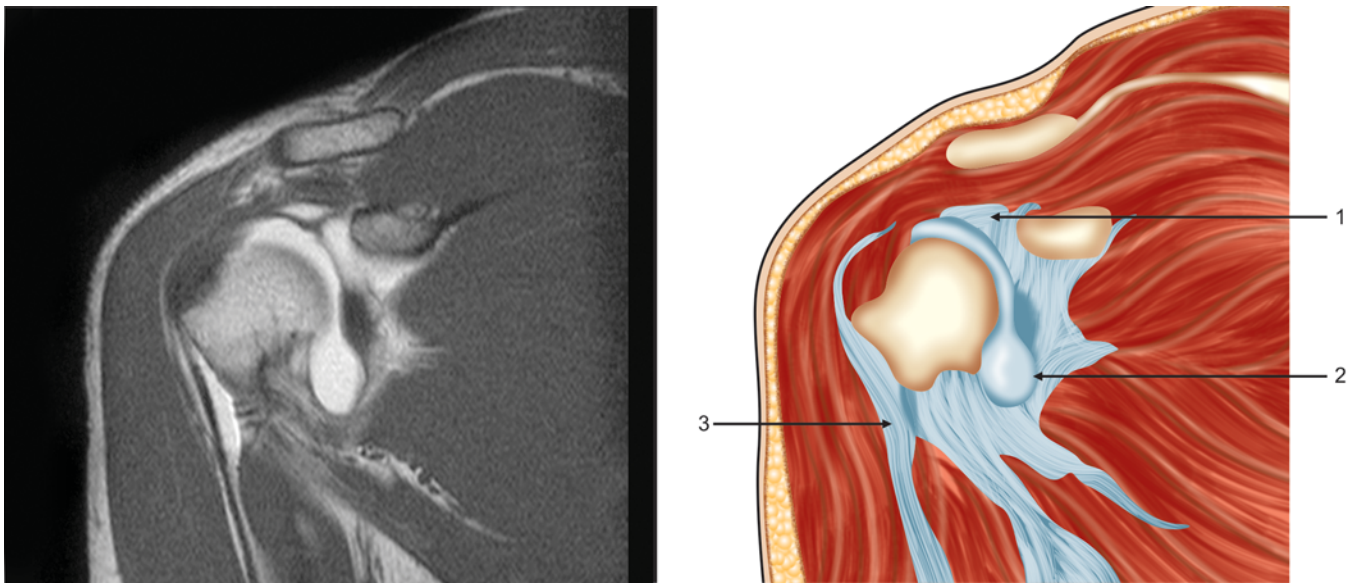

Figure 10.3

1. Superior glenohumeral ligament
2. Inferior glenohumeral ligament
3. Biceps tendon, long head

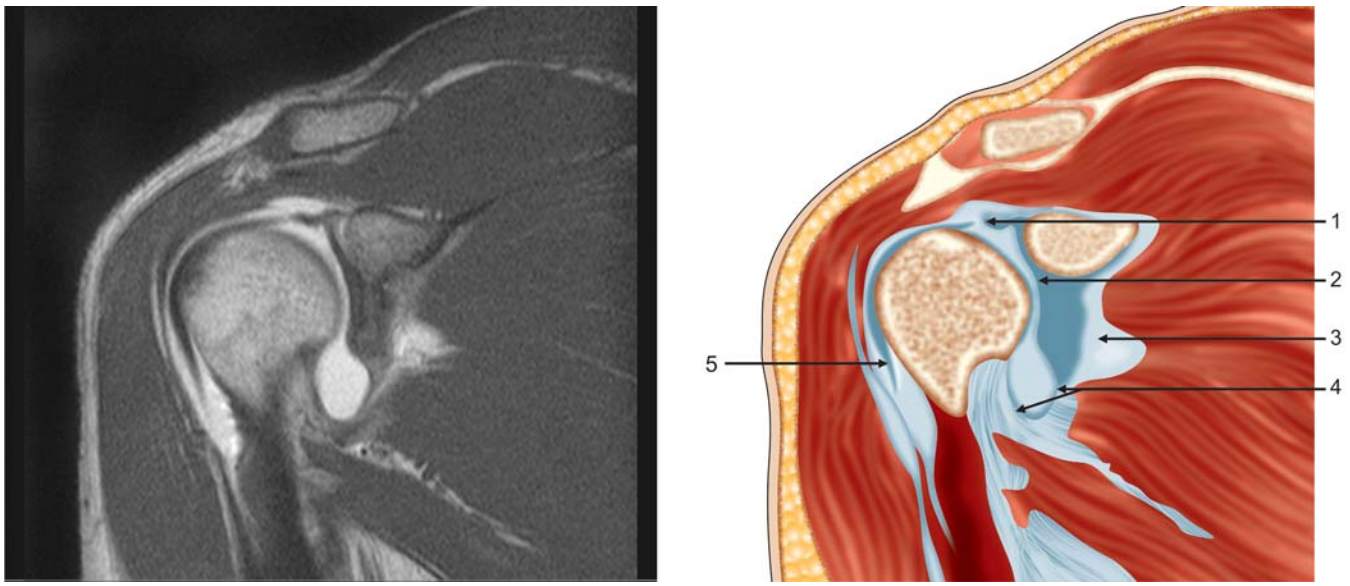

Figure 10.4

1. Biceps labral complex
2. Labrum
3. Subscapularis bursa
4. Inferior glenohumeral ligament
5. Biceps tendon, long head

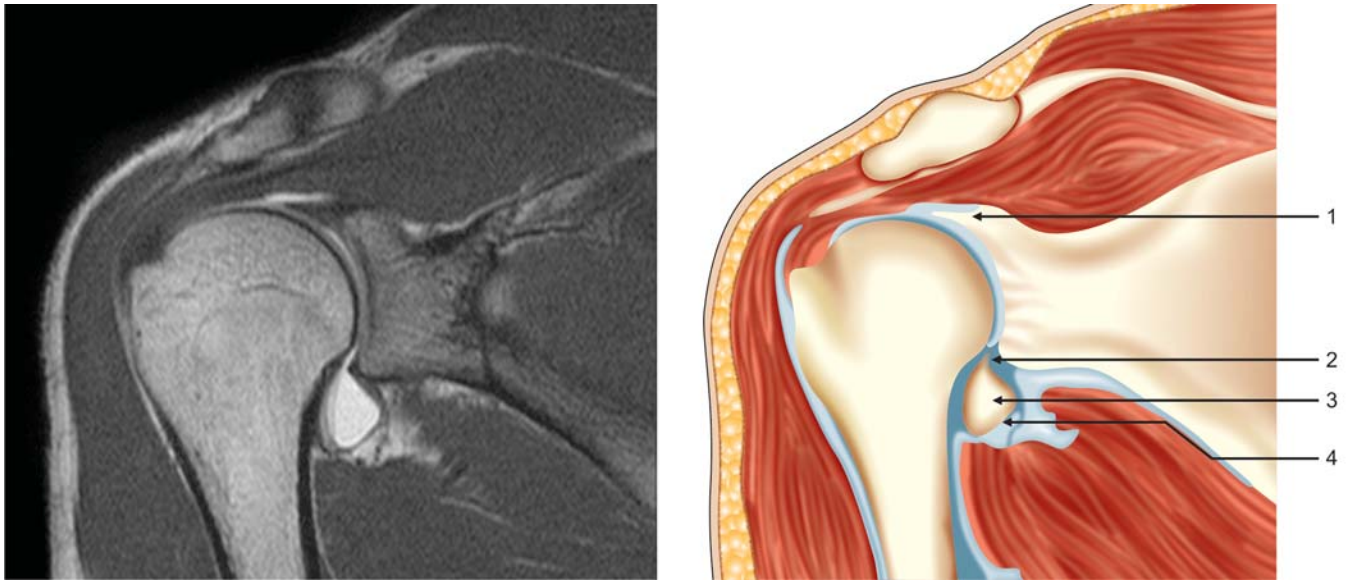

Figure 10.5

1. Superior labrum
2. Inferior labrum
3. Axillary pouch
4. Inferior glenohumeral ligament

MR ARTHROGRAM SHOULDER JOINT: SAGITTAL IMAGES—MEDIAL TO LATERAL

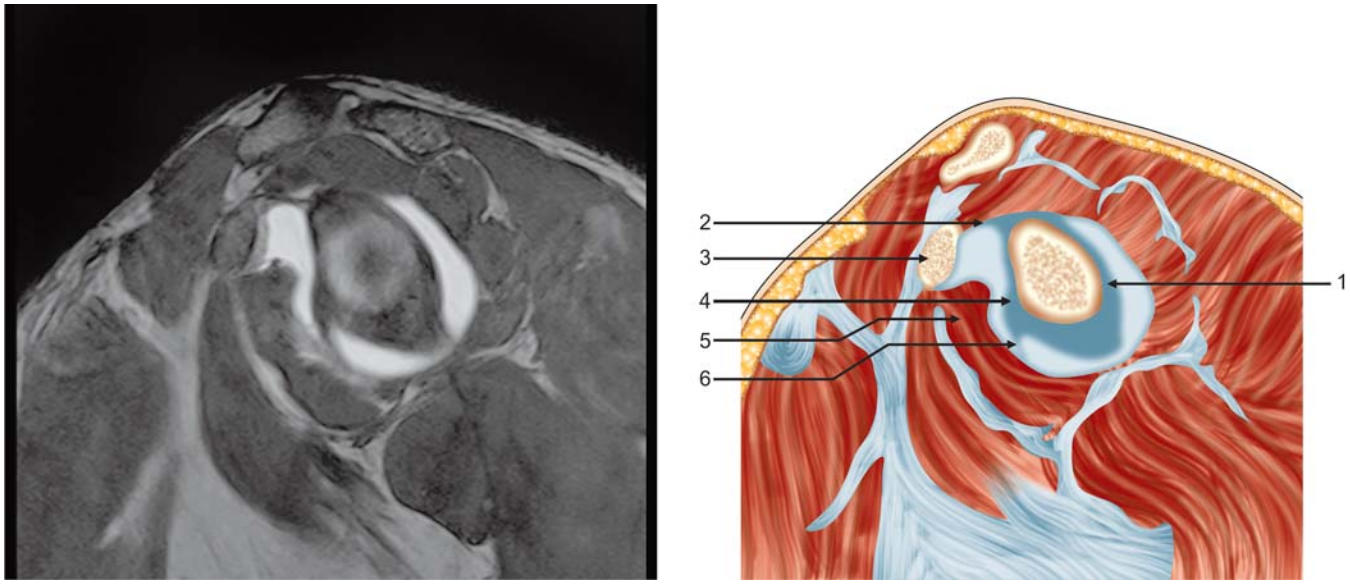

Figure 10.6

1. Posterior labrum
2. Superior glenohumeral ligament
3. Coracoid process
4. Anterior labrum
5. Subscapularis
6. Middle glenohumeral ligament

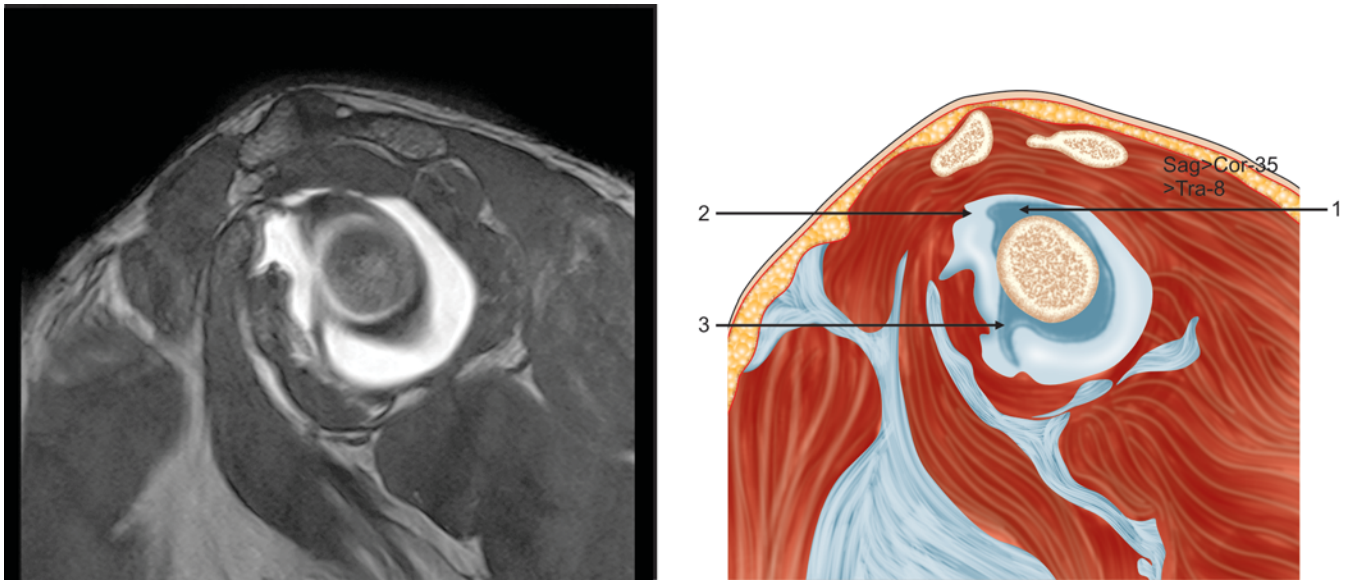

Figure 10.7

1. Biceps labral complex
2. Superior glenohumeral ligament
3. Middle glenohumeral ligament

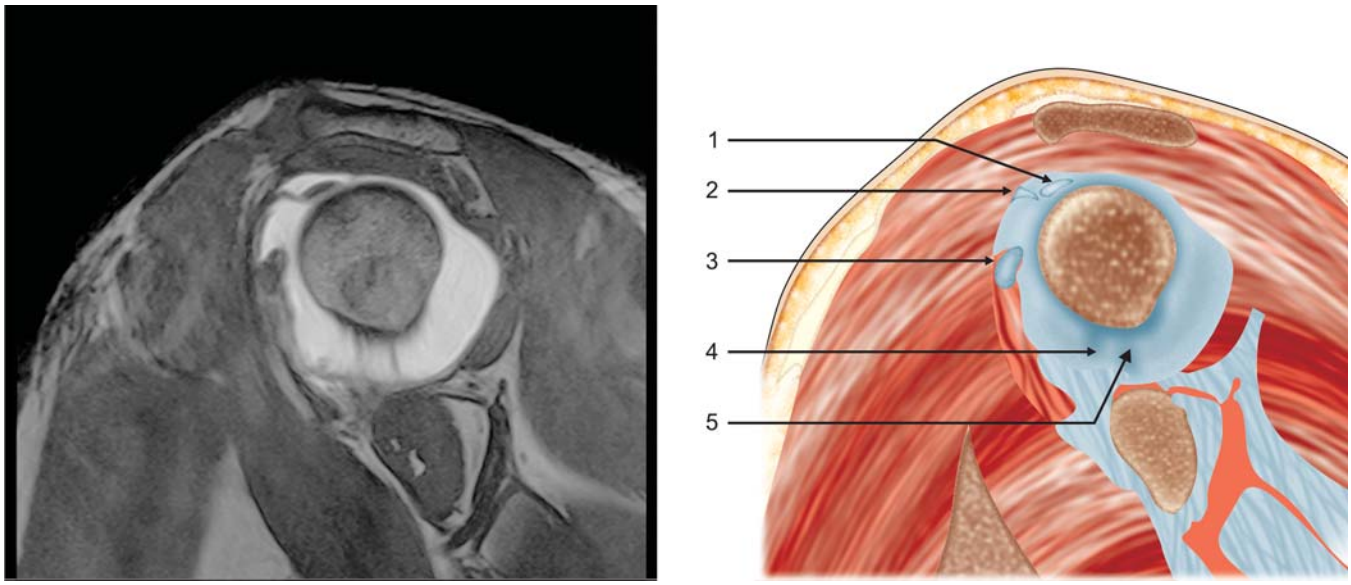

Figure 10.8

1. Biceps tendon
2. Superior glenohumeral ligament
3. Subscapularis tendon
4. Inferior glenohumeral ligament, anterior band
5. Inferior glenohumeral ligament, posterior band

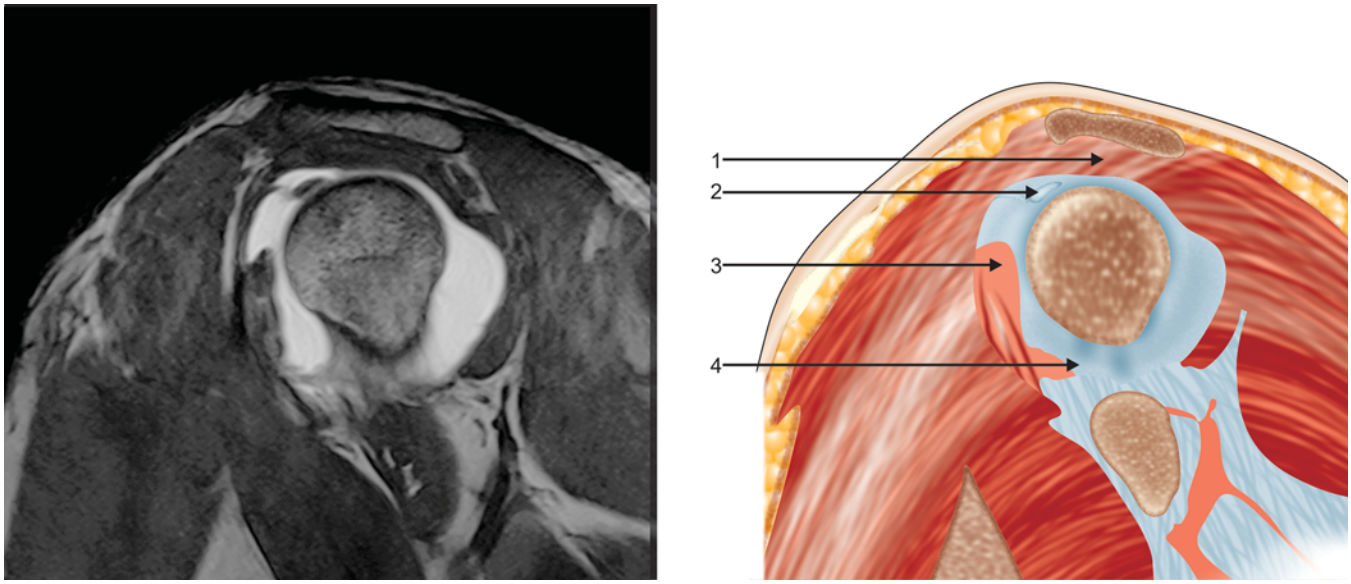

Figure 10.9

1. Supraspinatus tendon
2. Biceps tendon
3. Subscapularis tendon
4. Inferior glenohumeral ligament, axillary band

MR SHOULDER JOINT: AXIAL IMAGES—SUPERIOR TO INFERIOR

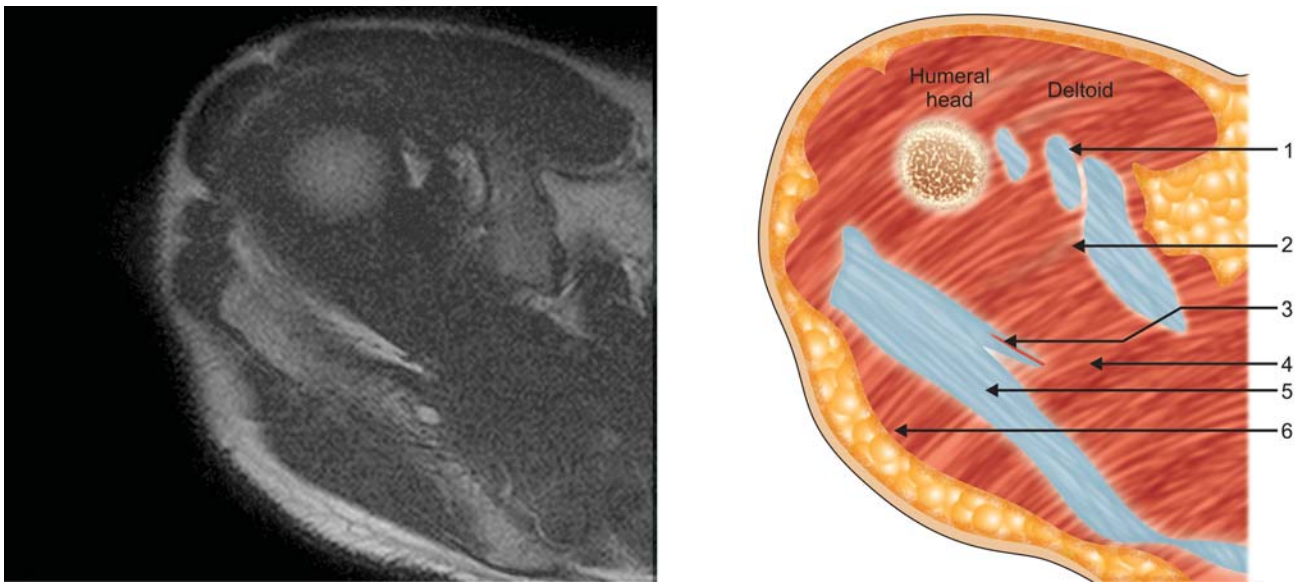

Figure 10.10

1. Coracoid process
2. Supraglenoid tuberosity
3. Suprascapular artery
4. Supraspinatus
5. Scapular spine
6. Deltoid

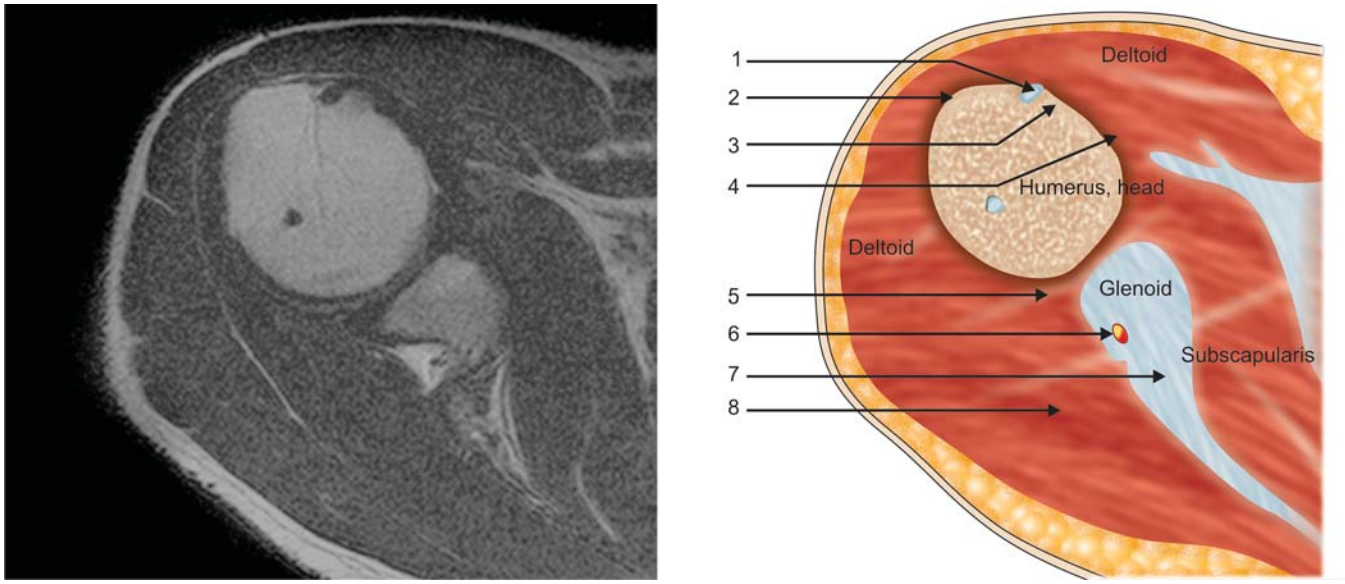

Figure 10.11

1. Biceps tendon, long head
2. Greater tuberosity
3. Lesser tuberosity
4. Subscapularis, tendon
5. Posterior labrum
6. Suprascapular artery and nerve
7. Scapular body
8. Infraspinatus

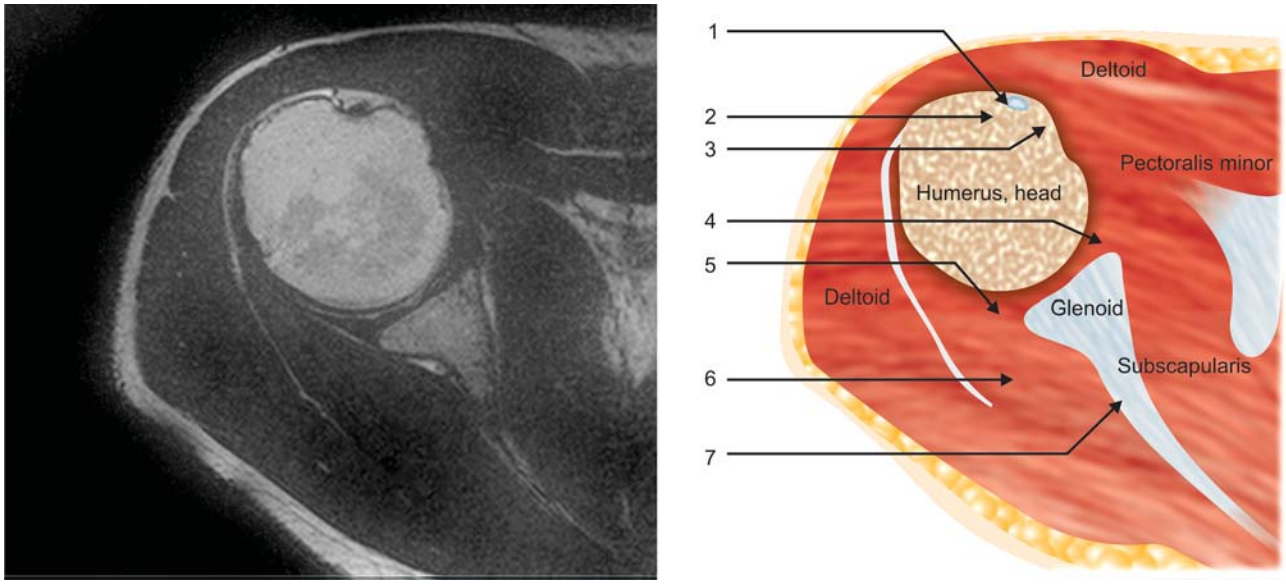

Figure 10.12

1. Biceps tendon, long head
2. Bicipital groove
3. Lesser tuberosity
4. Anterior labrum
5. Posterior labrum
6. Infraspinatus
7. Scapula

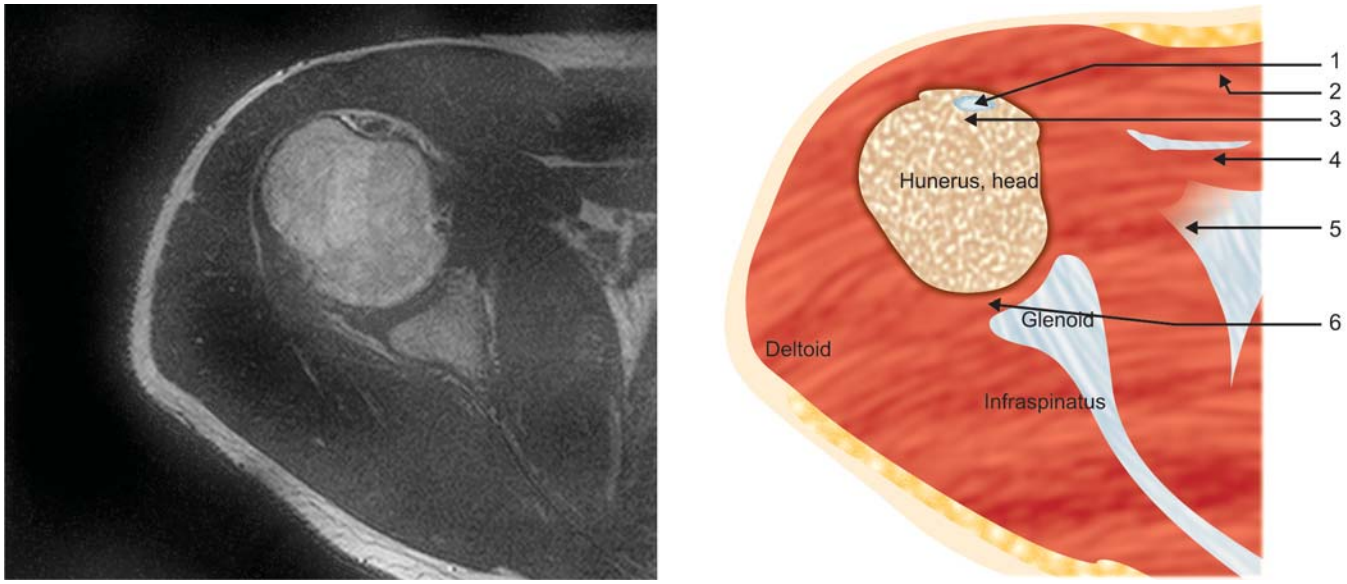

Figure 10.13

1. Biceps tendon, long head
2. Pectoralis major
3. Bicipital groove
4. Pectoralis minor
5. Neurovascular bundle
6. Inferior labrum

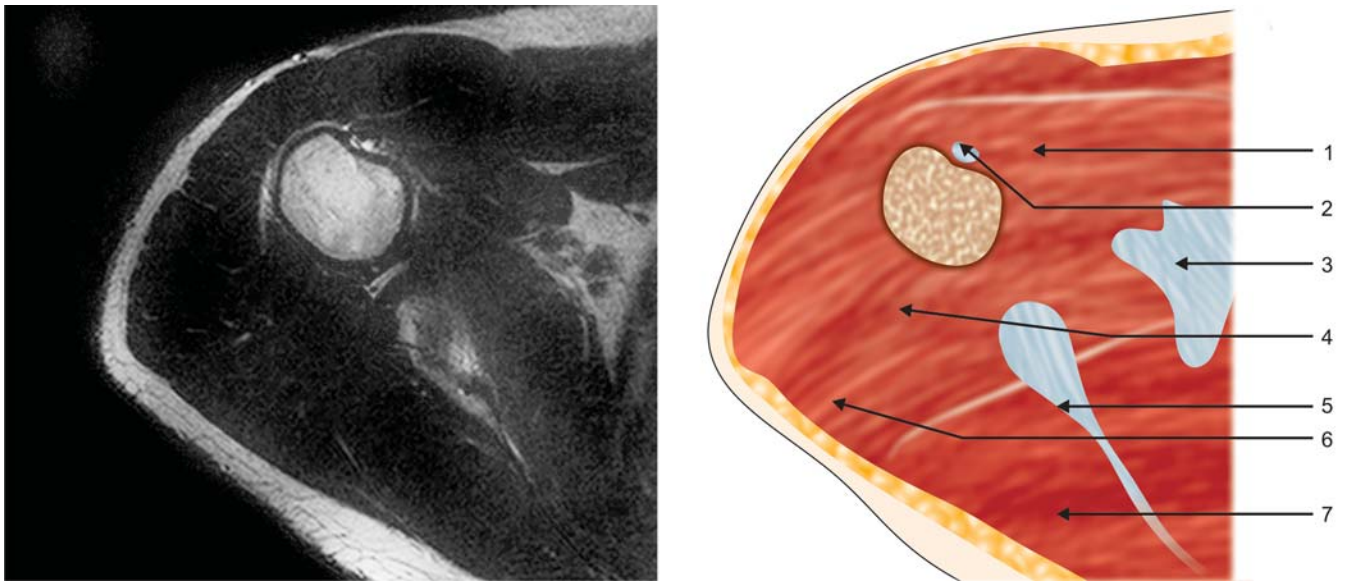

Figure 10.14

1. Coracobrachialis, short head biceps
2. Biceps tendon, long head
3. Neurovascular bundle
4. Teres minor
5. Scapula
6. Deltoid
7. Infraspinatus

MR SHOULDER JOINT: CORONAL IMAGES—ANTERIOR TO POSTERIOR

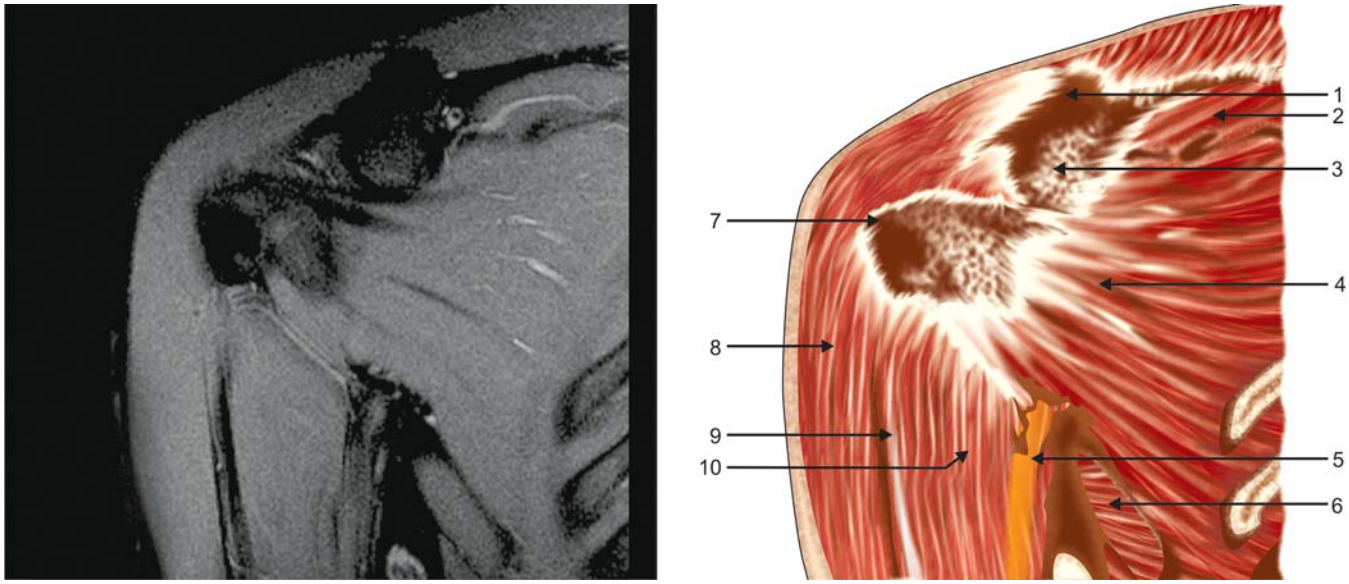

Figure 10.15

1. Clavicle
2. Supraspinatus
3. Coracoid process
4. Subscapularis muscle, tendon
5. Neurovascular bundle
6. Latissimus dorsi
7. Lesser tuberosity
8. Deltoid
9. Biceps tendon, long head
10. Biceps brachii

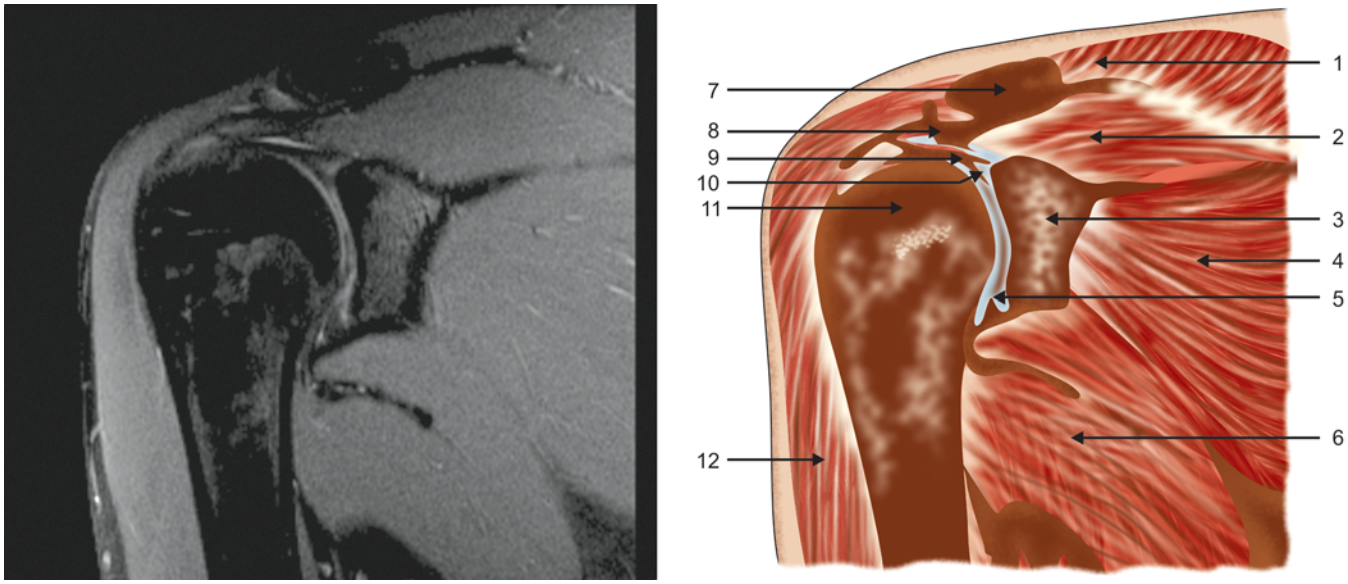

Figure 10.16

1. Trapezius
2. Supraspinatus muscle
3. Glenoid
4. Subscapularis
5. Inferior labrum
6. Latissimus dorsi and teres major
7. Clavicle
8. Supraspinatus tendon
9. Biceps-labral complex
10. Superior labrum
11. Humerus, head
12. Deltoid

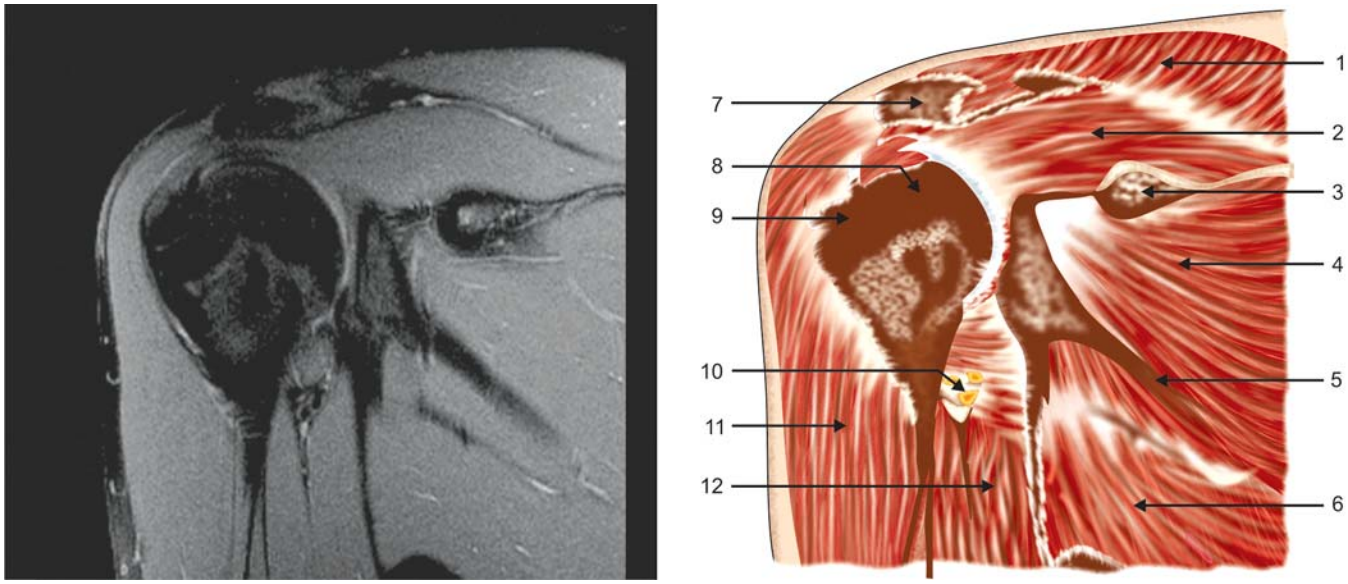

Figure 10.17

1. Trapezius
2. Supraspinatus
3. Scapular spine
4. Infraspinatus
5. Scapula
6. Teres minor
7. Acromion process
8. Humerus, head
9. Greater tuberosity
10. Profunda brachii vessels, radial nerve
11. Deltoid
12. Triceps, long head

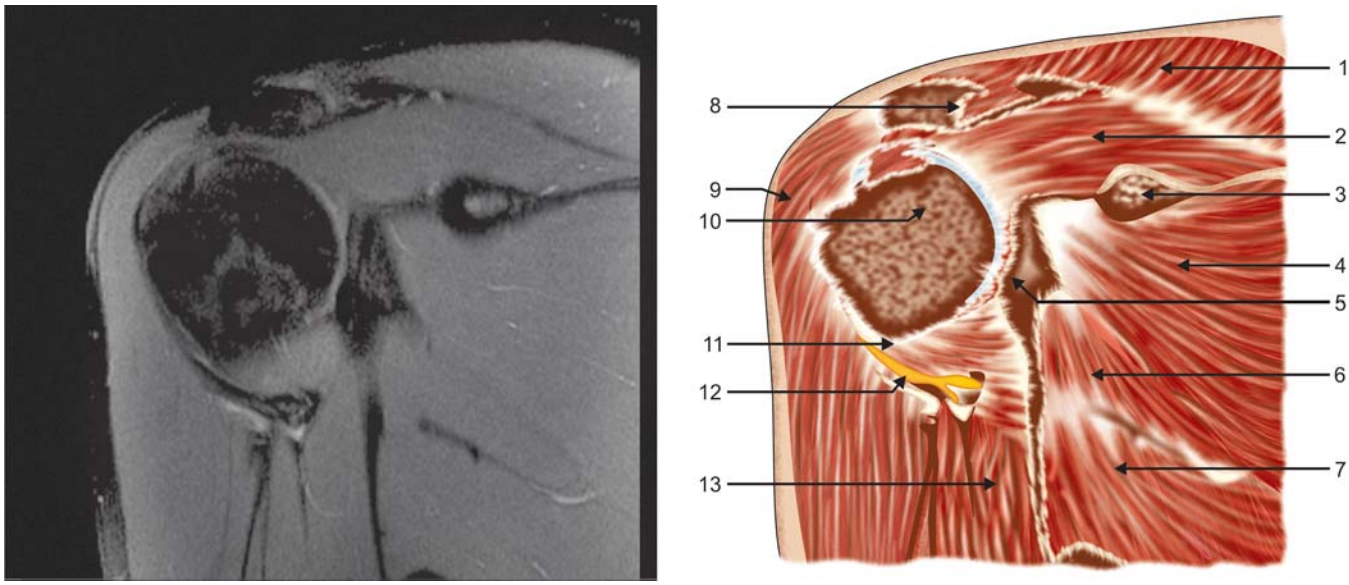

Figure 10.18

1. Trapezius
2. Supraspinatus
3. Scapular spine
4. Infraspinatus
5. Labrum
6. Teres minor
7. Teres major
8. Acromion process
9. Deltoid
10. Humerus, head
11. Surgical neck
12. Posterior circumflex artery, axillary nerve
13. Triceps, long head

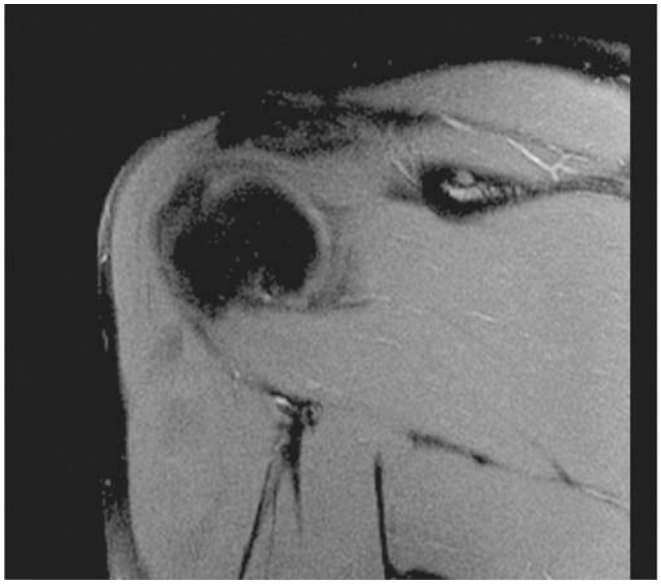

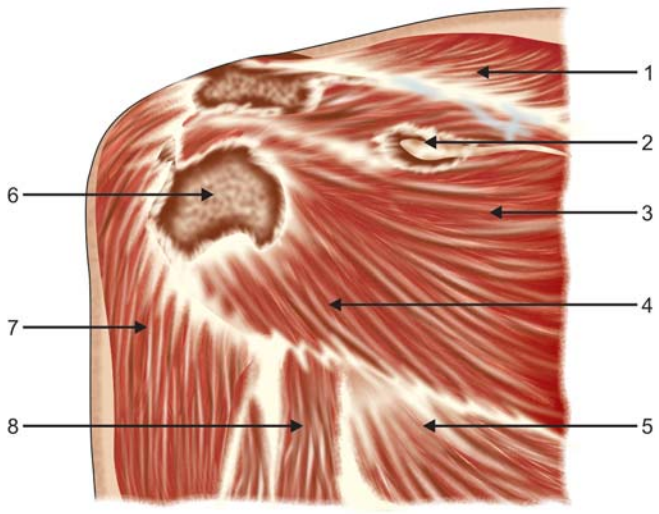

Figure 10.19

1. Trapezius
2. Scapular spine
3. Infraspinatus
4. Teres minor
5. Teres major
6. Humerus, head
7. Deltoid
8. Triceps

CHAPTER 11

Arm and Forearm

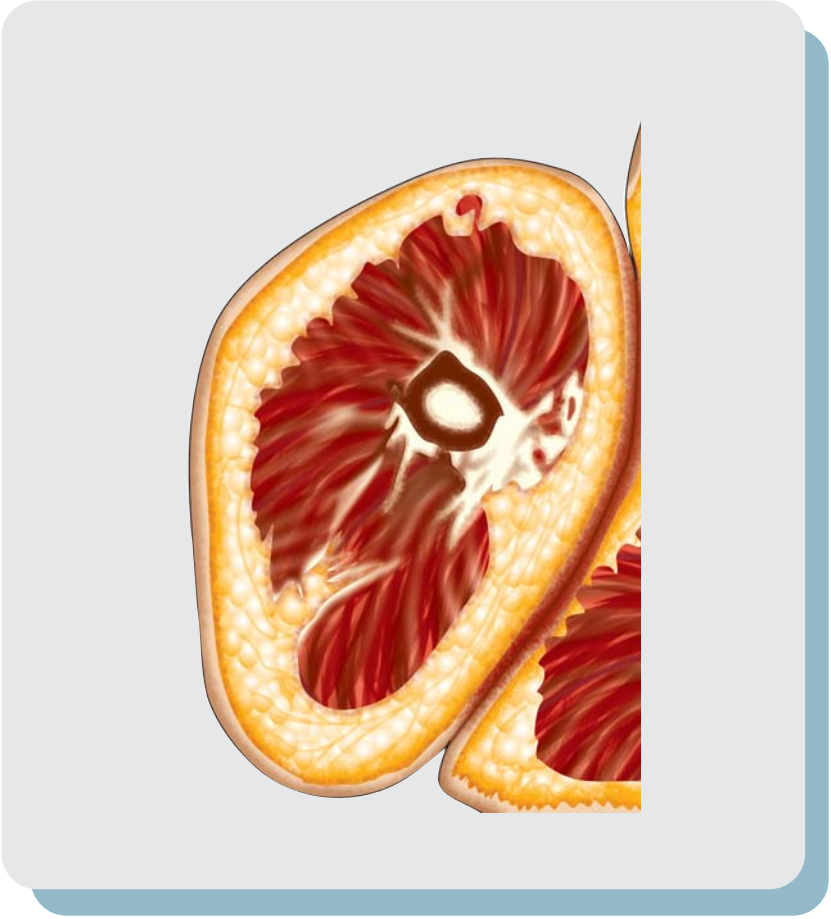

ARM

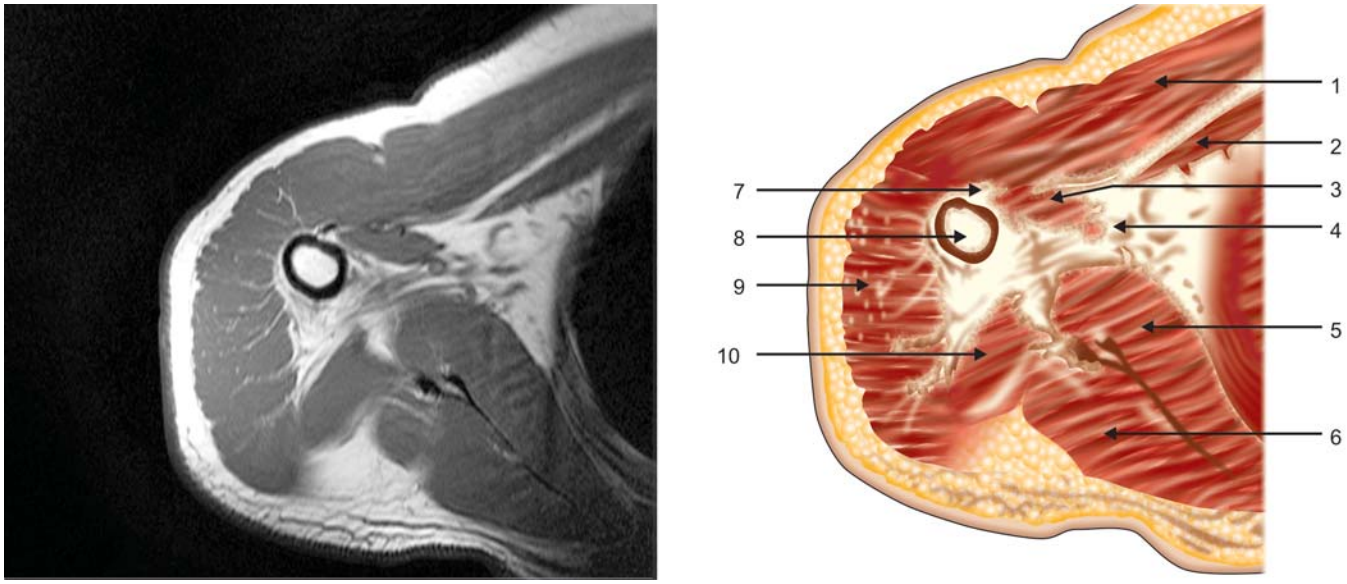

Figure 11.1

1. Pectoralis major
2. Pectoralis minor
3. Biceps brachii, short head
4. Neurovascular bundle
5. Subscapularis
6. Infraspinatus
7. Biceps, long head tendon
8. Humerus
9. Deltoid
10. Triceps

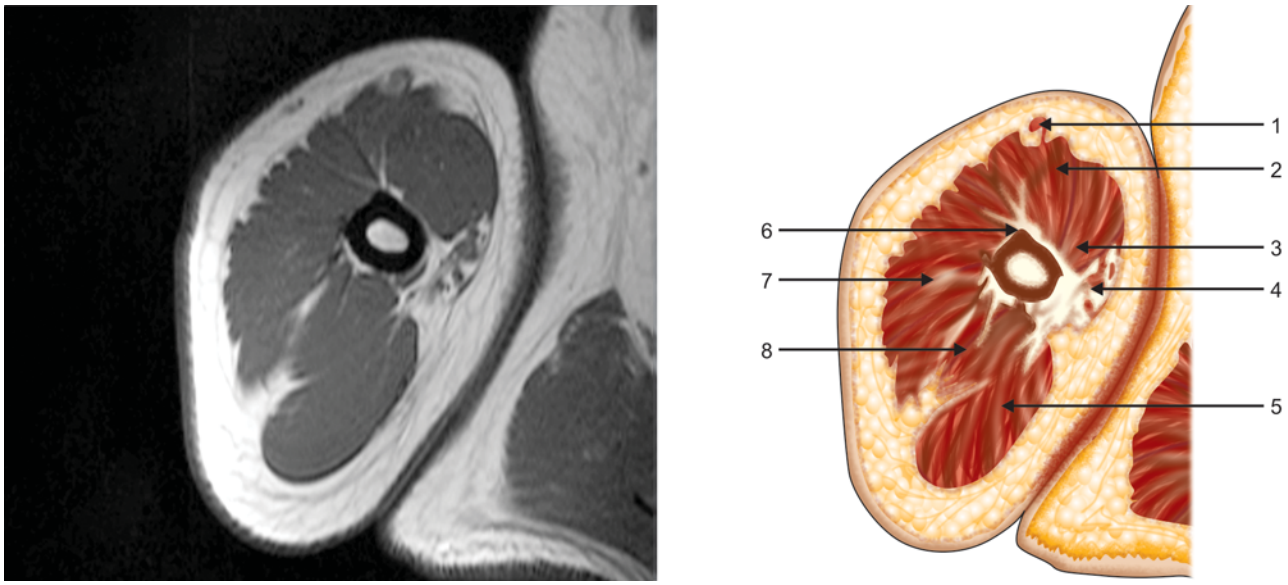

Figure 11.2

1. Cephalic vein
2. Biceps brachii
3. Coracobrachialis
4. Neurovascular bundle
   [Brachial artery, Brachial veins, Median and Ulnar nerves]
5. Triceps, long head
6. Deltoid tuberosity
7. Deltoid
8. Triceps, lateral head

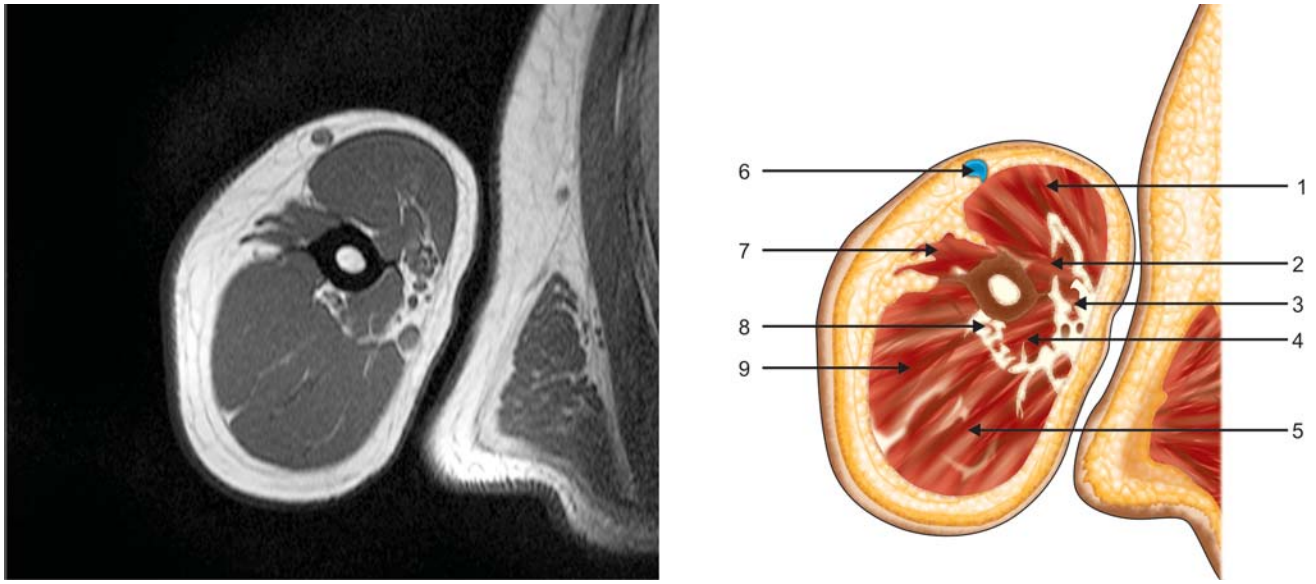

Figure 11.3

1. Biceps brachii
2. Brachialis
3. Neurovascular bundle
4. Triceps, medial head
5. Triceps, long head
6. Cephalic vein
7. Deltoid insertion
8. Radial nerve, deep brachial artery
9. Triceps, lateral head

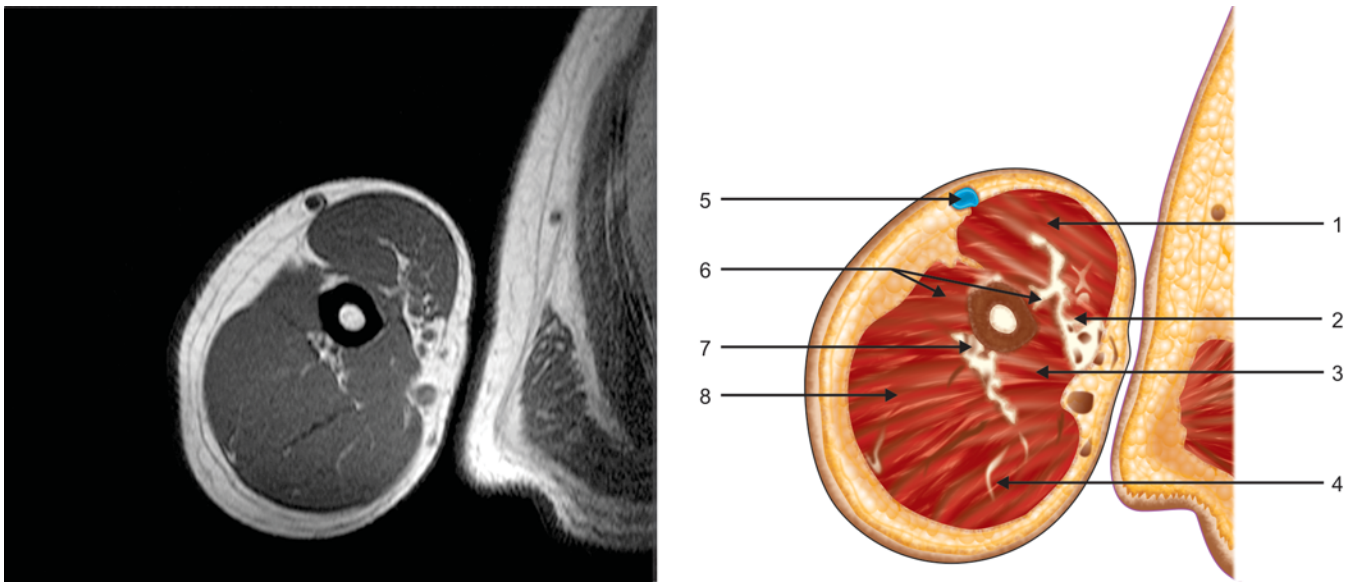

Figure 11.4

1. Biceps brachii
2. Neurovascular bundle
3. Triceps, medial head
4. Triceps, long head
5. Cephalic vein
6. Brachialis
7. Radial nerve, deep brachial artery
8. Triceps, lateral head

FOREARM

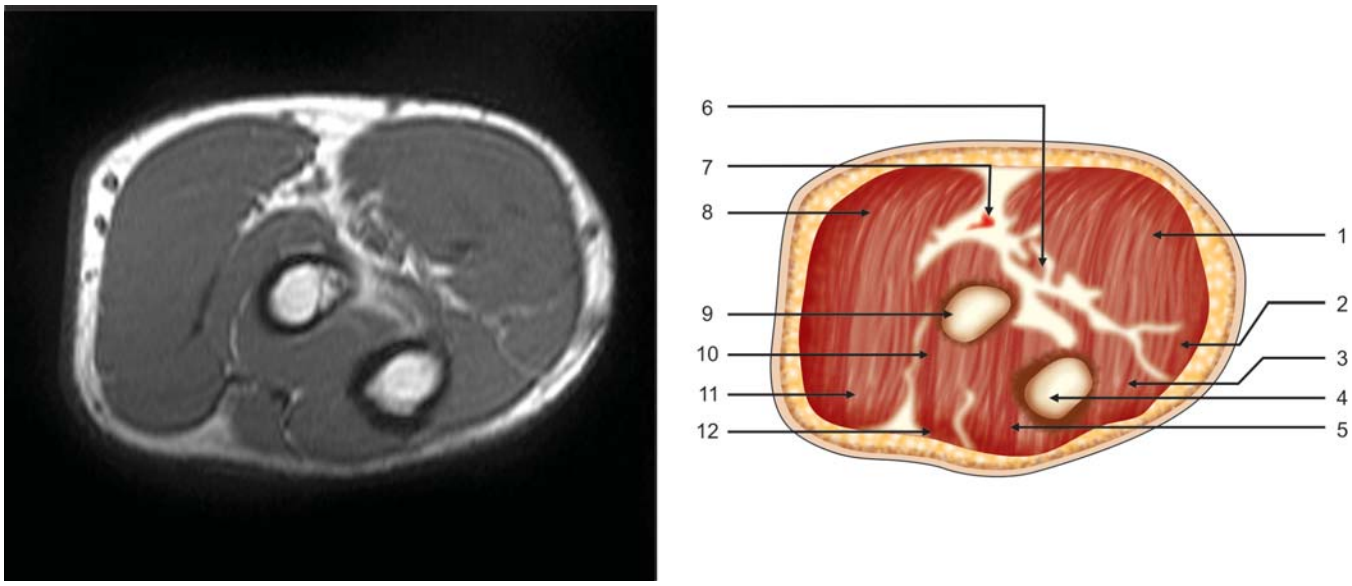

Figure 11.5

1. Flexor digitorum superficialis
2. Flexor carpi ulnaris
3. Flexor digitorum profundus
4. Ulna
5. Extensor carpi ulnaris
6. Ulnar artery, nerve
7. Radial artery
8. Brachioradialis
9. Radius
10. Supinator
11. Extensor carpi radialis brevis
12. Extensor digitorum

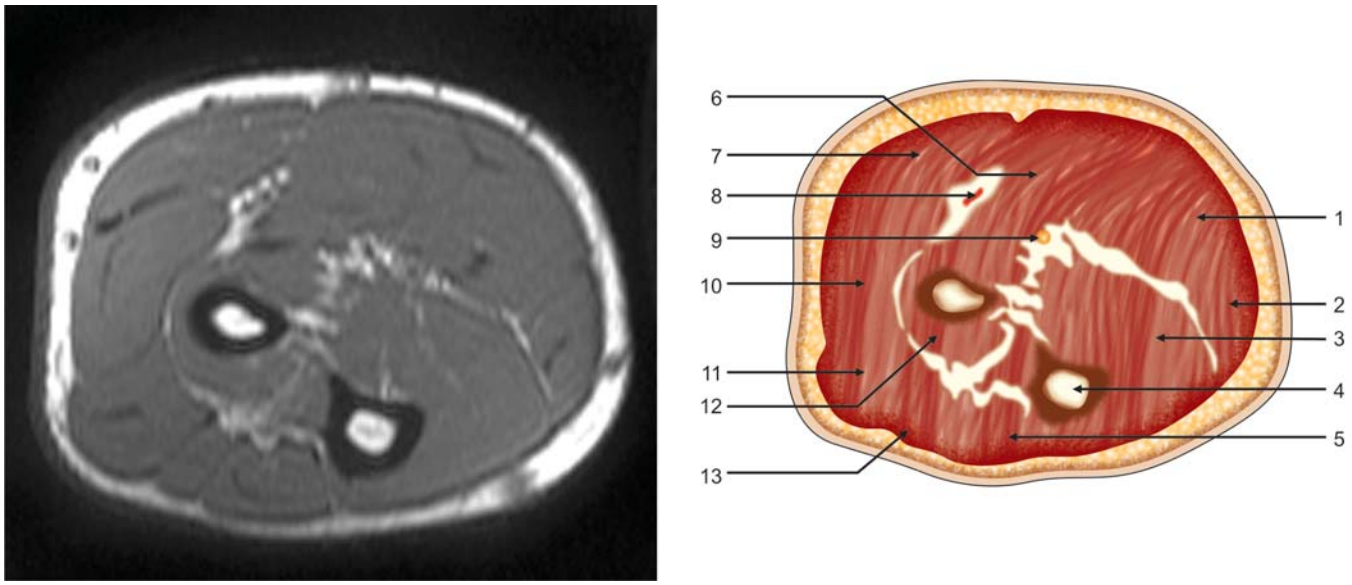

Figure 11.6

1. Flexor digitorum superficialis
2. Flexor carpi ulnaris
3. Flexor digitorum profundus
4. Ulna
5. Extensor carpi ulnaris
6. Flexor carpi radialis
7. Brachioradialis
8. Radial artery
9. Median nerve
10. Extensor carpi longus
11. Extensor carpi radialis brevis
12. Supinator
13. Extensor digitorum

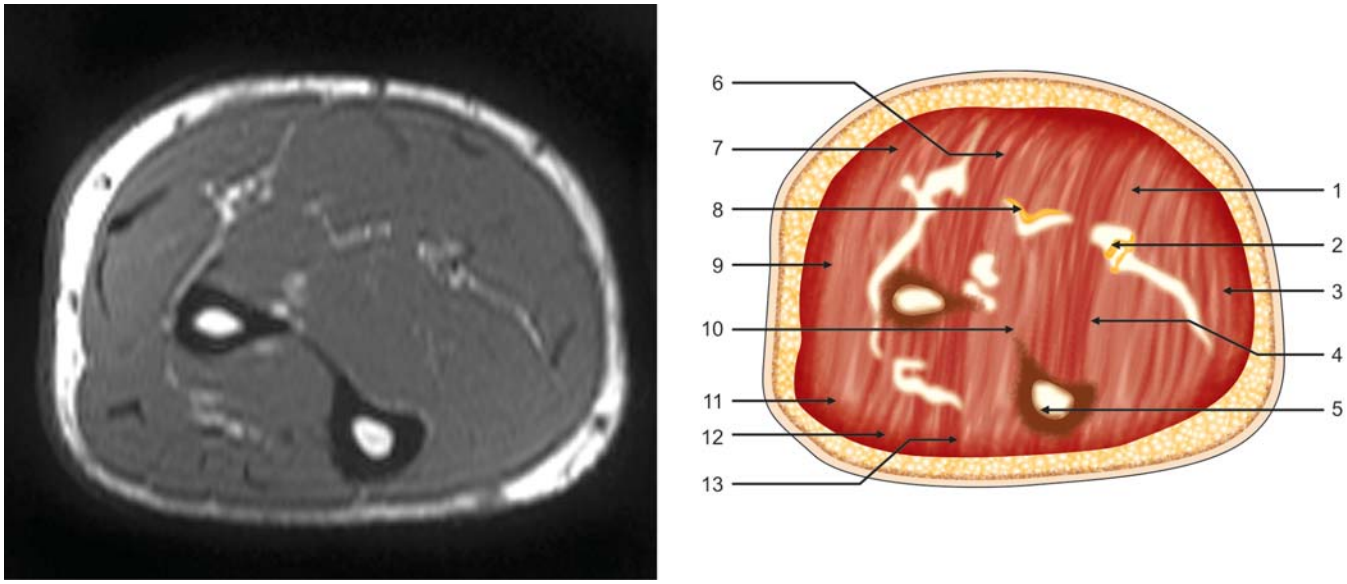

Figure 11.7

1. Flexor digitorum superficialis
2. Ulnar nerve
3. Flexor carpi ulnaris
4. Flexor digitorum profundus
5. Ulna
6. Flexor carpi radialis
7. Brachioradialis
8. Median nerve
9. Extensor carpi radialis longus
10. Interosseous membrane
11. Extensor carpi radialis brevis
12. Extensor digitorum
13. Extensor carpi ulnaris

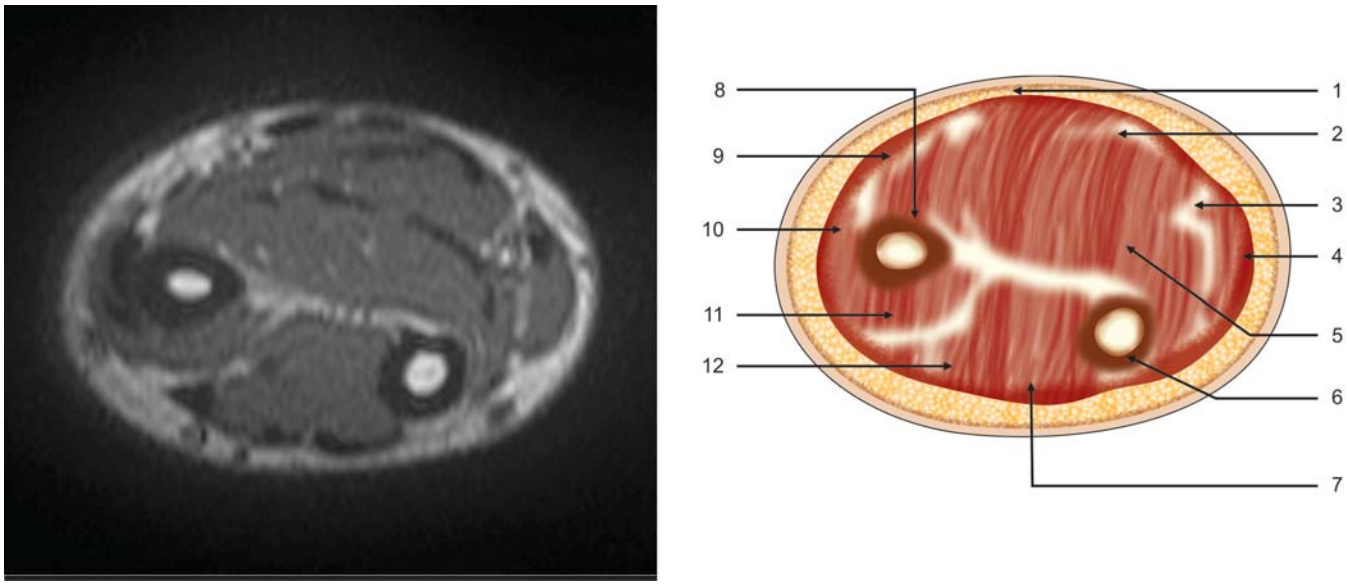

Figure 11.8

1. Palmaris longus
2. Flexor digitorum superficialis
3. Ulnar artery, nerve
4. Flexor carpi ulnaris
5. Flexor digitorum profundus
6. Ulna
7. Extensor carpi ulnaris
8. Radius
9. Radial artery
10. Extensor carpi radialis
11. Abductor pollicis longus
12. Extensor digitorum

CHAPTER 12

Elbow



X-RAY IMAGES



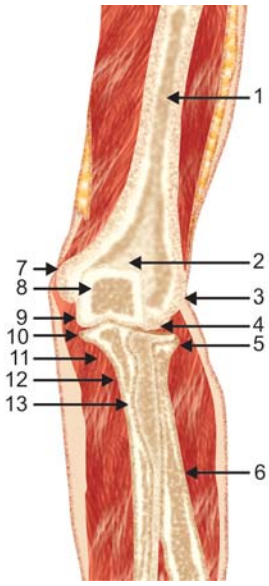

Figure 12.1

1. Humerus
2. Olecranon fossa
3. Lateral epicondyle
4. Capitulum
5. Radius, head
6. Radius
7. Medial epicondyl
8. Olecranon process
9. Trochlea
10. Coronoid process, ulna
11. Muscle
12. Ulna
13. Radial tuberosity



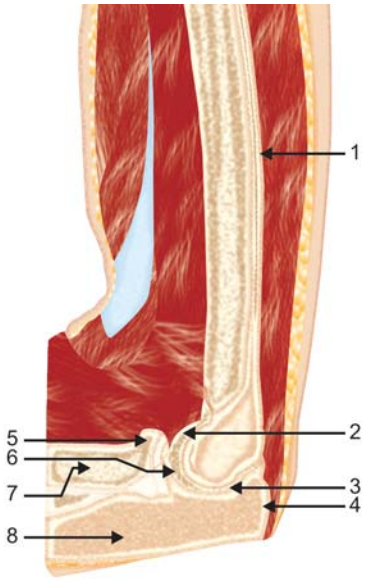

Figure 12.2

1. Humerus
2. Capitulum
3. Trochlear notch
4. Olecranon process
5. Radius, head
6. Coronoid process
7. Radius
8. Ulna

AXIAL VIEWS

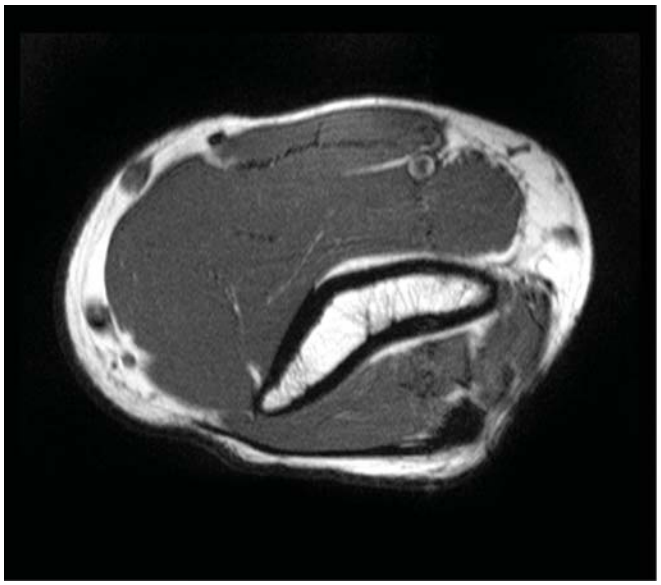

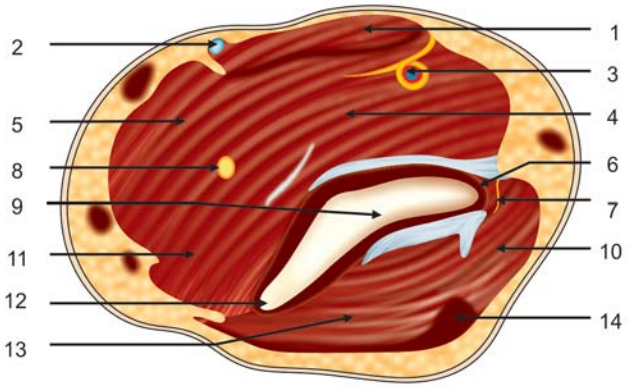

Figure 12.3

1. Biceps brachii
2. Cephalic vein
3. Brachial artery, vein, median nerve
4. Brachialis
5. Brachioradialis
6. Medial supracondylar ridge
7. Ulnar nerve
8. Radial nerve
9. Humerus
10. Triceps, long head
11. Extensor carpi radialis longus
12. Lateral supracondylar ridge
13. Tricep, medial and lateral heads
14. Triceps tendon

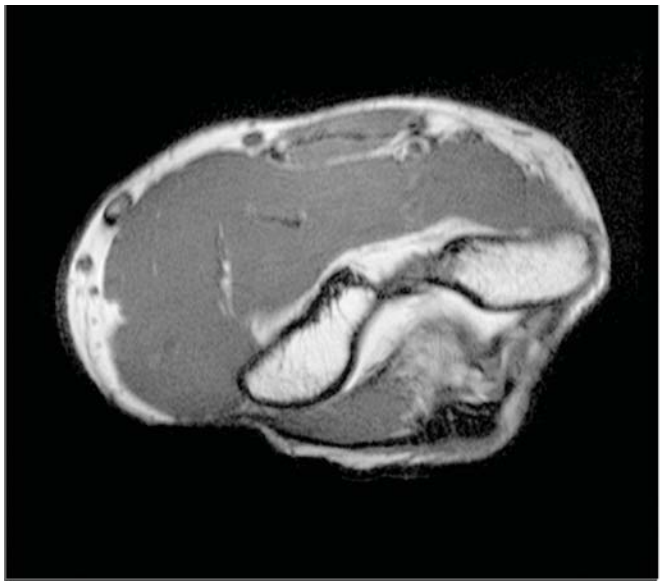

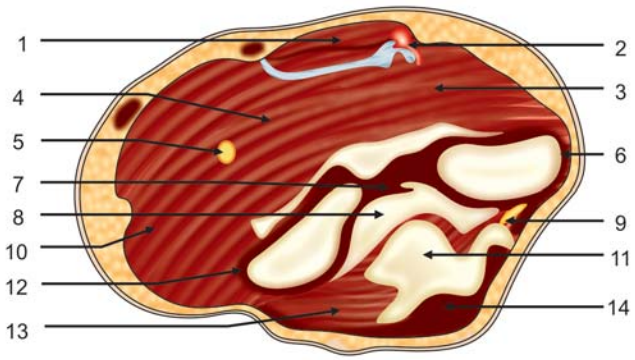

Figure 12.4

1. Biceps brachii
2. Neurovascular bundle (brachial artery, vein, medial nerve)
3. Brachialis
4. Brachioradialis
5. Radial nerve
6. Medial supracondylar ridge
7. Olecranon fossa
8. Post fat pad
9. Ulnar nerve
10. Extensor carpi radialis longus
11. Olecranon process
12. Lateral supracondylar ridge
13. Triceps muscle
14. Triceps tendon

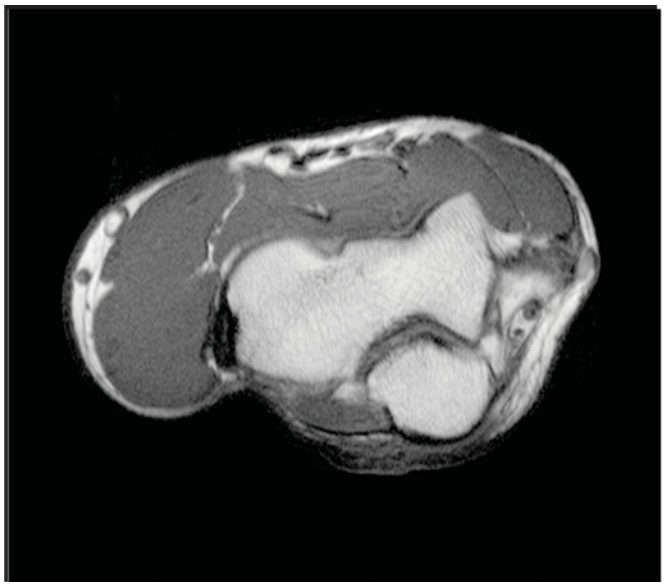

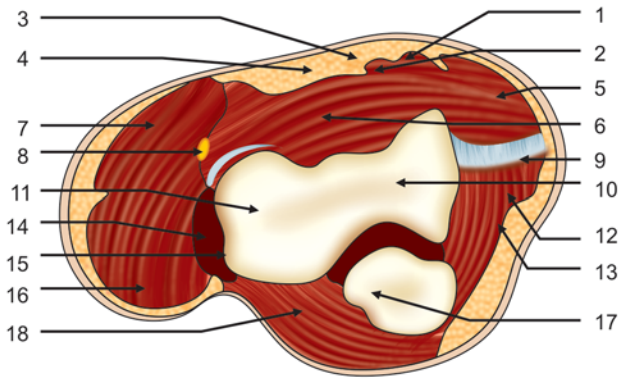

Figure 12.5

1. Median nerve
2. Brachial artery
3. Bicipital aponeurosis
4. Biceps brachii tendon
5. Pronator teres
6. Brachialis
7. Brachioradialis
8. Radial nerve
9. Common flexor tendon
10. Trochlea
11. Capitulum
12. Medial epicondyle
13. Ulnar nerve
14. Common extensor tendon
15. Lateral epicondyle
16. Extensor carpi radialis longus
17. Olecranon process
18. Anconeus

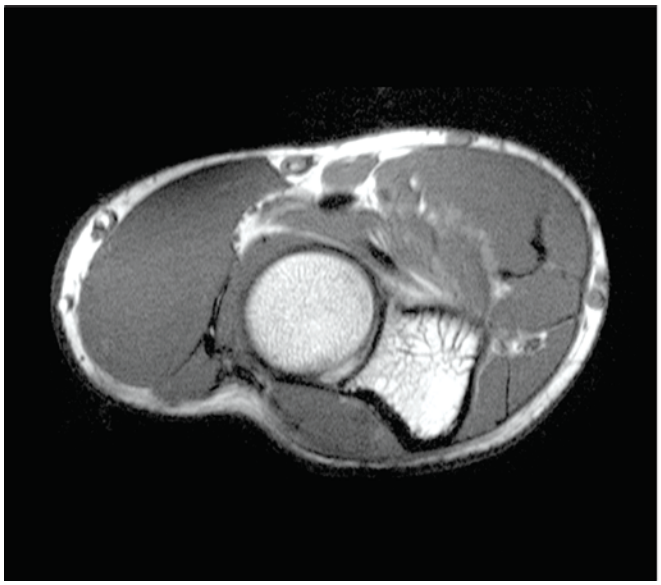

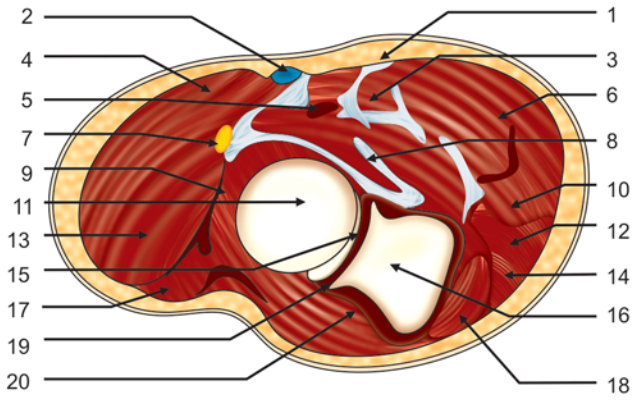

Figure 12.6

1. Bicipital aponeurosis
2. Cephalic vein
3. Brachial artery
4. Brachioradialis
5. Biceps brachii tendon
6. Pronator teres
7. Radial nerve
8. Brachialis muscle and tendon
9. Supinator
10. Palmaris longus
11. Radius, head
12. Ulnar nerve
13. Extensor carpi radialis longus
14. Flexor digitorum superficialis
15. Radial notch
16. Ulna
17. Extensor digitorum
18. Flexor carpi ulnaris
19. Supinator crest
20. Anconeus

CORONAL VIEWS

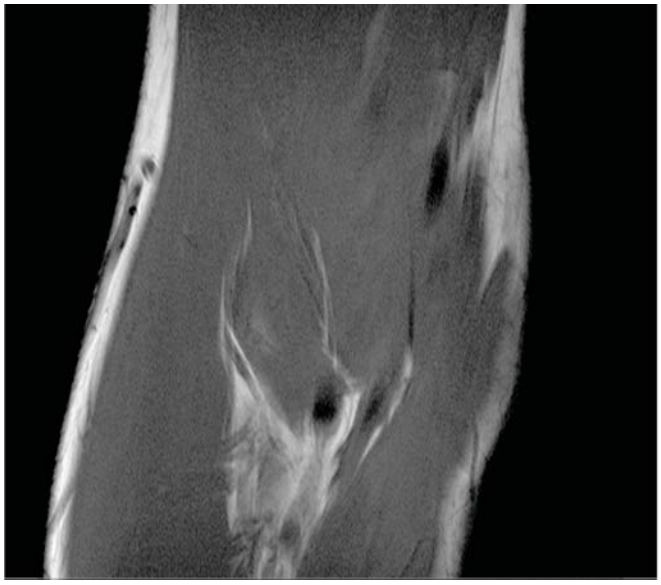

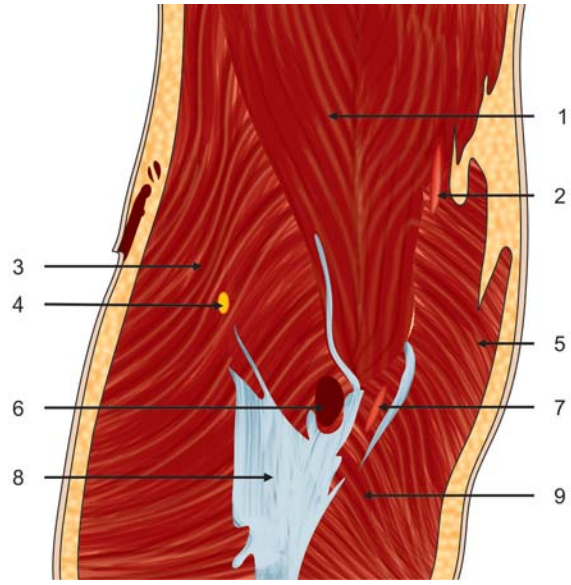

Figure 12.7

1. Brachialis
2. Brachial artery
3. Brachioradialis
4. Radial nerve
5. Pronator teres
6. Biceps tendon
7. Ulnar artery
8. Supinator
9. Flexor carpi radialis



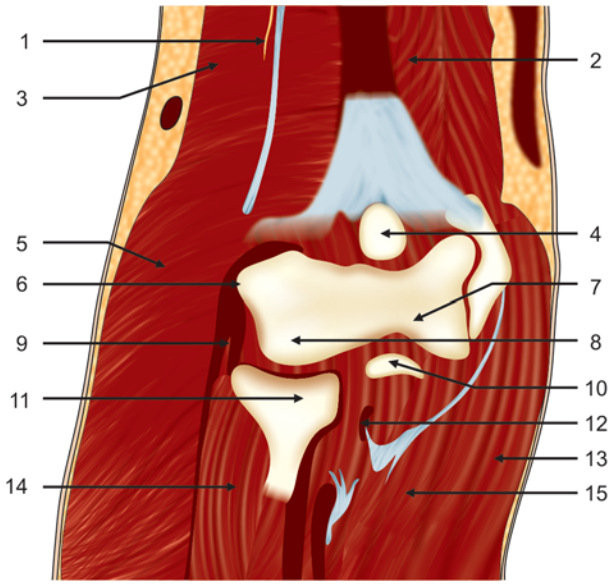

Figure 12.8

1. Radial nerve
2. Brachialis
3. Brachioradialis
4. Olecranon fossa
5. Extensor carpi radialis longus
6. Lateral epicondyle
7. Trochlea
8. Capitulum
9. Common extensor tendon
10. Coronoid process
11. Radius, head
12. Brachialis muscle, tendon
13. Flexor carpi ulnaris
14. Supinator muscle
15. Flexor digitorum superficialis

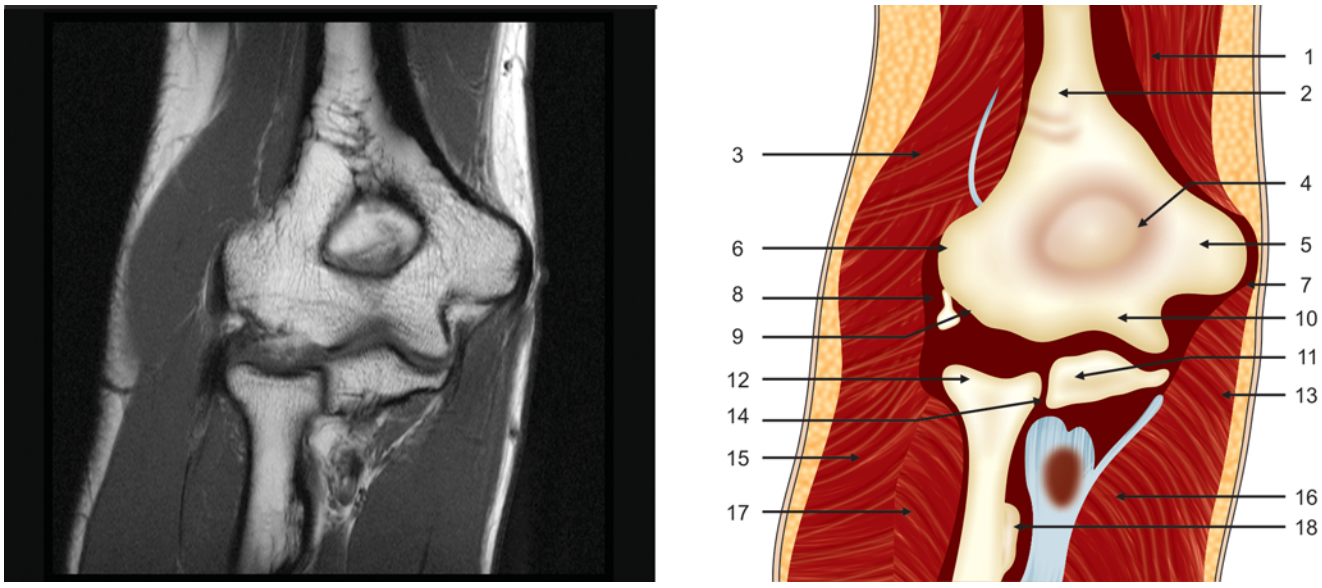

Figure 12.9

1. Triceps
2. Humerus
3. Extensor carpi radialis longus
4. Olecranon fossa
5. Medial epicondyle
6. Lateral epicondyle
7. Common flexor tendon
8. Common extensor tendon
9. Capitulum
10. Trochlea
11. Coronoid process
12. Radius, head
13. Flexor carpi ulnaris
14. Radioulnar joint
15. Extensor carpi radialis brevis
16. Flexor digitorum profundus
17. Supinator
18. Radial tuberosity

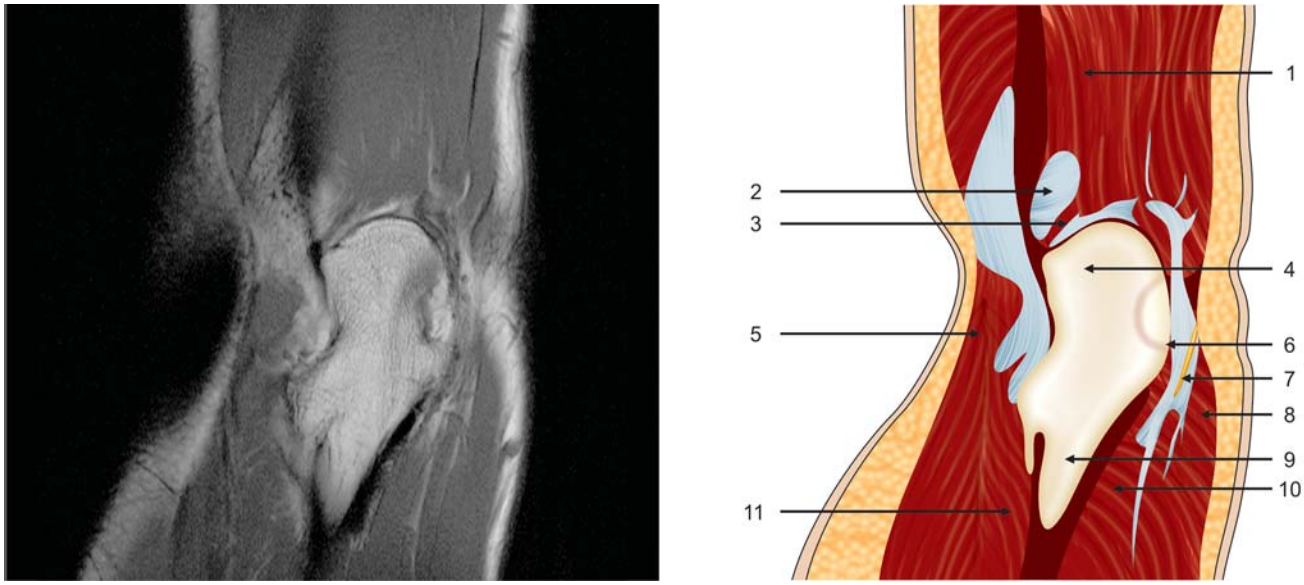

Figure 12.10

1. Triceps
2. Humerus
3. Olecranon fossa
4. Olecranon process
5. Anconeus
6. Coronoid process
7. Ulnar nerve
8. Flexor carpi ulnaris
9. Ulnar shaft
10. Flexor digitorum profundus
11. Extensor muscles

SAGITTAL VIEWS

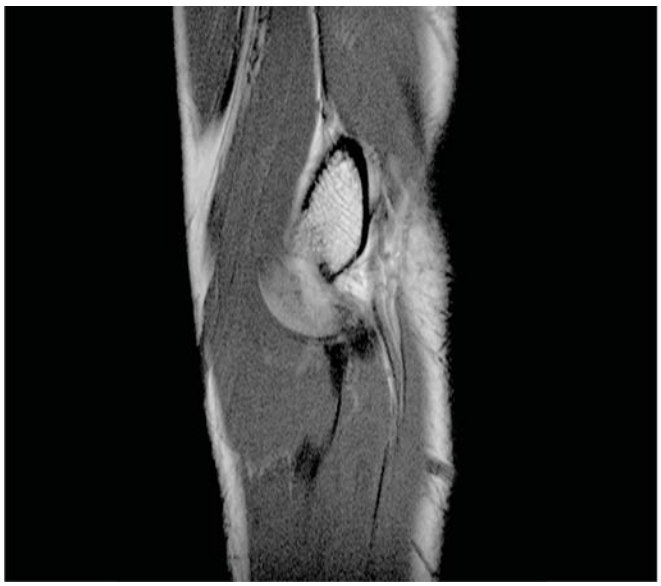

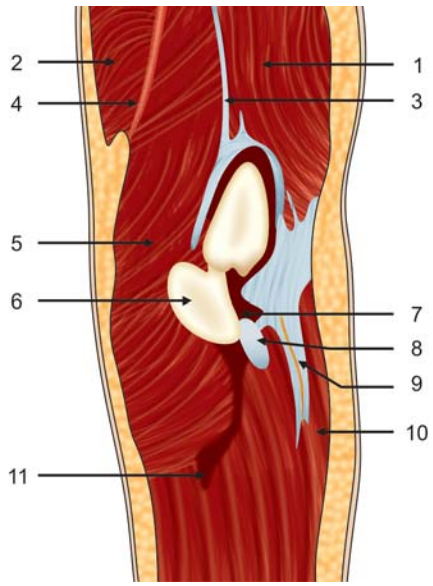

Figure 12.11

1. Triceps
2. Biceps brachii
3. Medial intermuscular septum
4. Brachial artery
5. Brachialis muscle
6. Trochlea
7. Medial epicondyle
8. Common flexor tendon
9. Ulnar nerve
10. Flexor carpi ulnaris
11. Superficial flexor muscles



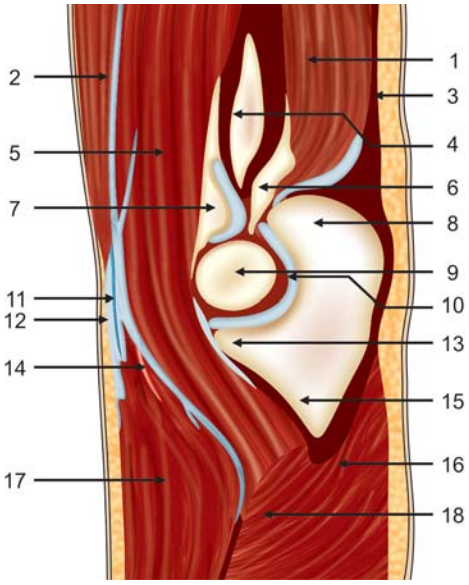

Figure 12.12

1. Triceps
2. Biceps brachii
3. Triceps tendon
4. Humerus
5. Brachialis
6. Olecranon fossa and posterior fat pad
7. Anterior fat pad
8. Olecranon process
9. Trochlea
10. Trochlear notch
11. Cephalic vein
12. Bicipital aponeurosis
13. Coronoid process
14. Brachial artery
15. Ulna
16. Flexor carpi ulnaris
17. Superficial flexor muscles
18. Flexor digitorum profundus

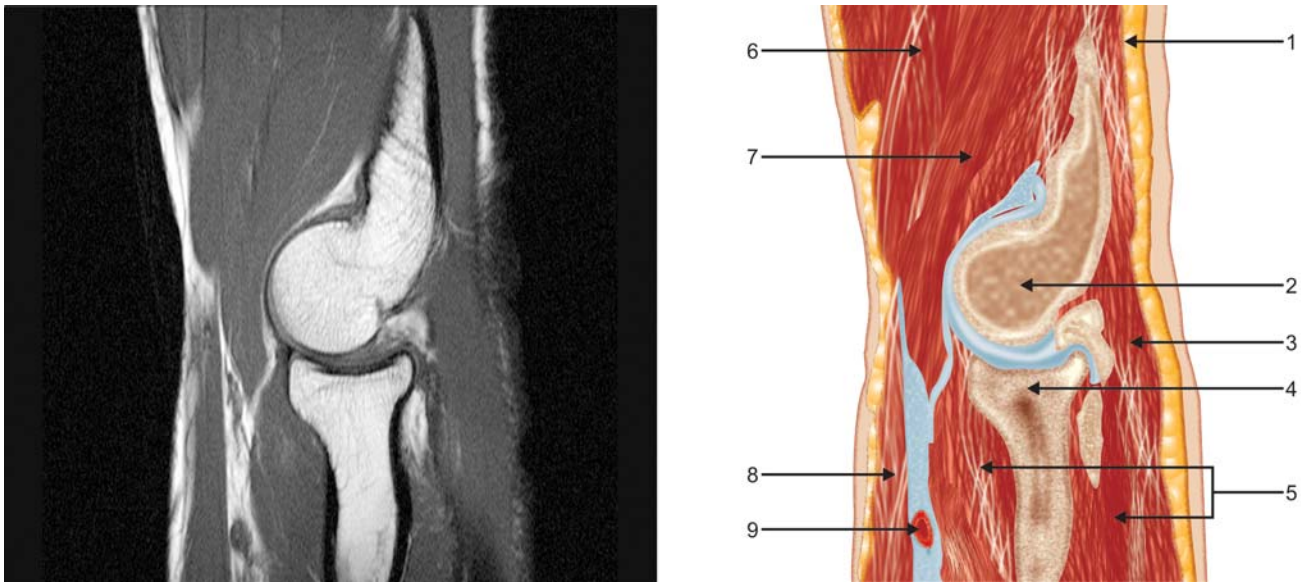

Figure 12.13

1. Triceps
2. Capitulum
3. Anconeus
4. Radius, head
5. Supinator
6. Brachioradialis
7. Extensor carpi radialis longus
8. Brachioradialis
9. Radial artery

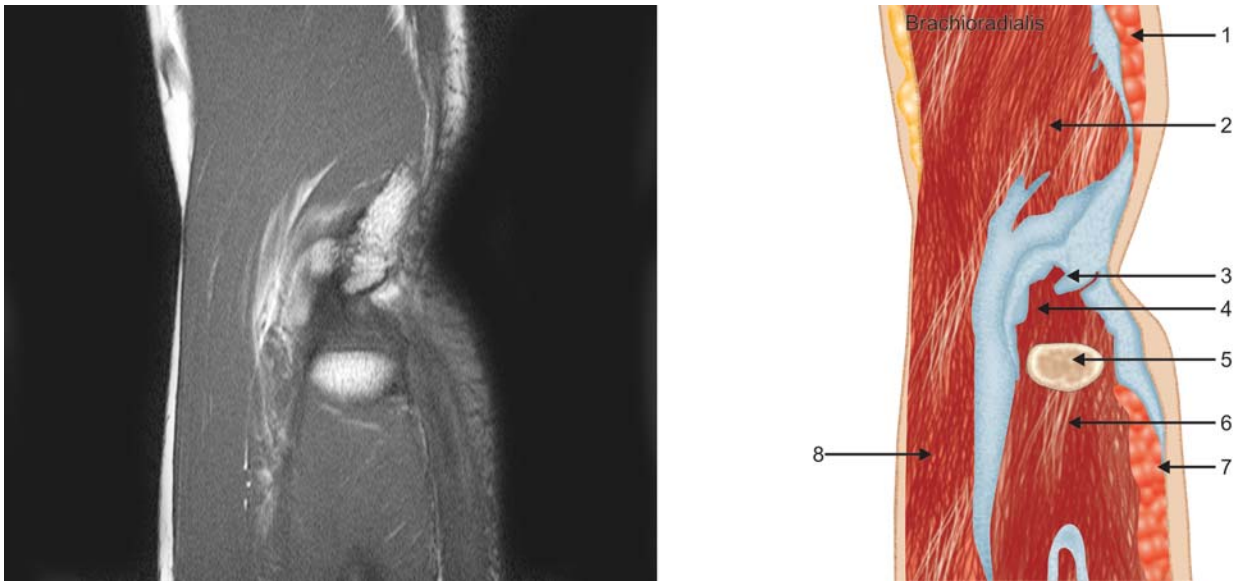

Figure 12.14

1. Triceps
2. Extensor carpi radialis longus
3. Lateral epicondyle
4. Common extensor tendon
5. Radius, head
6. Supinator
7. Extensor digitorum
8. Brachioradialis

CHAPTER 13

Wrist

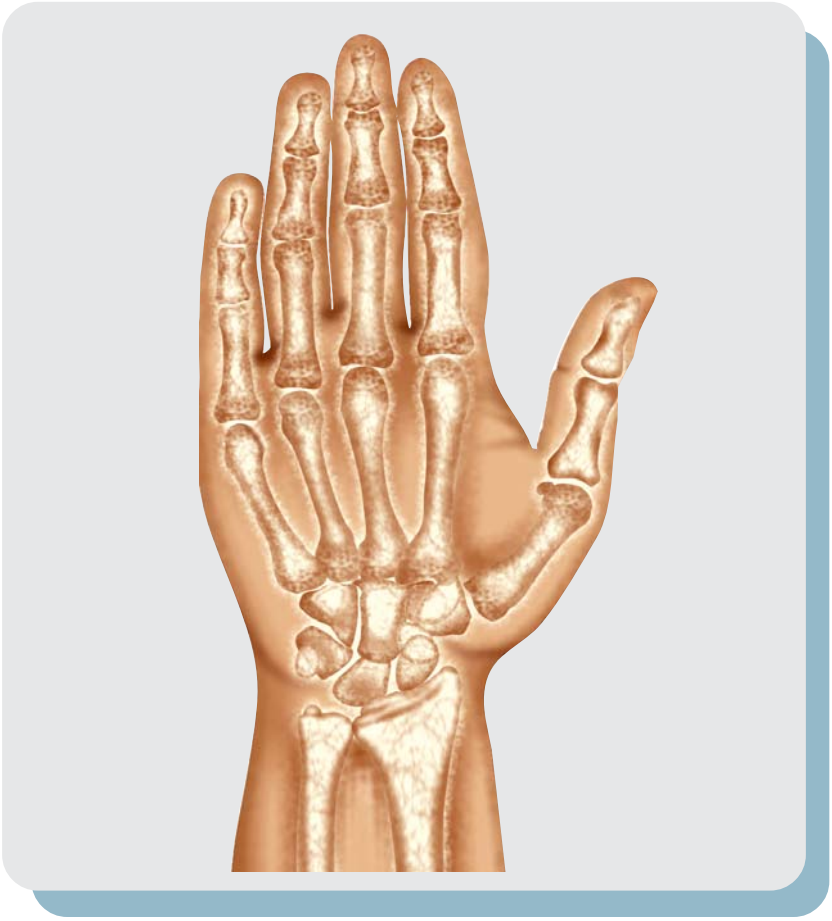

X-RAYS



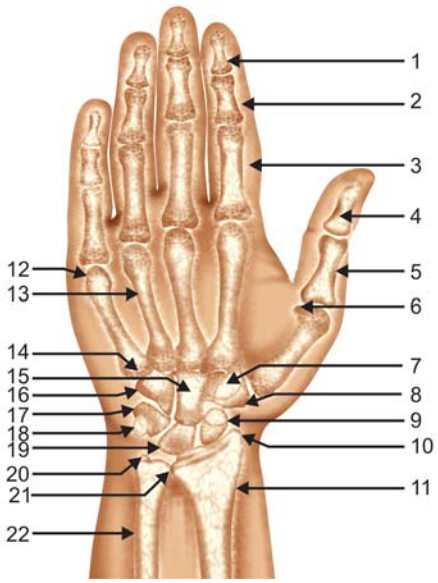

Figure 13.1

1. Distal phalanx
2. Middle phalanx
3. Proximal phalanx
4. Distal phalanx, thumb
5. Proximal phalanx, thumb
6. Sesamoid bone
7. Trapezoid
8. Trapezium
9. Scaphoid
10. Styloid process of radius
11. Radius
12. Head, fifth metacarpal
13. Fourth metacarpal
14. Base, fifth metacarpal
15. Capitate
16. Hamate
17. Triquetral
18. Pisiform
19. Lunate
20. Styloid process of ulna
21. Inferior radioulnar joint
22. Ulna



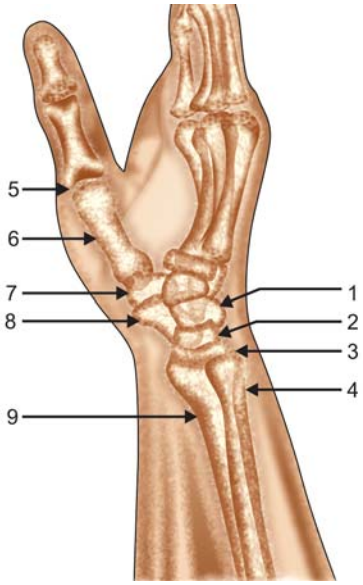

Figure 13.2

1. Capitate
2. Lunate
3. Styloid process
4. Ulna
5. Metacarpophalangeal joint
6. First metacarpal
7. Trapezium
8. Scaphoid
9. Radius

AXIAL IMAGES

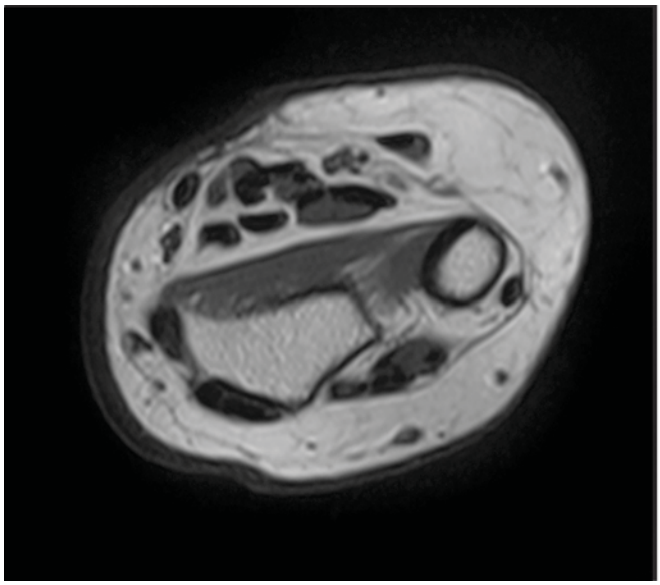

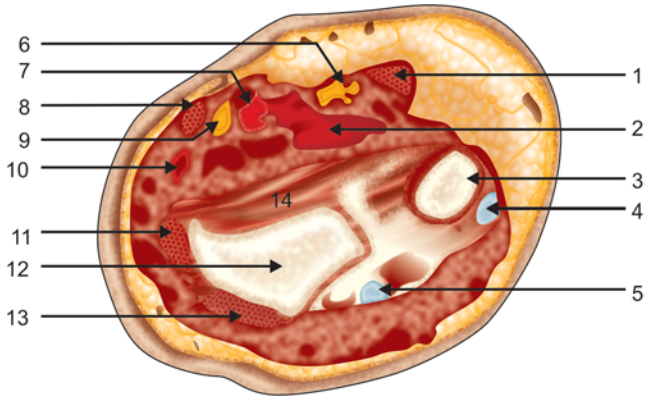

Figure 13.3

1. Flexor carpi ulnaris
2. Flexor digitorum profundus
3. Ulna
4. Extensor carpi ulnaris tendon
5. Extensor digitorum tendons
6. Ulnar artery, nerve
7. Flexor digitorum superficialis
8. Flexor carpi radialis
9. Median nerve
10. Radial artery
11. Abductor pollicis longus
12. Radius
13. Extensor carpi radialis longus, brevis
14. Pronator quadratus

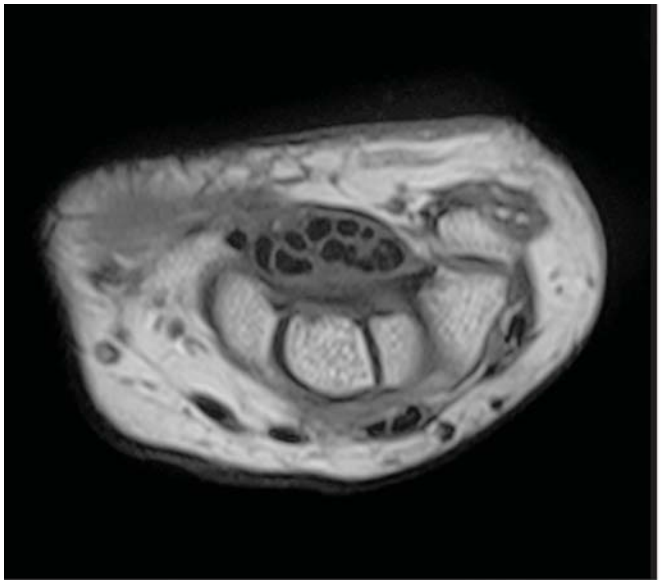

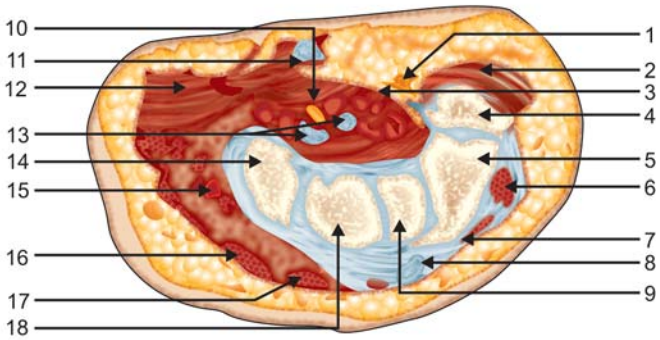

Figure 13.4

1. Ulnar artery, nerve
2. Abductor digiti minimi
3. Flexor retinaculum
4. Pisiform
5. Triquetrum
6. Extensor carpi ulnaris
7. Extensor retinaculum
8. Extensor digitorum tendons
9. Hamate
10. Median nerve
11. Palmaris longus tendon
12. Abductor pollicis brevis
13. Flexor digitorum tendons
14. Scaphoid
15. Radial artery
16. Extensor carpi radialis longus, brevis
17. Extensor pollicis longus
18. Capitate

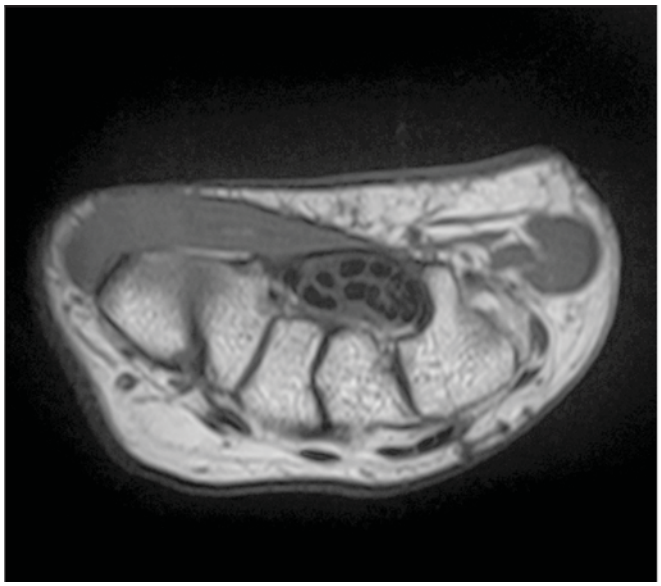

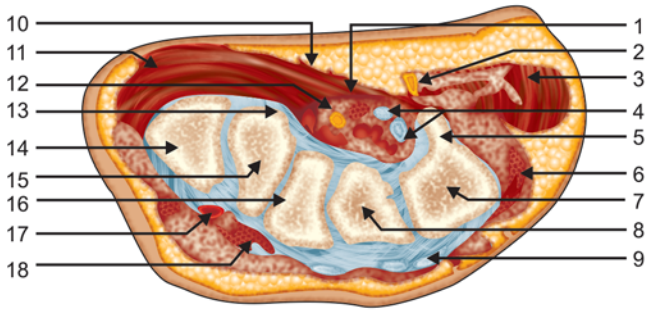

Figure 13.5

1. Flexor retinaculum
2. Ulnar nerve
3. Abductor digiti minimi
4. Flexor tendons
5. Hook of Hamate
6. Extensor carpi ulnaris
7. Hamate
8. Capitate
9. Extensor tendons
10. Palmar aponeurosis
11. Abductor pollicis brevis
12. Median nerve
13. Tubercle of trapezium
14. First metacarpal, base
15. Trapezium
16. Trapezoid
17. Radial artery
18. Extensor carpi radialis longus, brevis

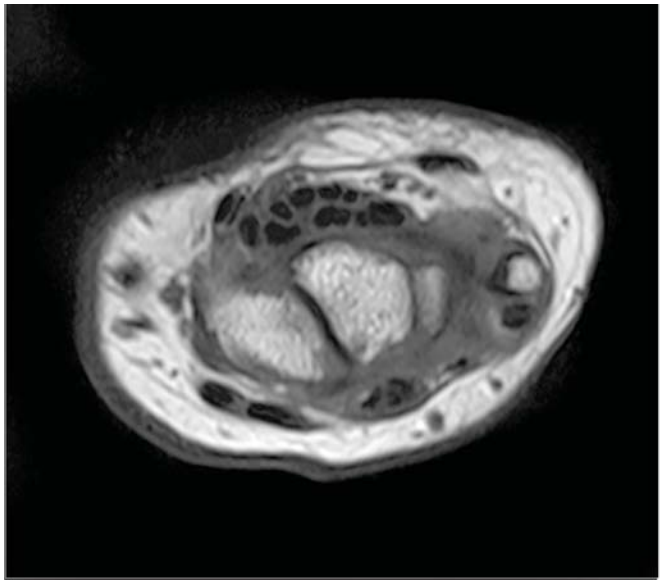

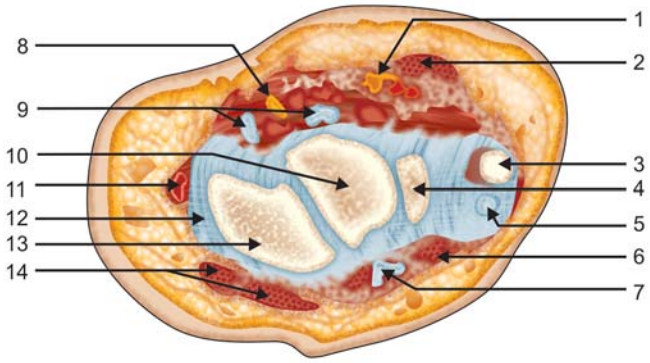

Figure 13.6

1. Ulnar nerve, artery
2. Flexor carpi ulnaris
3. Ulnar styloid
4. Triquetrum
5. Extensor carpi ulnaris tendon
6. Extensor retinaculum
7. Extensor tendons
8. Median nerve
9. Flexor digitorum tendons
10. Lunate
11. Radial artery
12. Abductor pollicis longus
13. Scaphoid
14. Extensor carpi radialis longus, brevis



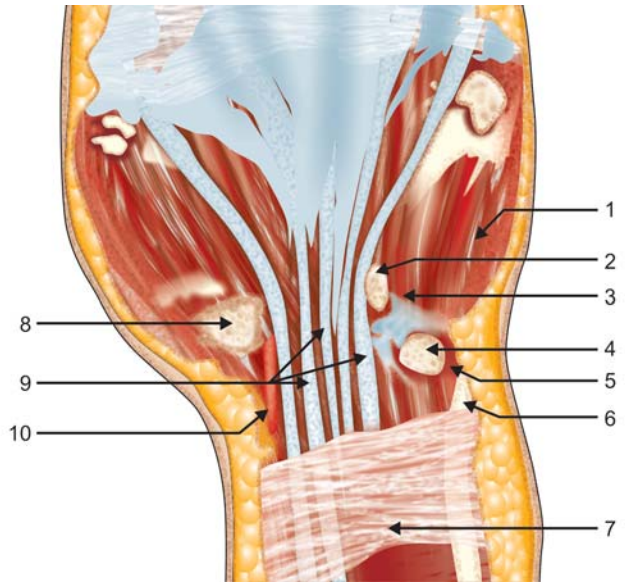

Figure 13.7

1. Abductor digiti minimi
2. Hook of hamate
3. Pisohamate ligament
4. Pisiform
5. Flexor carpi ulnaris (insertion)
6. Ulna
7. Pronator quadratus
8. Trapezium, tubercle
9. Flexor digitorum profundus and superficialis tendons
10. Radial artery

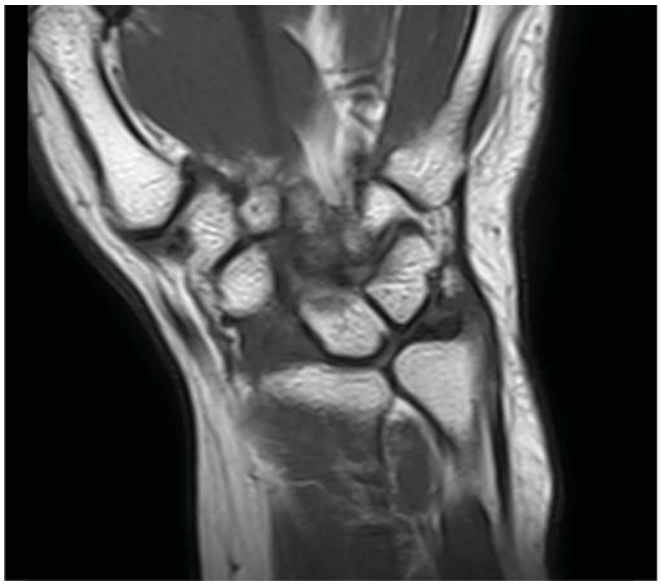

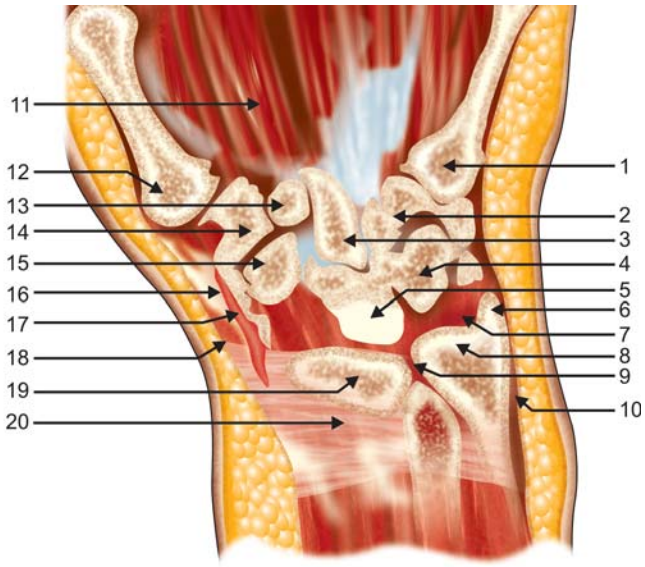

Figure 13.8

1. Fifth metacarpal base
2. Hamate
3. Capitate
4. Triquetrum
5. Lunate
6. Ulnar styloid
7. Triangular fibrocartilage
8. Ulna
9. Distal radioulnar joint
10. Extensor carpi ulnaris tendon
11. Abductor pollicis, oblique head
12. First metacarpal base
13. Trapezoid
14. Trapezium
15. Scaphoid, distal pole
16. Snuff box
17. Radial artery
18. Extensor pollicis brevis and abductor pollicis longus tendons
19. Radius
20. Pronator quadratus

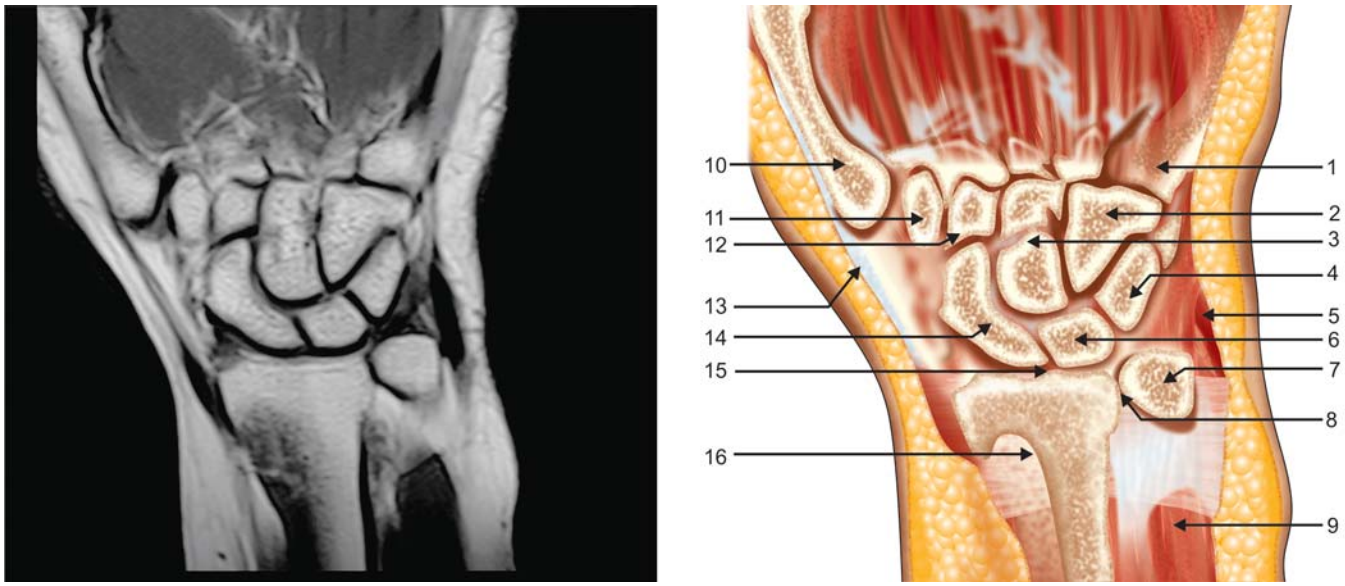

Figure 13.9

1. Fifth metacarpal base
2. Hamate
3. Capitate
4. Triquetrum
5. Extensor carpi ulnaris tendon
6. Lunate
7. Ulna
8. Distal radioulnar joint
9. Pronator quadratus
10. First metacarpal
11. Trapezium
12. Trapezoid
13. Extensor pollicis brevis and abductor pollicis longus tendons
14. Scaphoid
15. Scapholunate ligament
16. Radius

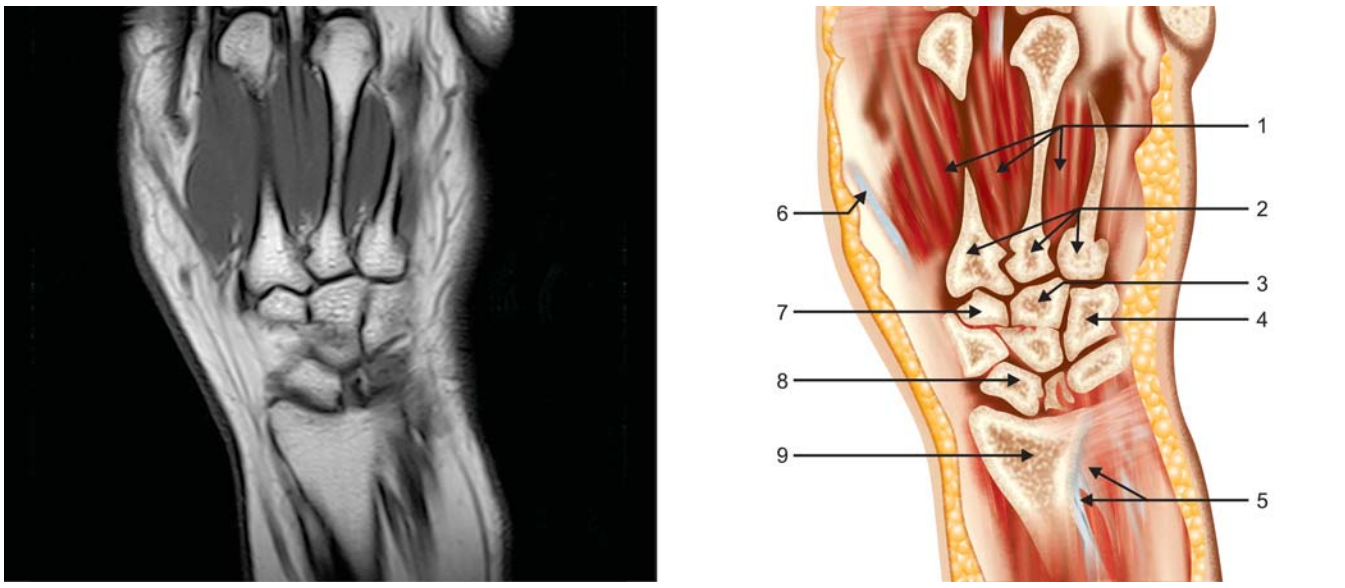

Figure 13.10

1. Interosseous muscles
2. Second, third, fourth metacarpals
3. Capitate
4. Hamate
5. Extensor tendons
6. Extensor pollicis longus
7. Trapezoid
8. Scaphoid, proximal pole
9. Radius



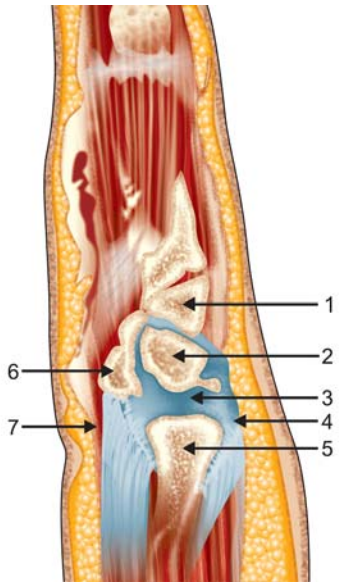

Figure 13.11

1. Hamate
2. Triquetrum
3. Triangular fibrocartilage
4. Extensor carpi ulnaris
5. Ulna
6. Pisiform
7. Flexor carpi ulnaris

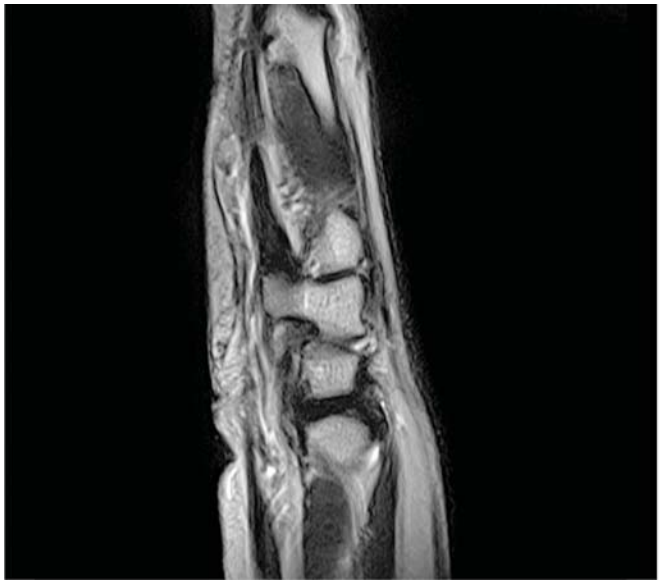

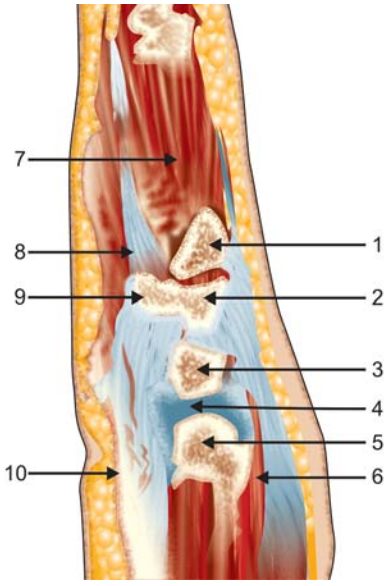

Figure 13.12

1. Fourth metacarpal base
2. Hamate
3. Triquetrum
4. Triangular fibrocartilage
5. Ulna, head
6. Extensor carpi ulnaris
7. Interosseous muscle
8. Flexor tendons
9. Hook of hamate
10. Flexor carpi ulnaris

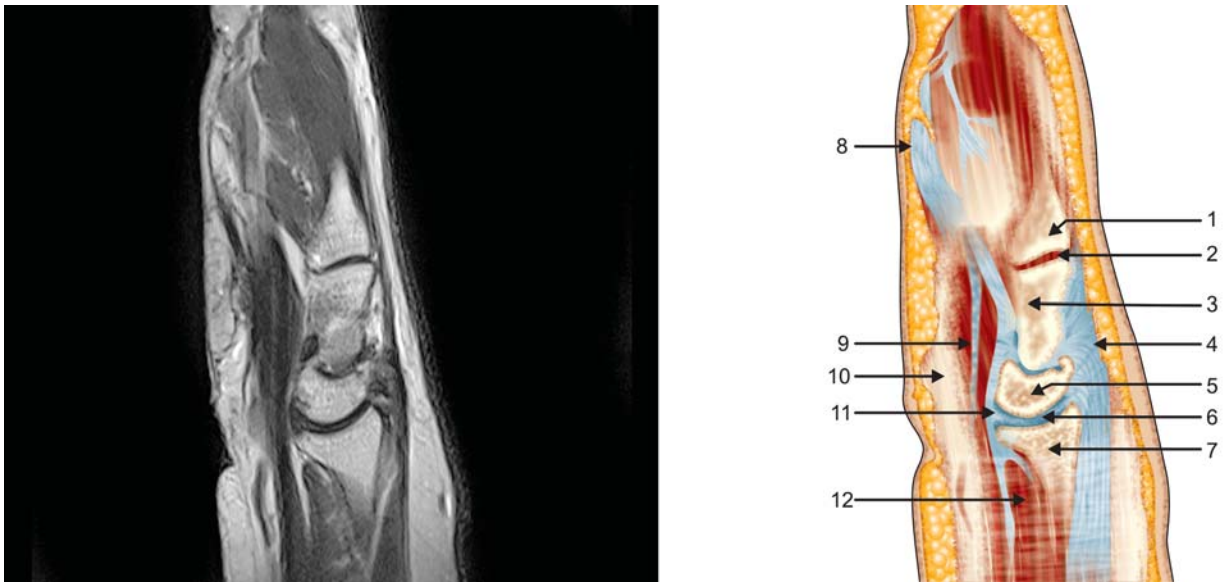

Figure 13.13

1. Third metacarpal base
2. Carpometacarpal joint
3. Capitate
4. Extensor digitorum tendon
5. Lunate
6. Radiocarpal joint
7. Radius
8. Palmar aponeurosis
9. Flexor tendon
10. Flexor retinaculum
11. Palmar radiocarpal ligament
12. Pronator quadratus

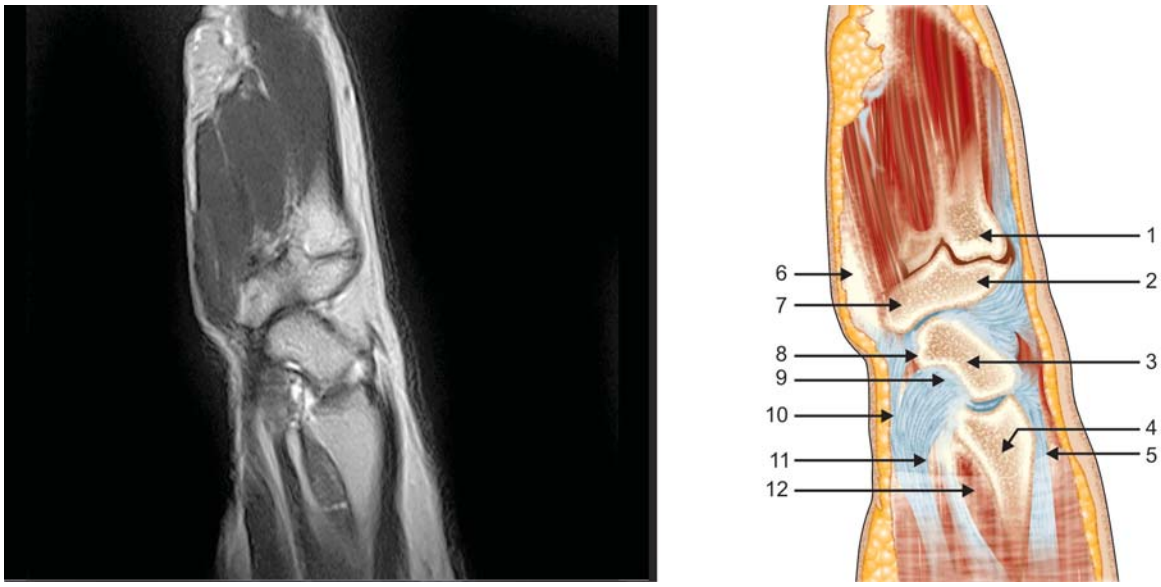

Figure 13.14

1. Second metacarpal, base
2. Trapezoid
3. Scaphoid
4. Radius
5. Extensor pollicis longus tendon
6. Thenar muscle
7. Trapezium
8. Scaphoid tuberosity
9. Palmar radiocarpal ligaments
10. Flexor carpi radialis tendon
11. Flexor pollicis longus tendon
12. Pronator quadratus

CHAPTER 14

Upper Extremity Vessels

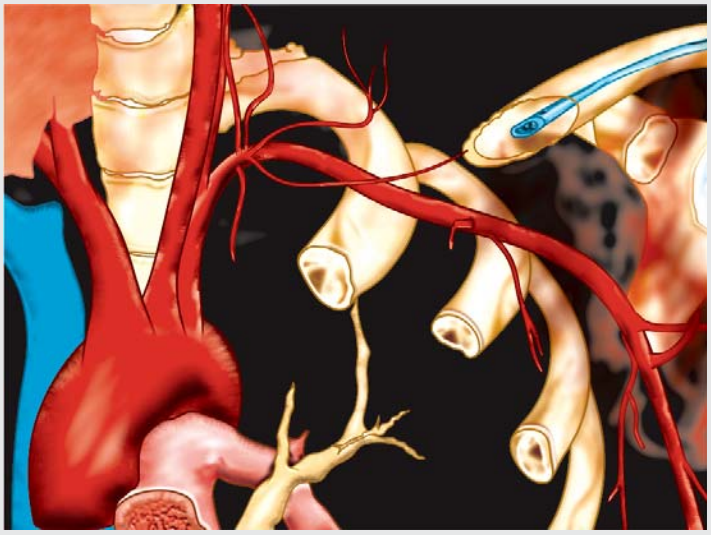

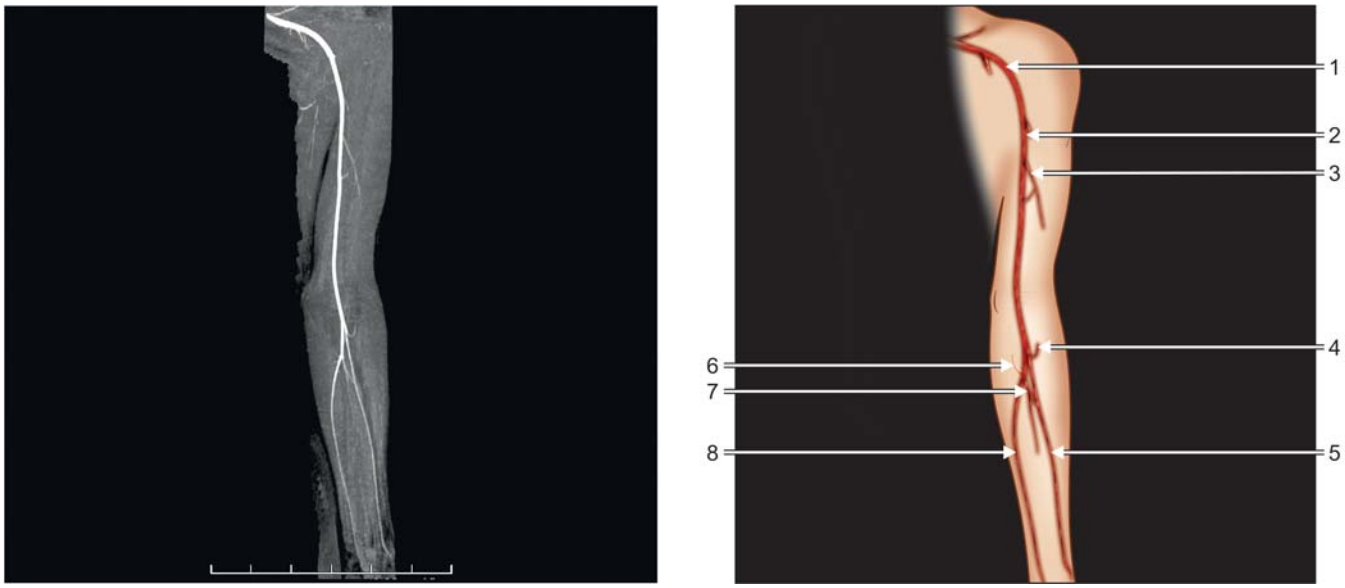

Figure 14.1

1. Axillary artery
2. Brachial artery
3. Profunda brachii artery
4. Radial recurrent artery
5. Radial artery
6. Ulnar recurrent artery
7. Common interosseous artery
8. Ulnar artery

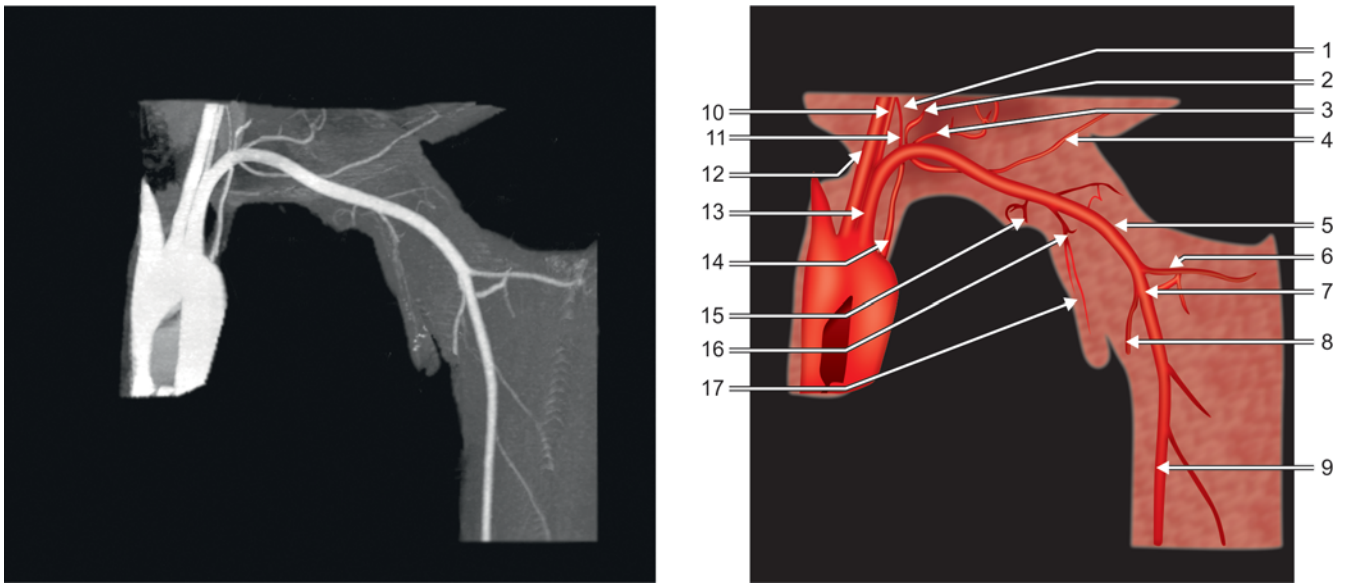

Figure 14.2

1. Inferior thyroid artery
2. Transverse cervical artery
3. Costocervical trunk
4. Supracapsular artery
5. Axillary artery
6. Ant circumflex humeral artery
7. Post circumflex humeral artery
8. Subscapular artery
9. Brachial artery
10. Vertebral artery
11. Thyrocervical trunk
12. Left carotid artery
13. Left subclavian artery
14. Internal mammary artery
15. Superior thoracic artery
16. Thoracoacromial artery
17. Lateral thoracic artery

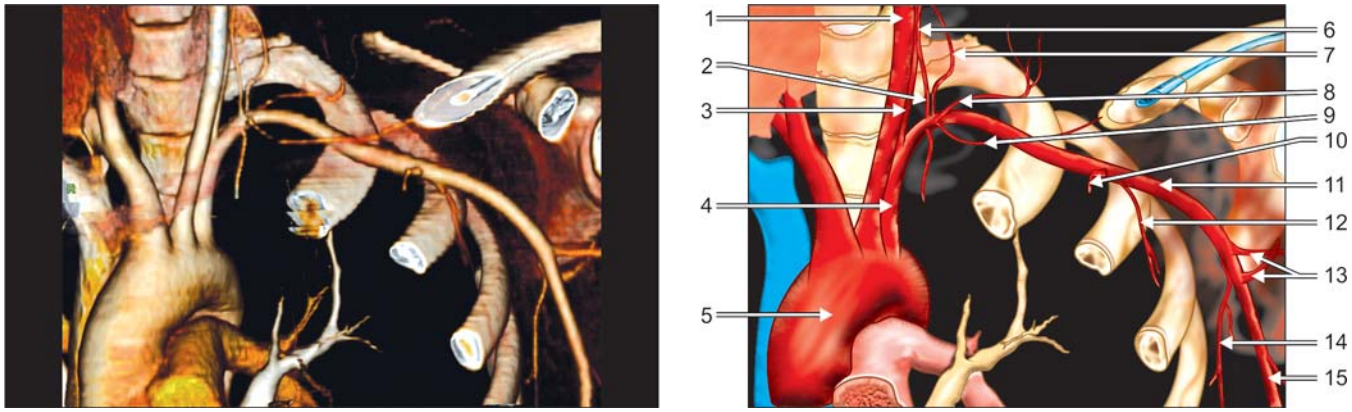

Figure 14.3

1. Left carotid artery
2. Thyrocervical trunk
3. Left vertebral artery
4. Left subclavian artery
5. Arch of aorta
6. Inferior thyroid artery
7. Transverse cervical artery
8. Costocervical trunk
9. Suprascapular artery
10. Superior thoracic artery
11. Axillary artery
12. Lateral thoracic artery
13. Circumflex humeral arteries
14. Subscapular artery
15. Brachial artery

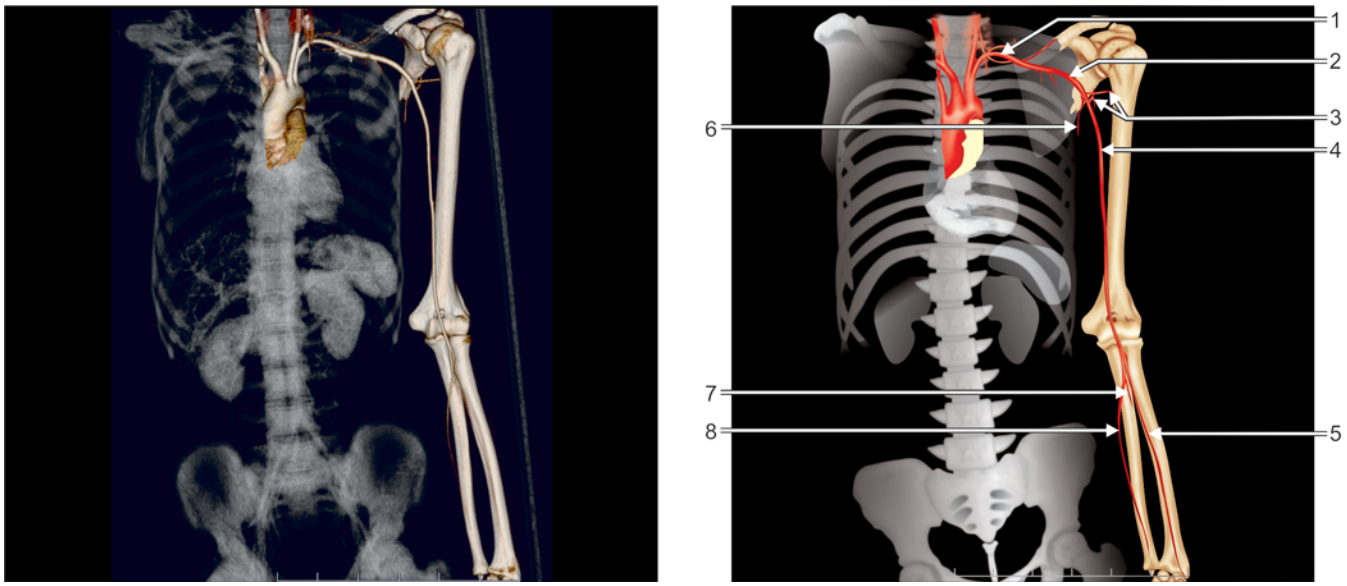

Figure 14.4

1. Subclavian artery
2. Axillary artery
3. Circumflex humeral artery
4. Brachial artery
5. Radial artery
6. Subscapular artery
7. Interosseous artery
8. Ulnar artery

Section 5

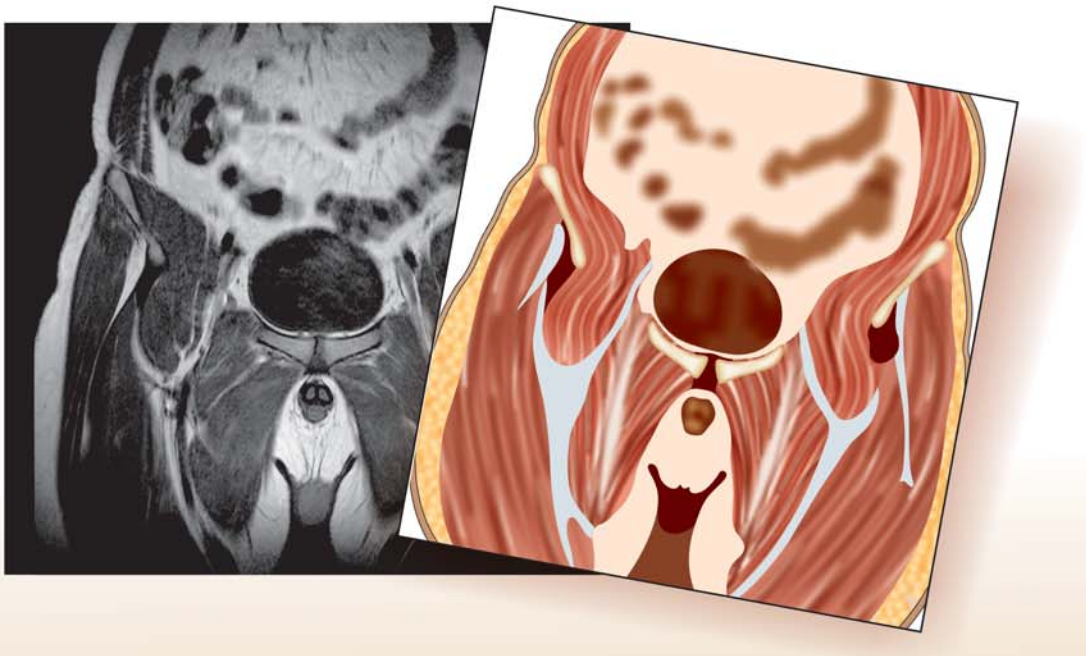

Lower Extremity

- **Hips**
- **Thigh and Calf**
- **Knee**
- **Ankle and Foot**
- **Lower Extremity Vessels**

CHAPTER 15

Hips

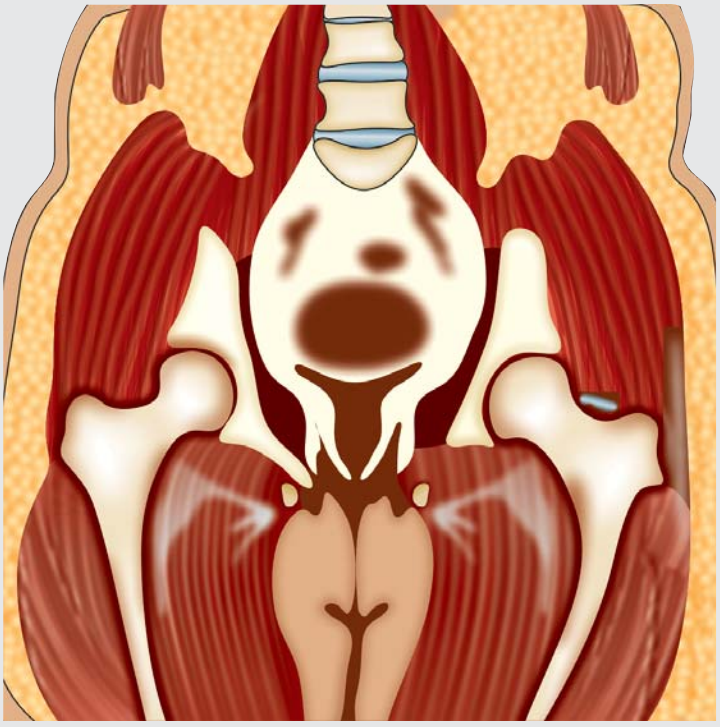

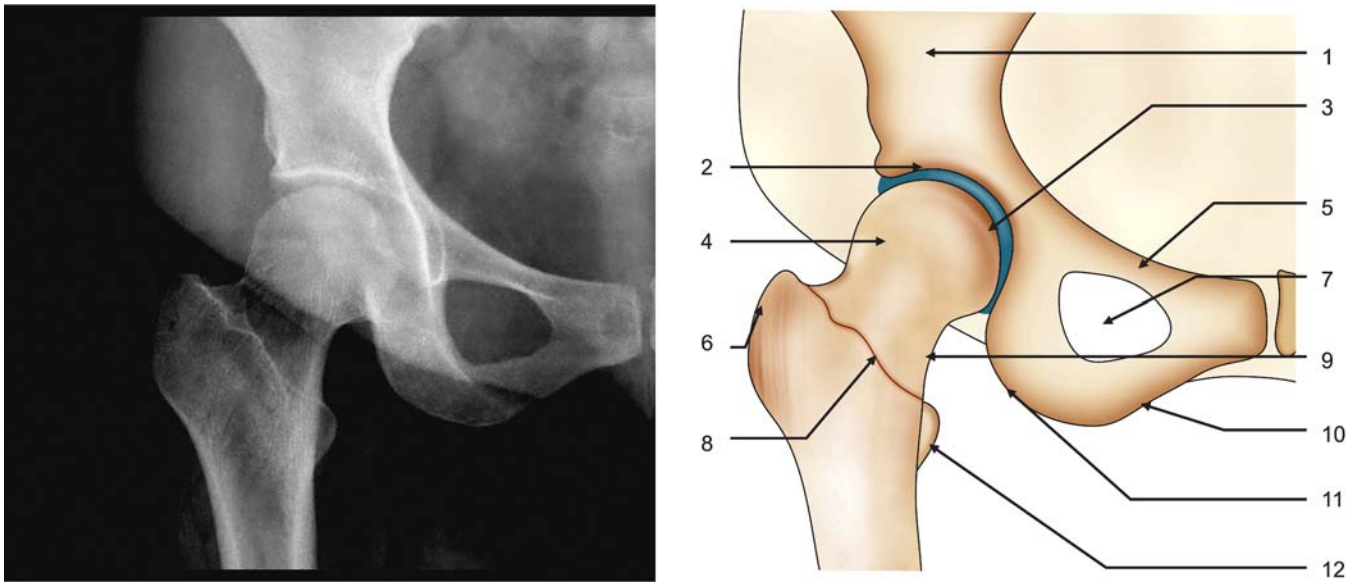

Figure 15.1

1. Ilium
2. Acetabulum
3. Fovea capitis
4. Femoral head
5. Superior pubic ramus
6. Greater trochanter
7. Obturator foramen
8. Intertrochanteric line
9. Femoral neck
10. Inferior pubic ramus
11. Ischial tuberosity
12. Lesser trochanter

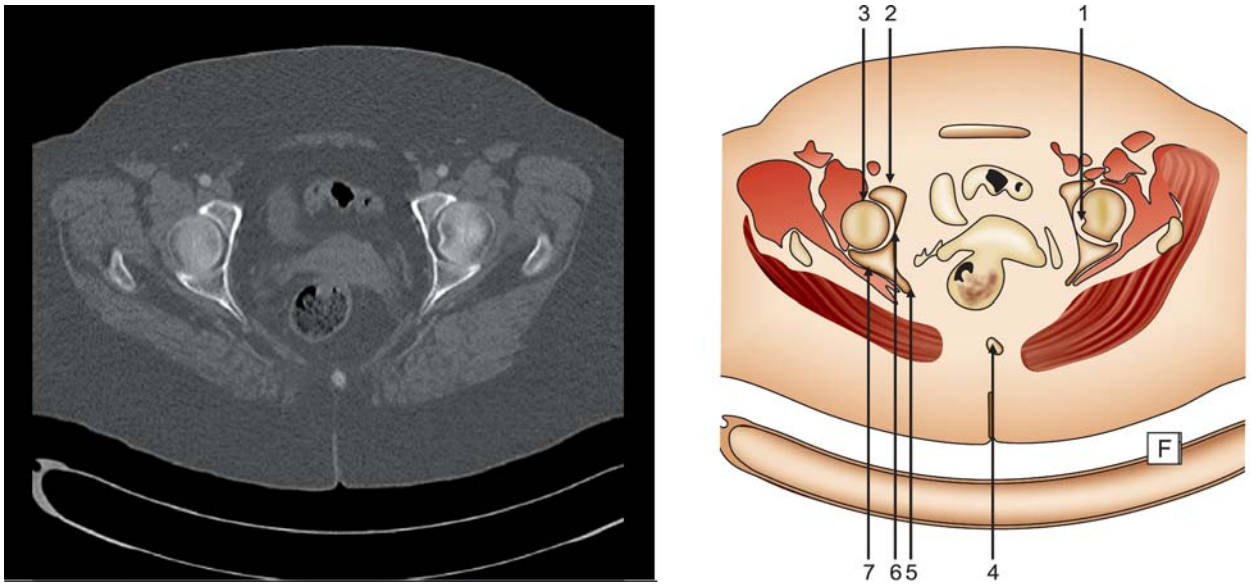

Figure 15.2

1. Fovea capitis
2. Anterior pillar acetabulum
3. Femoral head
4. Coccyx
5. Ischial spine
6. Quadrilateral plate
7. Posterior pillar acetabulum

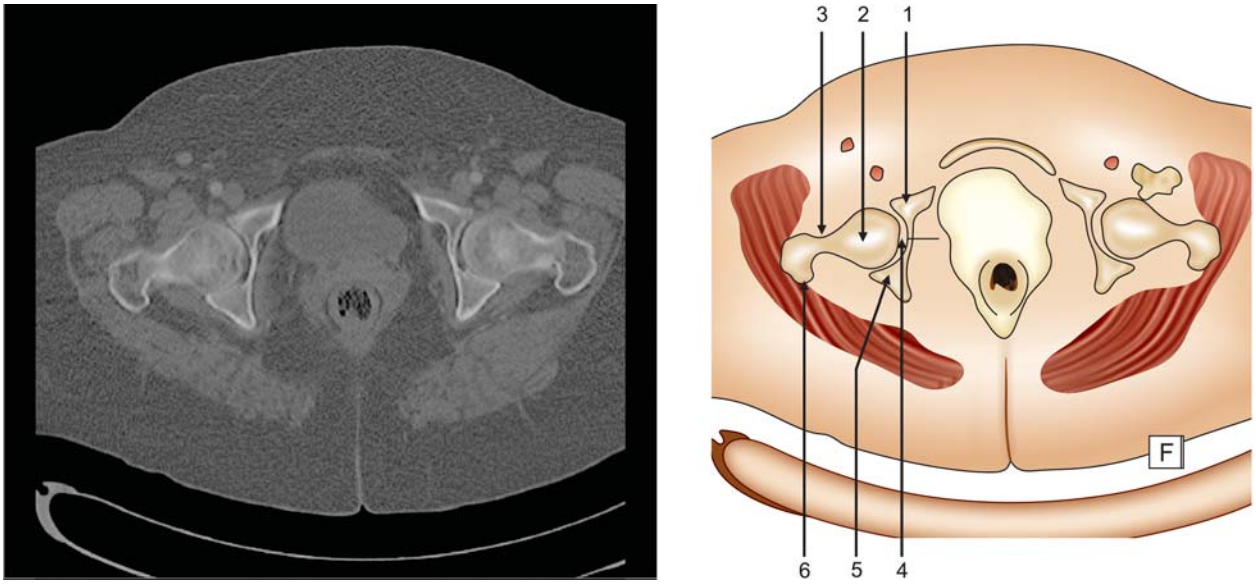

Figure 15.3

1. Acetabulum
2. Femoral head
3. Neck
4. Joint space
5. Ischium
6. Greater trochanter

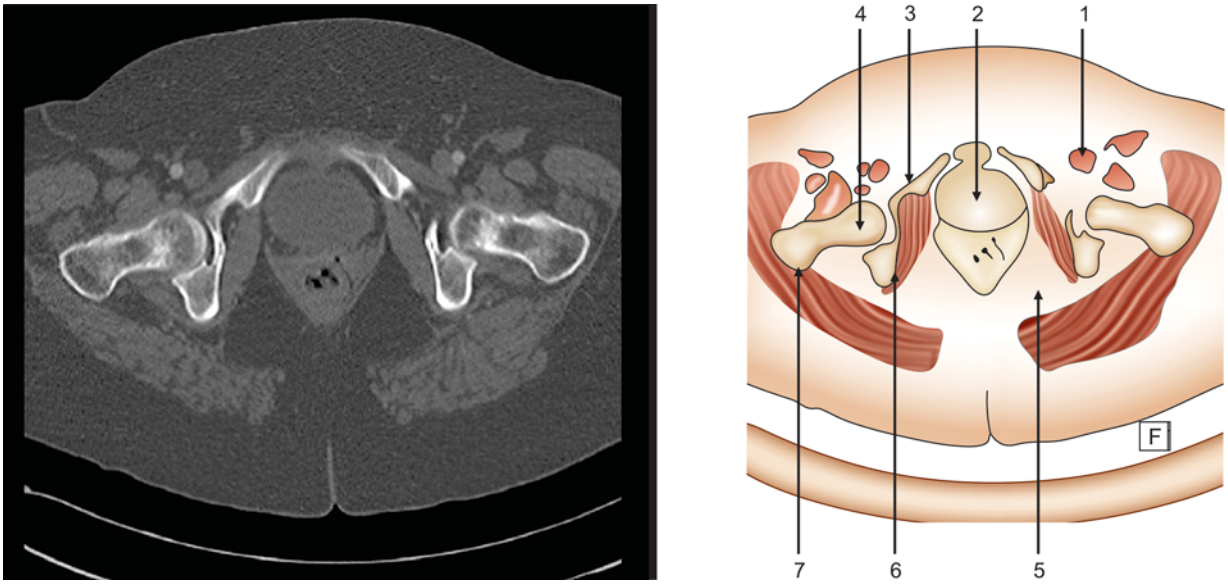

Figure 15.4

1. Femoral vessels
2. Bladder
3. Superior ramus of pubis
4. Head of femur
5. Ischio-anal fossa
6. Ischium
7. Greater trochanter

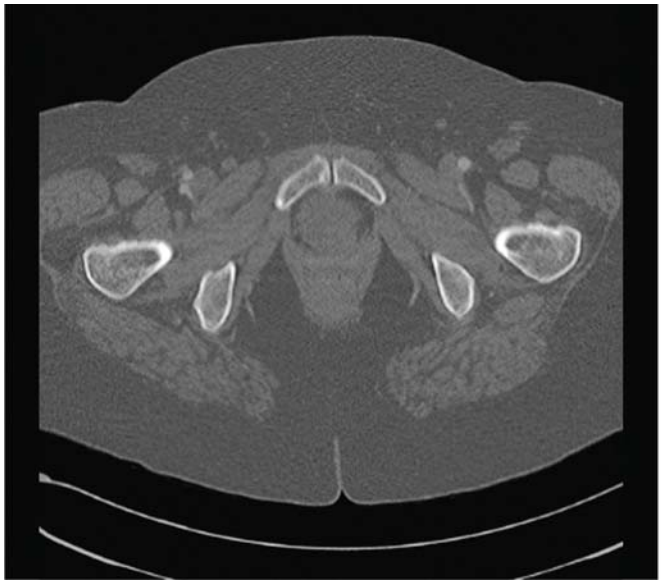

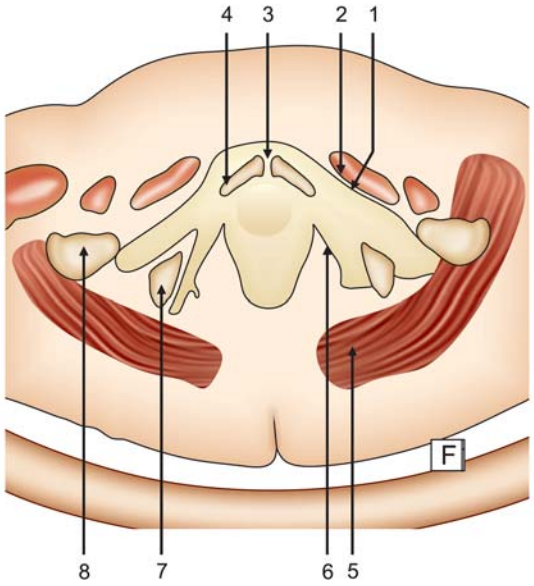

Figure 15.5

1. Obturator externus
2. Pectineus
3. Pubic symphysis
4. Body of pubis
5. Gluteus maximus
6. Obturator internus
7. Ischium
8. Femur



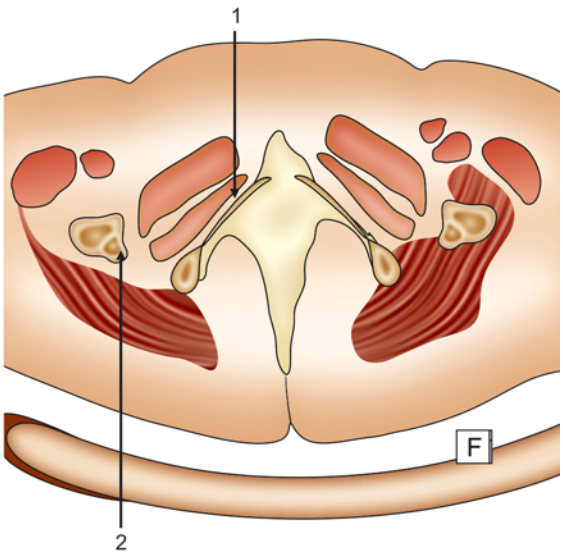

Figure 15.6

1. Inferior ramus of pubi
2. Lesser trochanter

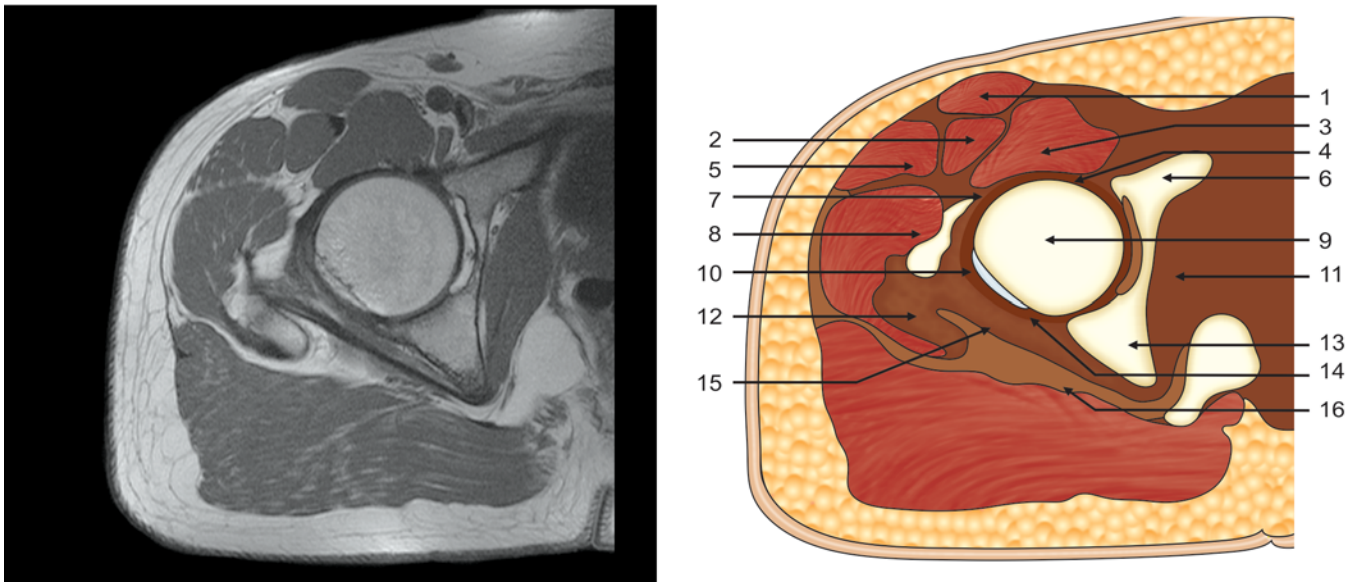

Figure 15.7

1. Sartorius
2. Rectus femoris
3. Iliopsoas
4. Anterior labrum
5. Tensor fascia lata
6. Pubis
7. Iliofemoral ligament
8. Gluteus medius
9. Femoral head
10. Iliofemoral ligament
11. Obturator internus
12. Greater trochanter
13. Ischium
14. Posterior labrum
15. Obturator internus tendon
16. Sciatic nerve

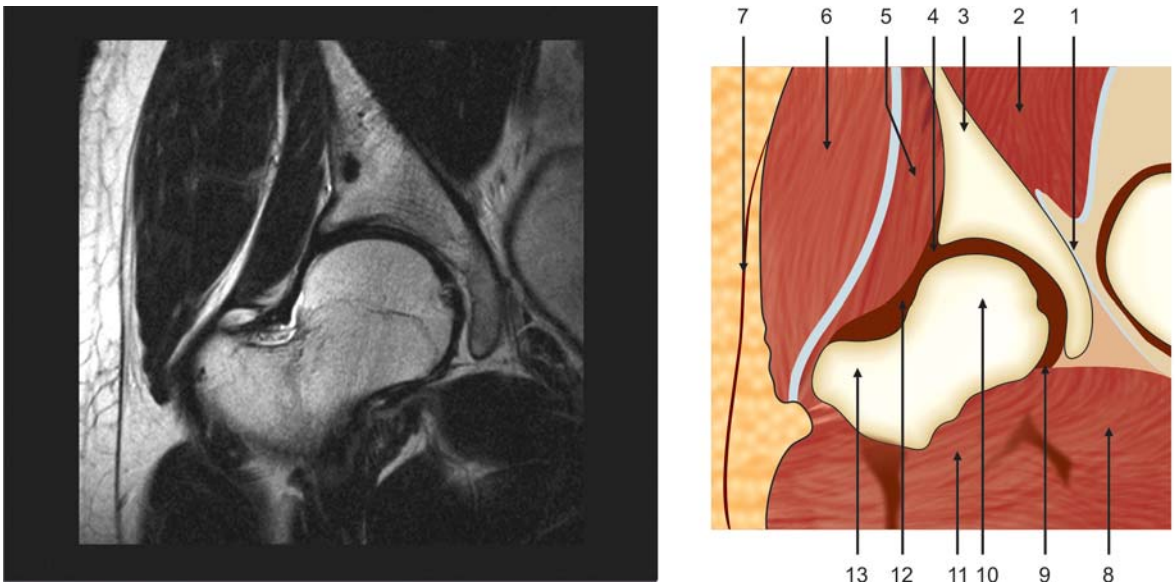

Figure 15.8

1. Acetabulum
2. Iliopsoas
3. Ilium
4. Superior labrum
5. Gluteus minimus
6. Gluteus medius
7. Iliotibial tract
8. Obturator externus
9. Joint space
10. Femoral head
11. Iliopsoas
12. Iliofemoral ligament
13. Greater trochanter

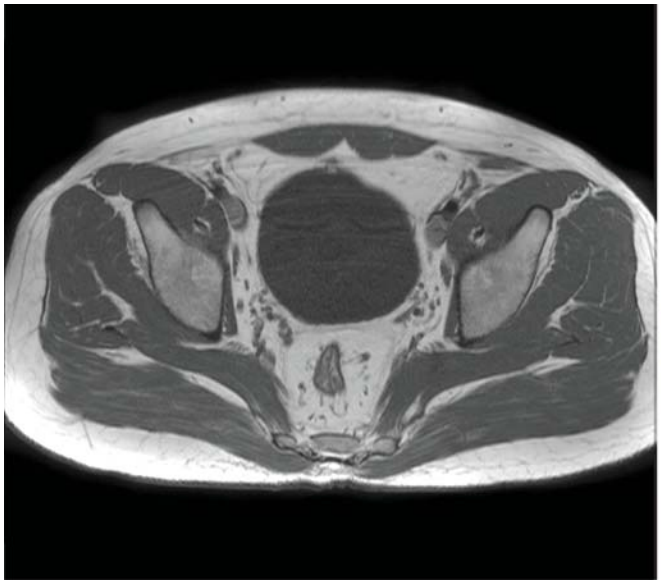

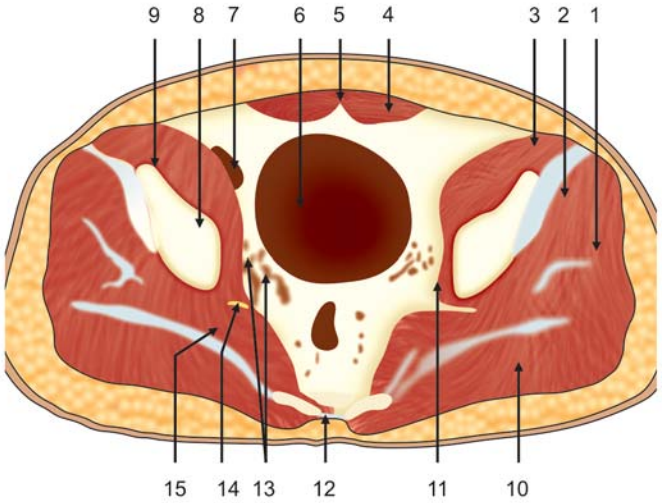

Figure 15.9

1. Gluteus medius
2. Gluteus minimus
3. Iliopsoas
4. Rectus abdominis
5. Linea alba
6. Urinary bladder
7. External iliac vessels
8. Acetabulum
9. Anterior inferior iliac spine
10. Gluteus maximus
11. Obturator internus
12. Sacrum
13. Obturator and inferior gluteal vessels
14. Sciatic nerve
15. Piriformis



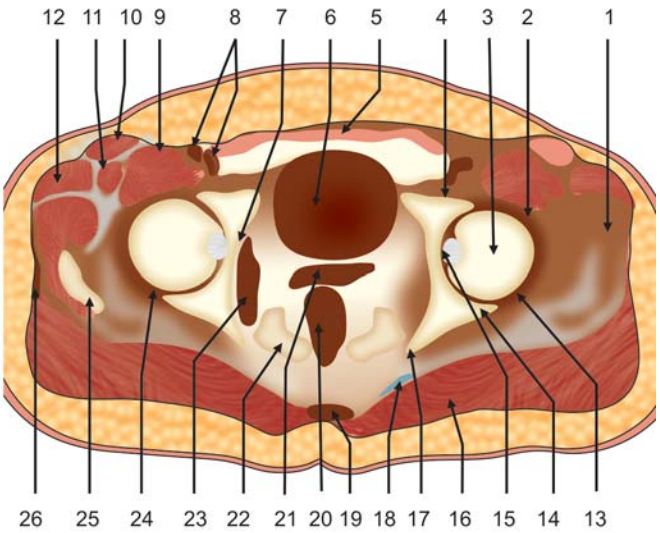

Figure 15.10

1. Gluteus medius
2. Iliofemoral ligament
3. Femoral head
4. Anterior pillar, acetabulum
5. Rectus abdominis
6. Urinary bladder
7. Quadrilateral plate
8. Femoral vessels
9. Iliopsoas
10. Sartorius
11. Rectus femoris
12. Tensor fascia lata
13. Ischiofemoral ligament
14. Posterior pillar, acetabulum
15. Ligamentum teres
16. Gluteus maximus
17. Ischial spine
18. Sacrotuberous ligament
19. Coccyx
20. Rectum
21. Seminal vesicles
22. Ischiorectal fossa
23. Obturator internus
24. Posterior labrum
25. Greater trochanter
26. Iliotibial tract

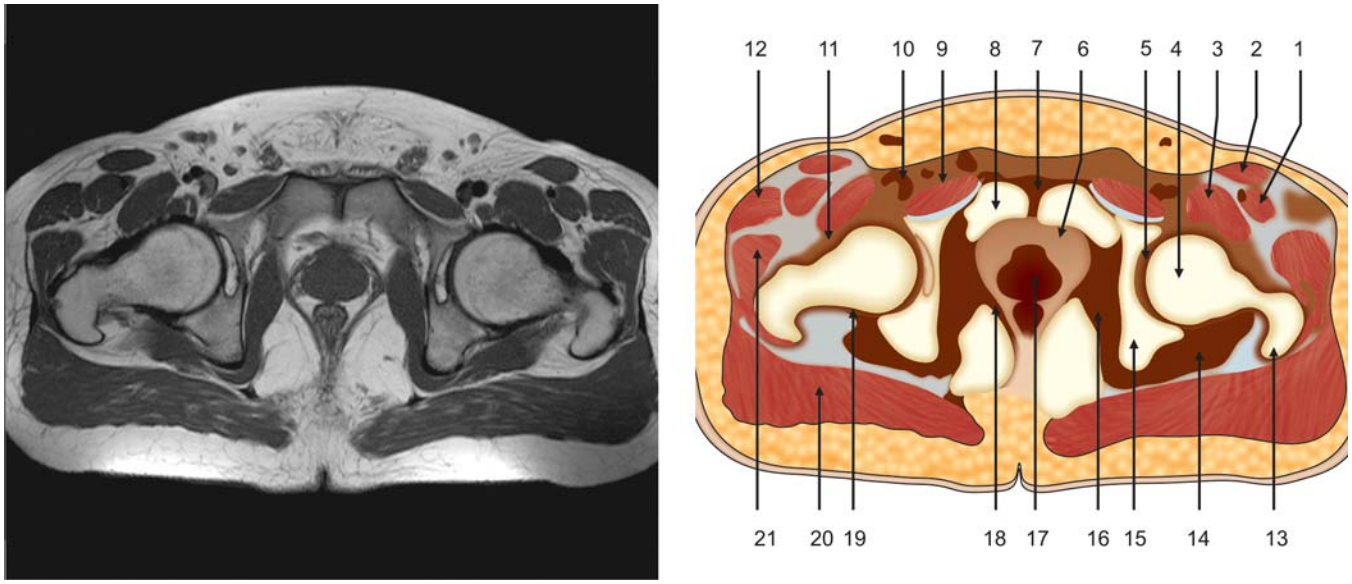

Figure 15.11

1. Rectus femoris
2. Sartorius
3. Iliopsoas
4. Femoral head
5. Labrum
6. Retropubic space of Retzius
7. Symphysis pubis
8. Pubis
9. Pectineus
10. Femoral vessels
11. Iliofemoral ligament
12. Tensor fascia lata
13. Greater trochanter
14. Inferior gemellus
15. Ischium
16. Obturator internus
17. Prostate
18. Levator ani
19. Ischiofemoral ligament
20. Gluteus maximus
21. Gluteus medius minimus

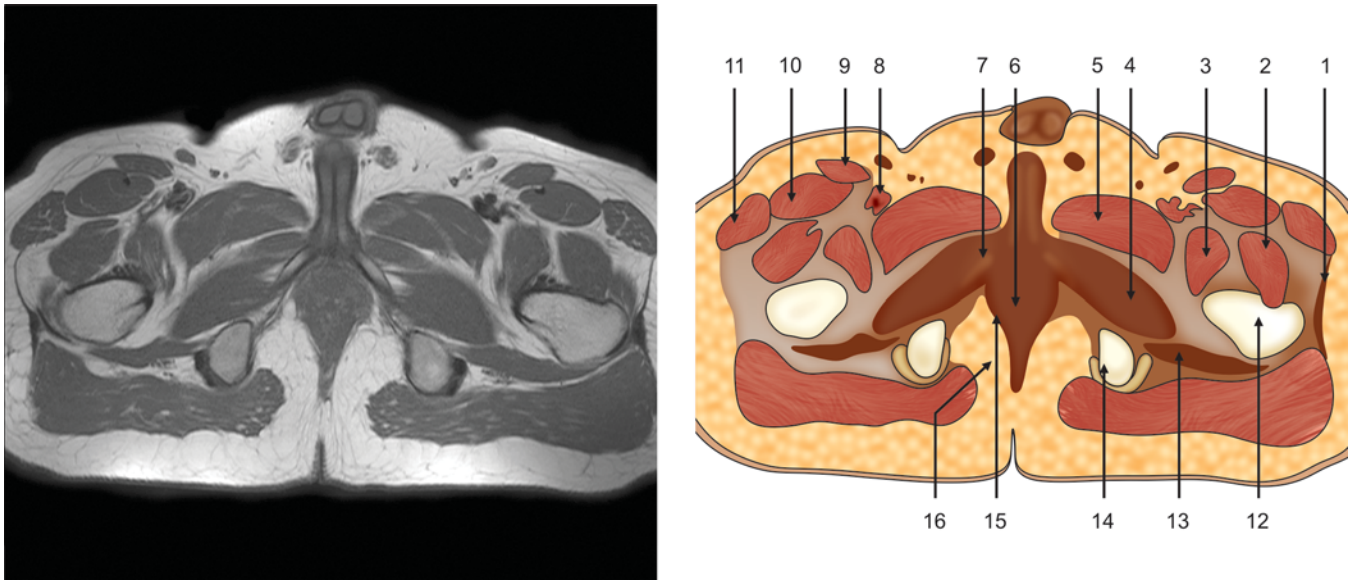

Figure 15.12

1. Ilio-tibial tract
2. Vastus lateralis
3. Iliopsoas
4. Obturator externus
5. Pectineus
6. Anal canal
7. Inferior pubic ramus
8. Femoral vessels
9. Sartorius
10. Rectus femoris
11. Tensor fascia lata
12. Femur
13. Quadratus femoris
14. Ischial tuberosity
15. Levator ani
16. Ischioanal fossa

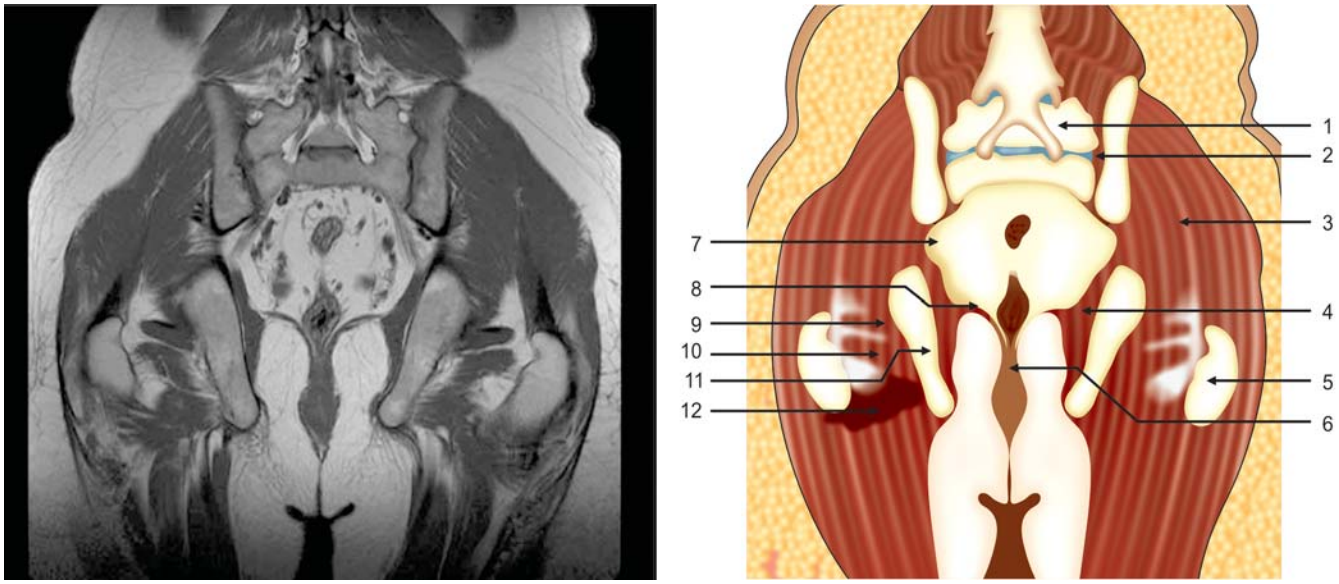

Figure 15.13

1. Sacrum
2. Sacroiliac joint
3. Gluteus maximus
4. Obturator internus
5. Greater trochanter
6. Anal canal
7. Sciatic nerve
8. Levator ani
9. Gemelli
10. Obturator externus
11. Ischium
12. Quadratus femoris

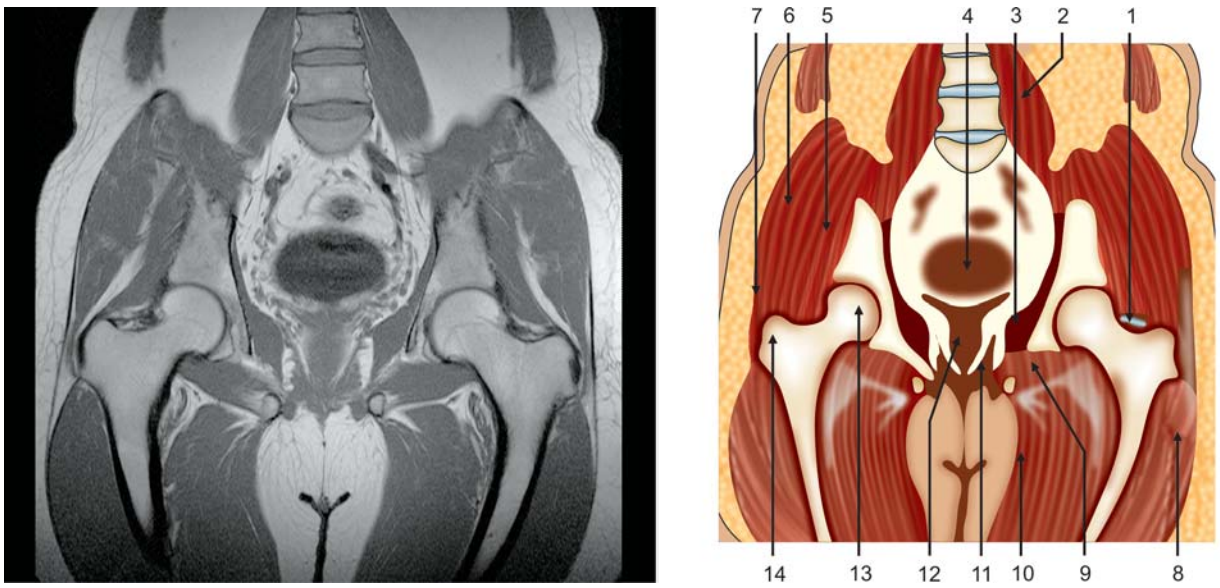

Figure 15.14

1. Iliofemoral ligament
2. Psoas
3. Obturator internus
4. Bladder
5. Gluteus minimus
6. Gluteus medius
7. Iliofemoral tract
8. Vastus lateralis
9. Obturator externus
10. Adductor magnus
11. Levator ani
12. Prostate
13. Femoral head
14. Greater trochanter

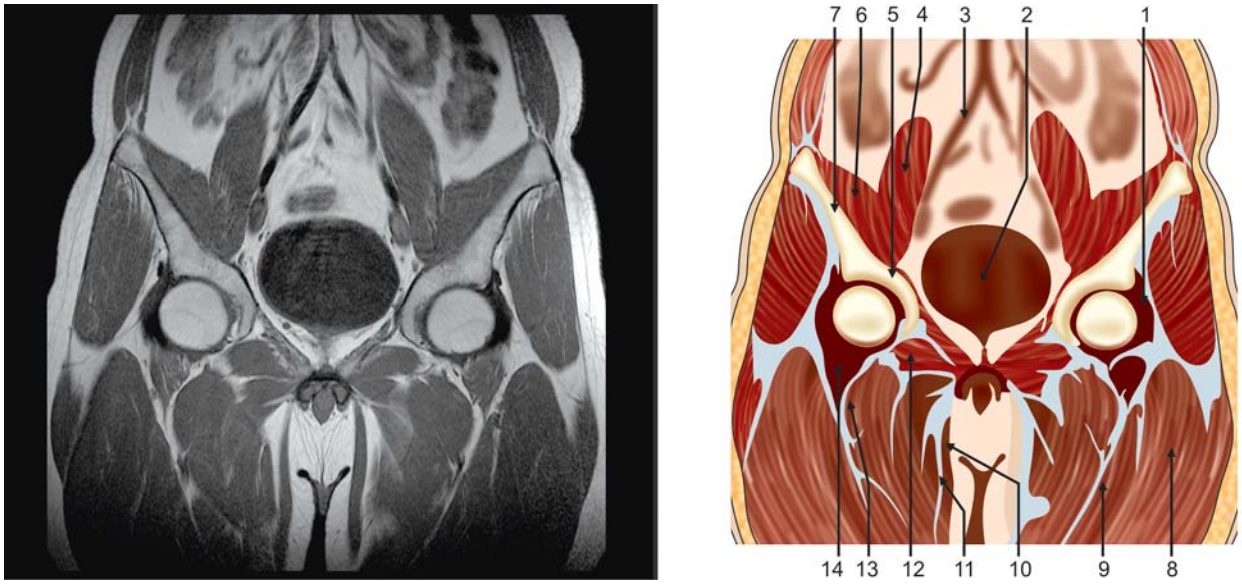

Figure 15.15

1. Iliofemoral ligament
2. Urinary bladder
3. Common iliac vessels
4. Psoas
5. Acetabulum
6. Iliacus
7. Iliac bone
8. Vastus lateralis
9. Vastus intermedius
10. Gracilis
11. Adductor brevis
12. Obturator externus
13. Pectineus
14. Iliopsoas

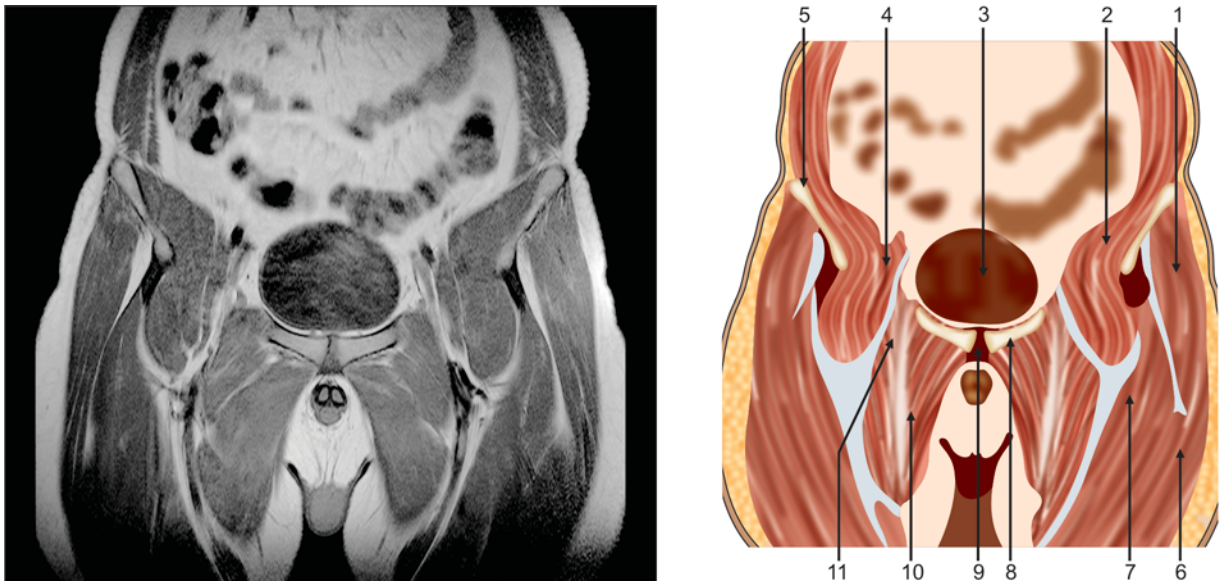

Figure 15.16

1. Gluteus medius
2. Iliopsoas
3. Urinary bladder
4. External iliac vessels
5. Ilium
6. Vastus lateralis
7. Rectus femoris
8. Superior ramus pubis
9. Pubic symphysis
10. Adductor longus
11. Pectineus

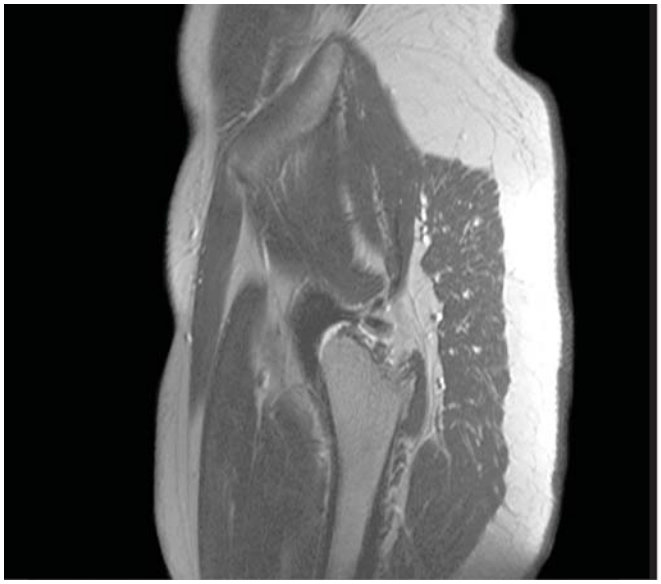

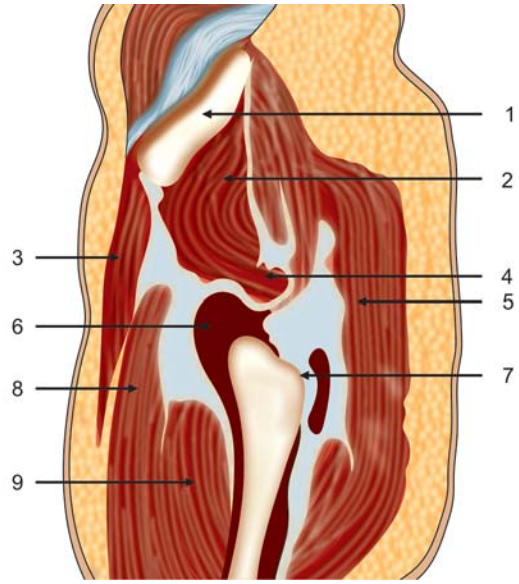

Figure 15.17

1. Ilium
2. Gluteus medius
3. Sartorius
4. Piriformis
5. Gluteus maximus
6. Obturator internus
7. Greater trochanter
8. Rectus femoris
9. Vastus intermedius

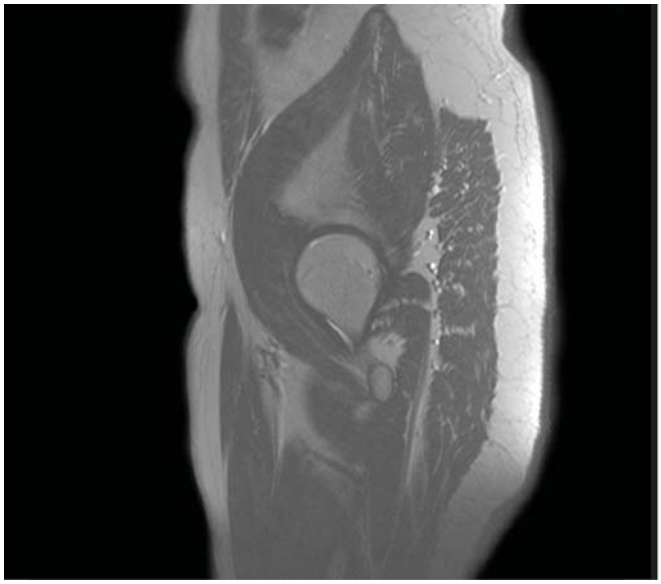

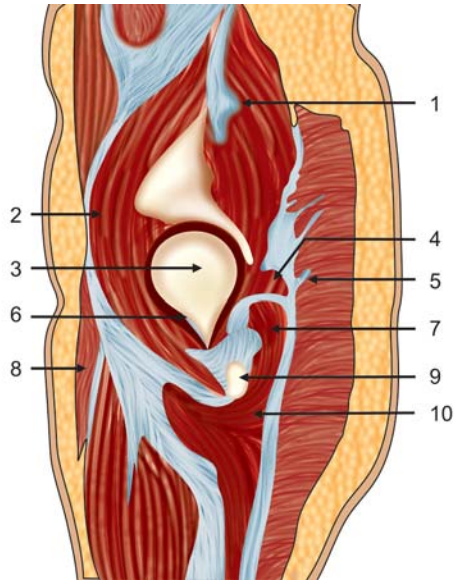

Figure 15.18

1. Gluteus minimus
2. Iliopsoas
3. Head, femur
4. Gemelli
5. Gluteus maximus
6. Iliofemoral ligament
7. Quadratus femoris
8. Sartorius
9. Lesser trochanter
10. Sciatic nerve

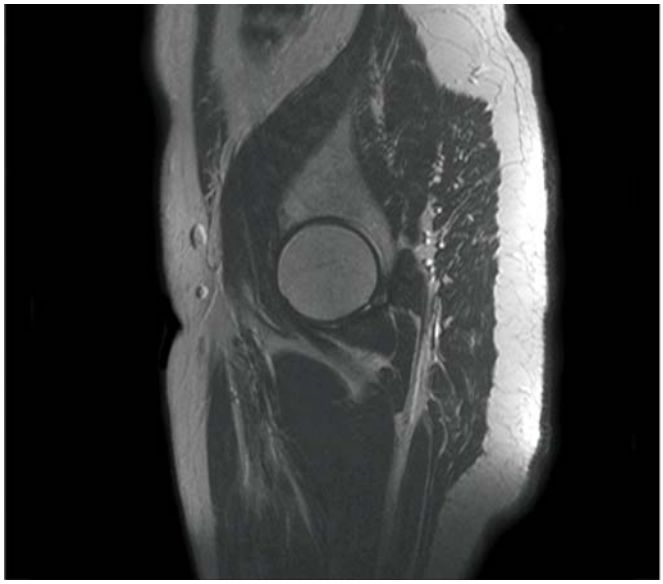

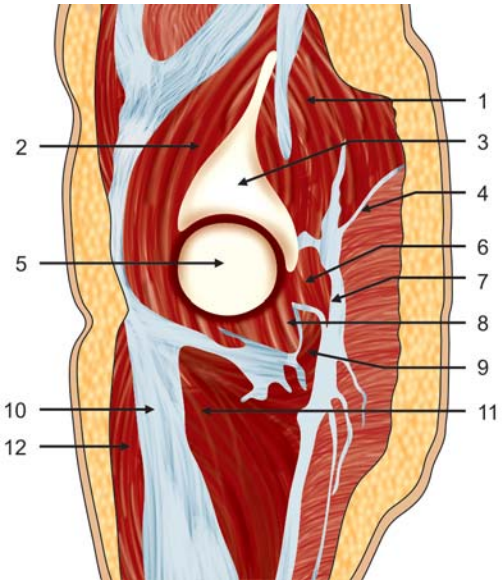

Figure 15.19

1. Gluteus minimus
2. Iliopsoas
3. Acetabular roof
4. Gluteus maximus
5. Head, femur
6. Gemelli
7. Sciatic nerve
8. Obturator externus
9. Quadratus femoris
10. Femoral vessels
11. Pectineus
12. Sartorius

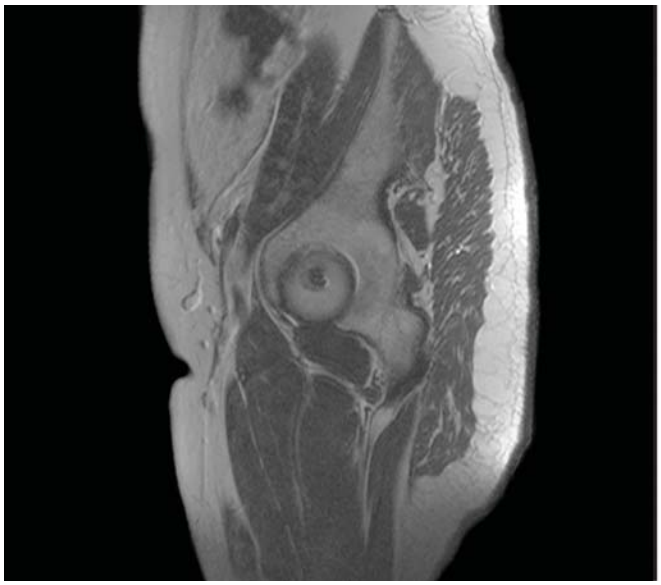

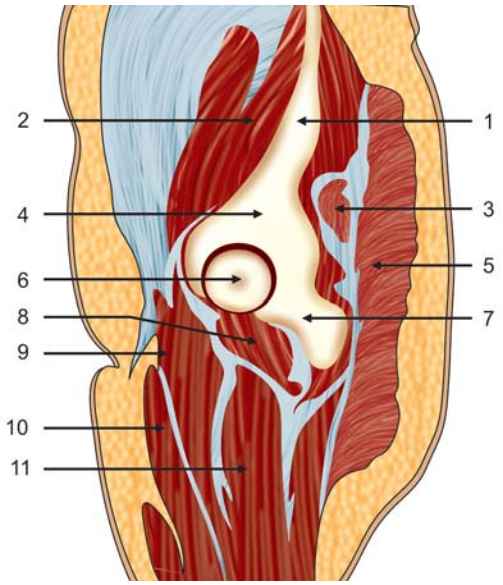

Figure 15.20

1. Ilium
2. Iliopsoas
3. Piriformis
4. Acetabulum
5. Gluteus maximus
6. Head, femur
7. Ischium
8. Obturator externus
9. Pectineus
10. Adductor longus
11. Adductor magnus

CHAPTER 16

Thigh and Calf

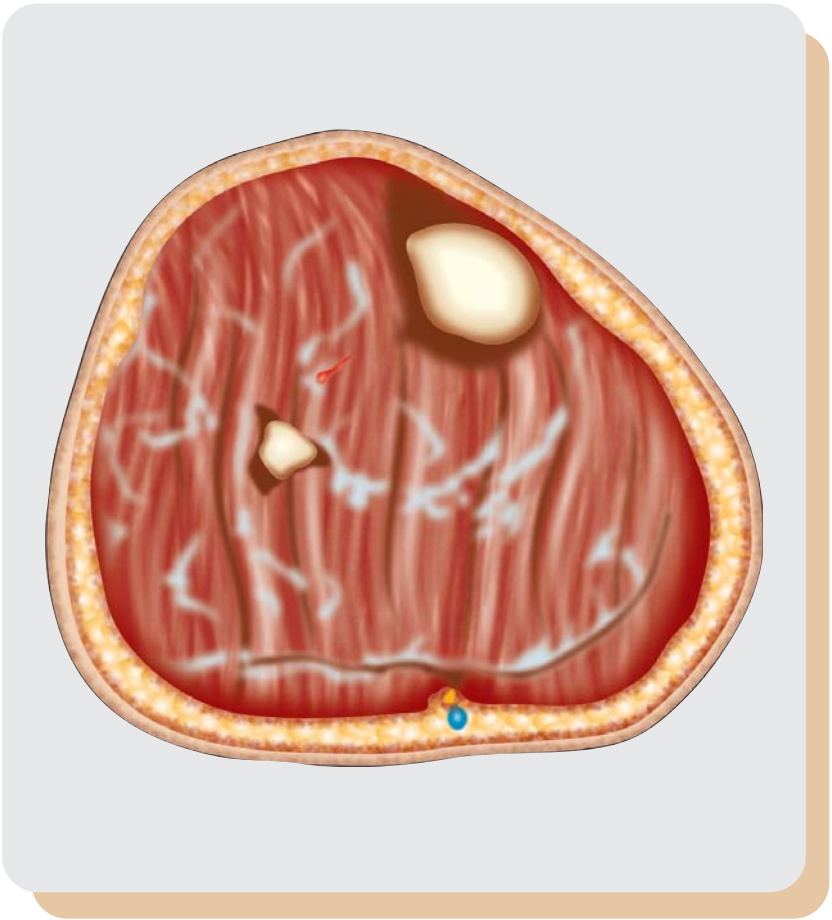

THIGH FIGURES

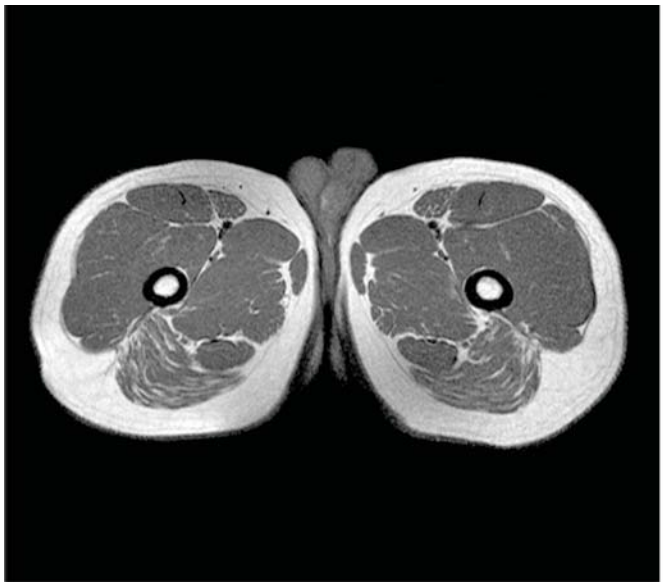

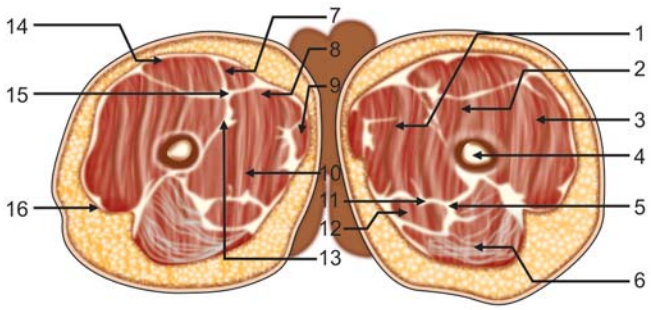

Figure 16.1

1. Adductor brevis
2. Vastus intermedius
3. Vastus lateralis
4. Femur
5. Sciatic nerve
6. Gluteus maximus
7. Sartorius
8. Adductor longus
9. Gracilis
10. Adductor magnus
11. Semimembranosis
12. Semitendinosis
13. Deep femoral vessels
14. Rectus femoris
15. Femoral vessels
16. Ilio-tibial tract

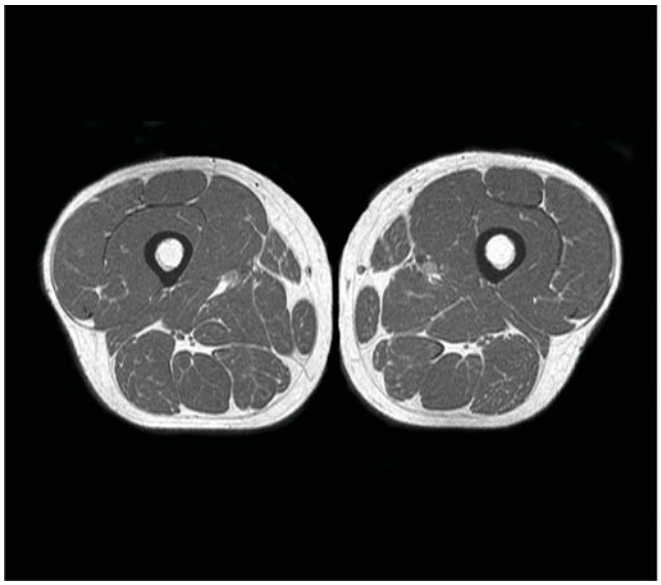

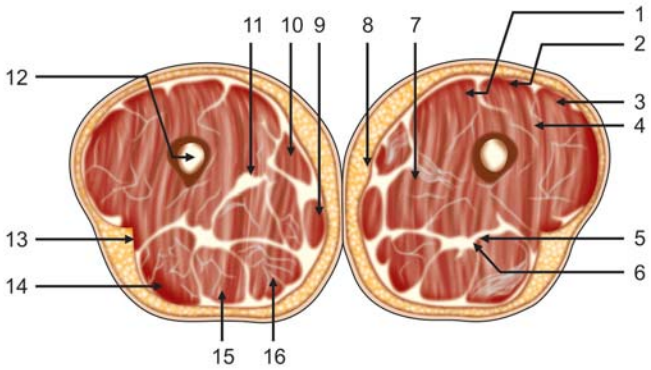

Figure 16.2

1. Vastus medialis
2. Rectus femoris
3. Vastus lateralis
4. Vastus intermedius
5. Common peroneal nerve
6. Tibial nerve
7. Adductor magnus
8. Great saphenous vein
9. Gracilis
10. Sartorius
11. Femoral vessels
12. Femur
13. Biceps femoris (Short head)
14. Biceps femoris (Long head)
15. Semitendinosis
16. Semimembranosis

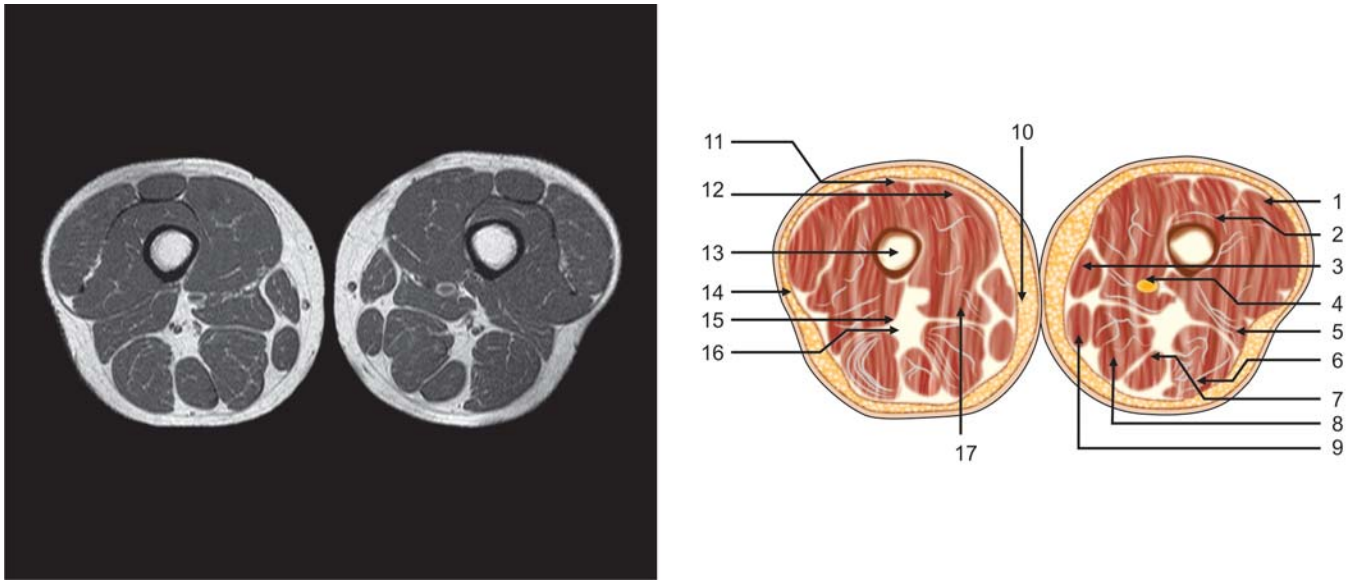

Figure 16.3

1. Vastus lateralis
2. Vastus intermedius
3. Sartorius
4. Femoral vessels
5. Biceps femoris (short head)
6. Biceps femoris
7. Semitendinosis
8. Semimembranosis
9. Gracilis
10. Great saphenous vein
11. Rectus femoris
12. Vastus medialis
13. Femur
14. Ilio-tibial tract
15. Common peroneal nerve
16. Tibial nerve
17. Adductor magnus

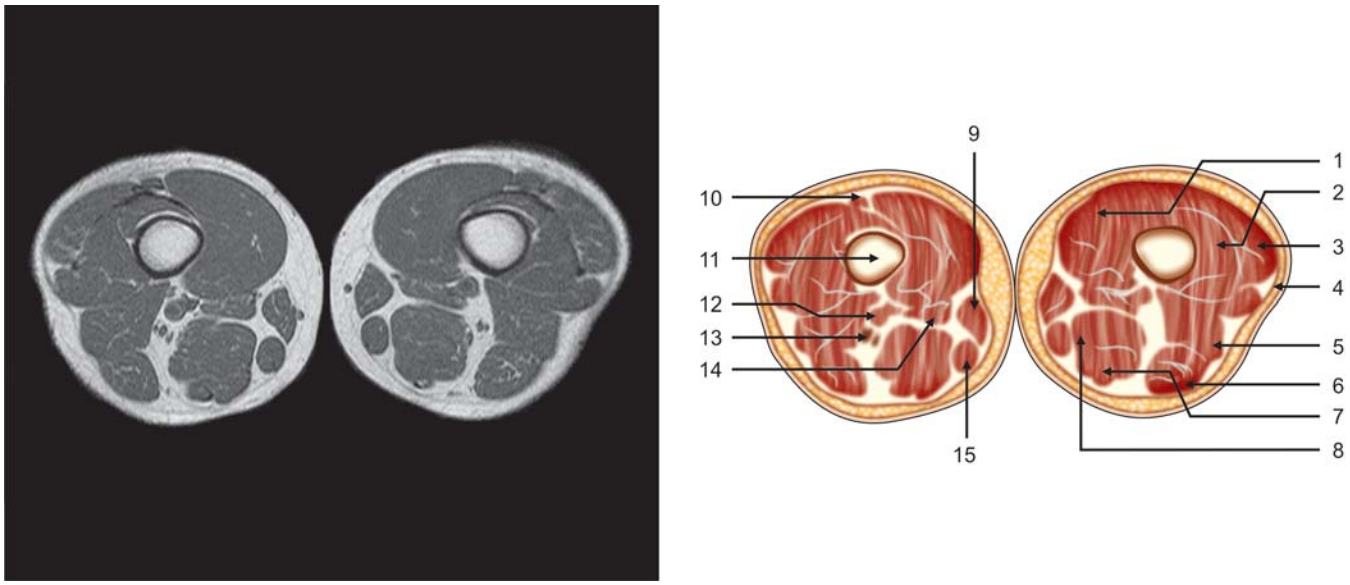

Figure 16.4

1. Vastus medialis
2. Vastus intermedius
3. Vastus lateralis
4. Ilio-tibial tract
5. Biceps femoris (short head)
6. Biceps femoris (long head)
7. Semitendinosis
8. Semimembranosis
9. Sartorius
10. Quadriceps femoris
11. Femur
12. Popliteal vessels
13. Common peroneal nerve
14. Adductor magnus
15. Gracilis

CORONAL IMAGES

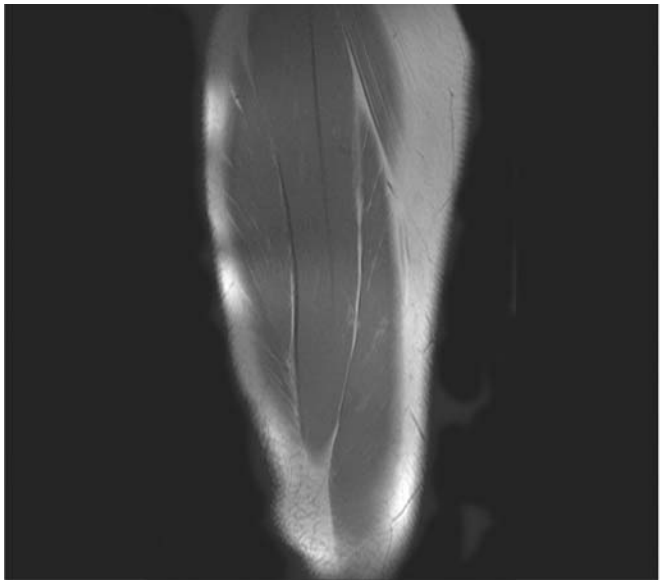

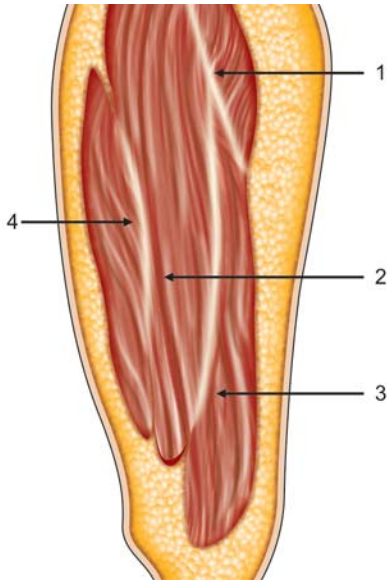

Figure 16.5

1. Sartorius
2. Rectus femoris
3. Vastus medialis
4. Vastus lateralis

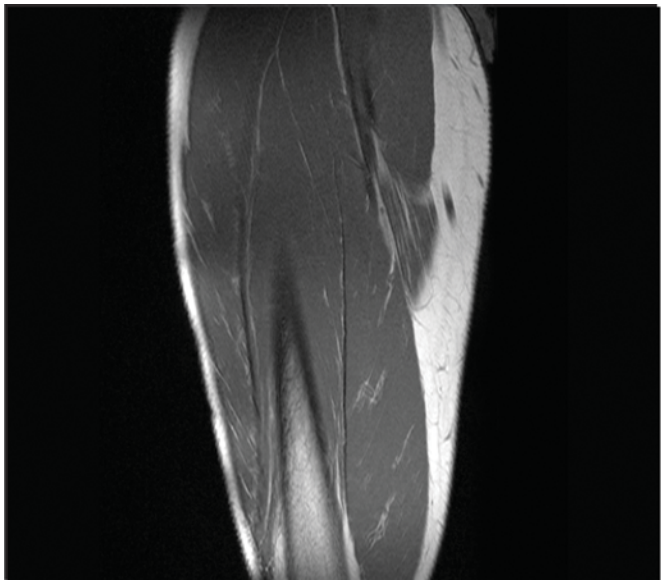

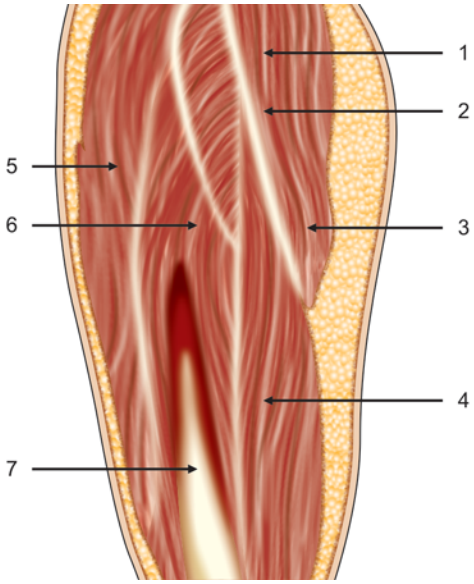

Figure 16.6

1. Adductor longus
2. Femoral vessels
3. Sartorius
4. Vastus medialis
5. Vastus lateralis
6. Vastus intermedius
7. Femur

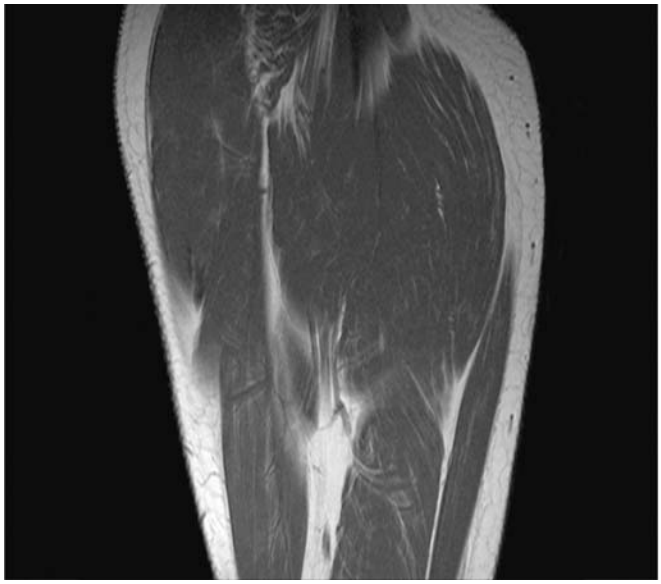

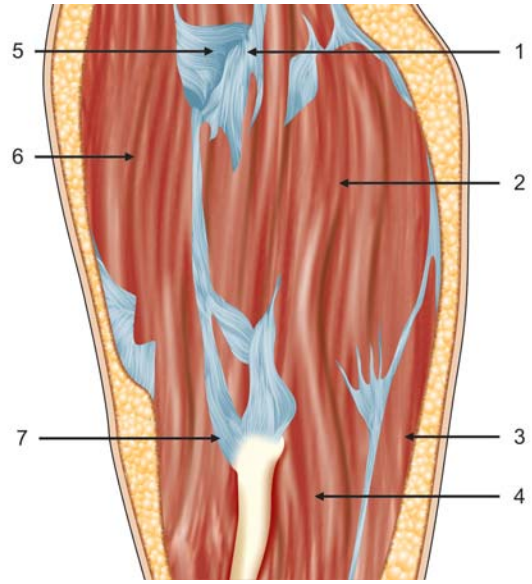

Figure 16.7

1. Femoral vessels
2. Adductor magnus
3. Gracilis
4. Semimembranosus
5. Gluteus maximus
6. Vastus lateralis
7. Biceps femoris

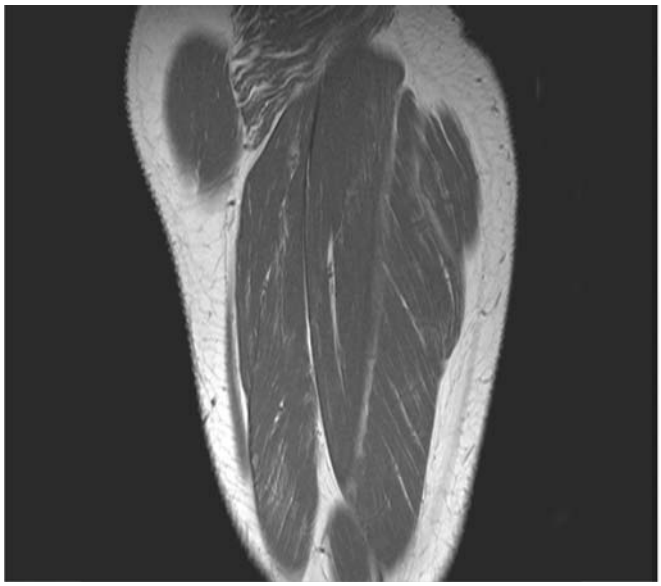

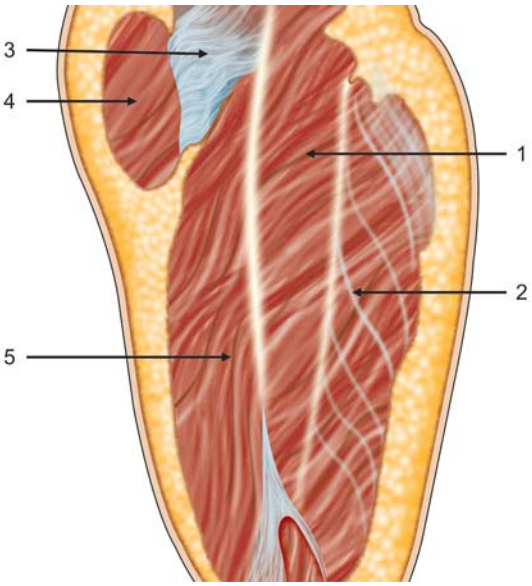

Figure 16.8

1. Semitendinosus
2. Semimembranosus
3. Gluteus maximus
4. Vastus lateralis
5. Biceps femoris

SAGITTAL IMAGES

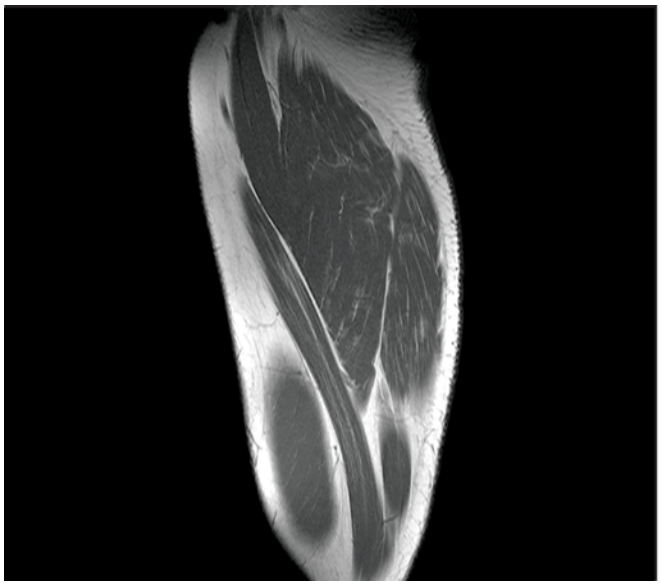

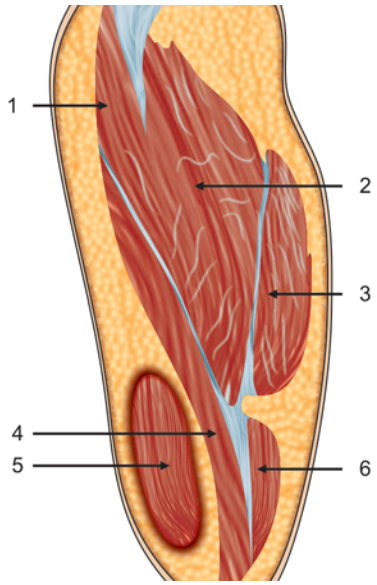

Figure 16.9

1. Adductor longus
2. Adductor magnus
3. Semimembranosus
4. Sartorius
5. Vastus medialis
6. Gracilis

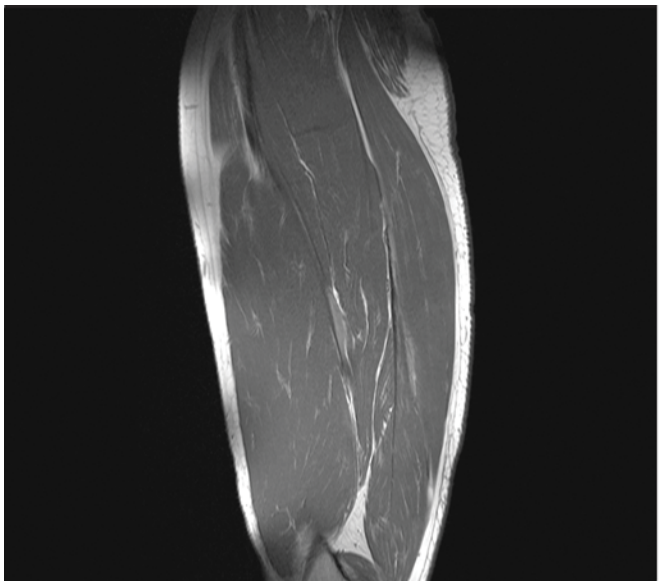

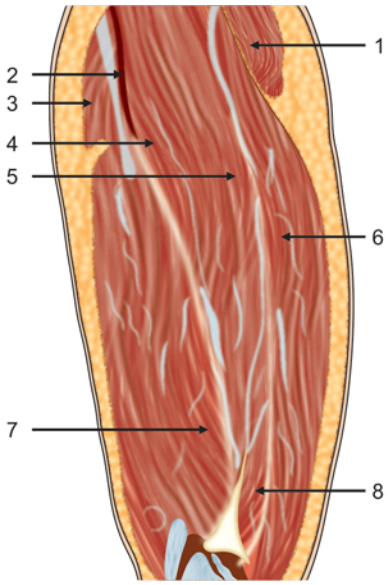

Figure 16.10

1. Gluteus maximus
2. Femoral vessels
3. Sartorius
4. Adductor longus
5. Adductor magnus
6. Semitendinosus
7. Vastus medialis
8. Semimembranosus

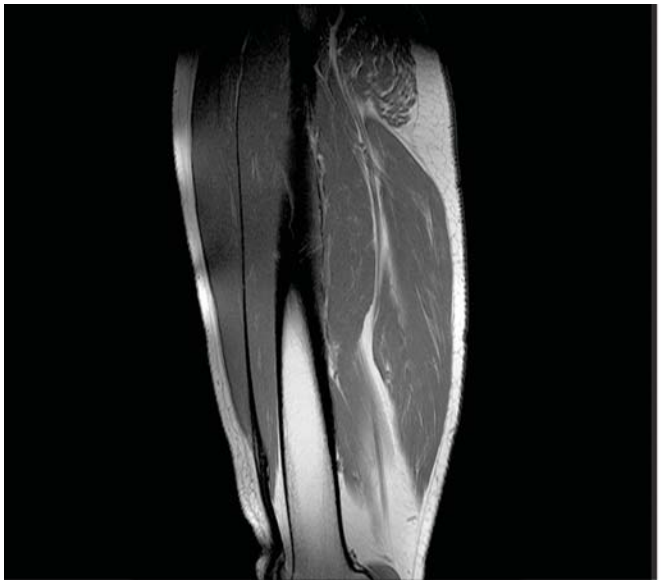

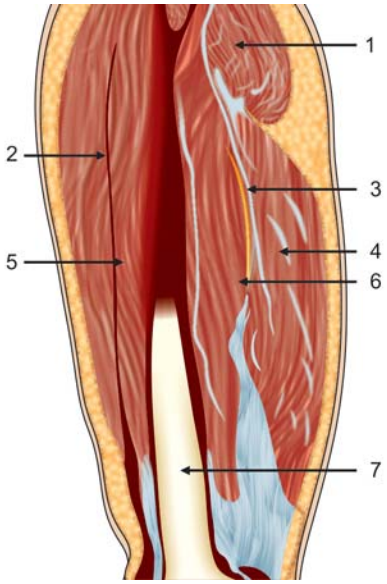

Figure 16.11

1. Gluteus maximus
2. Rectus femoris
3. Sciatic nerve
4. Biceps femoris
5. Vastus intermedius
6. Adductor magnus
7. Femur

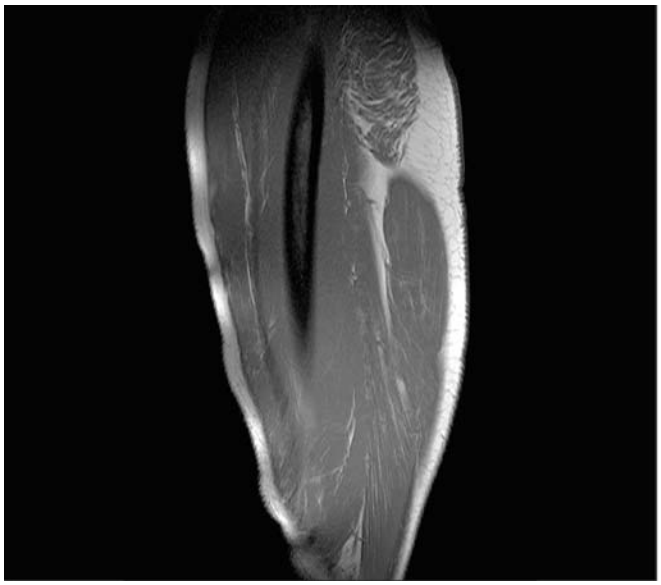

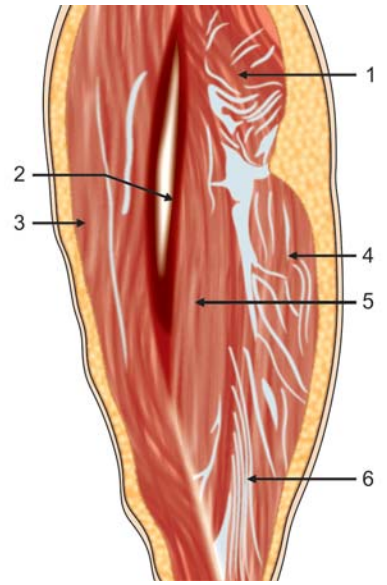

Figure 16.12

1. Gluteus maximus
2. Femur
3. Vastus lateralis
4. Biceps femoris
5. Vastus intermedius
6. Biceps femoris (short head)

CALF FIGURES

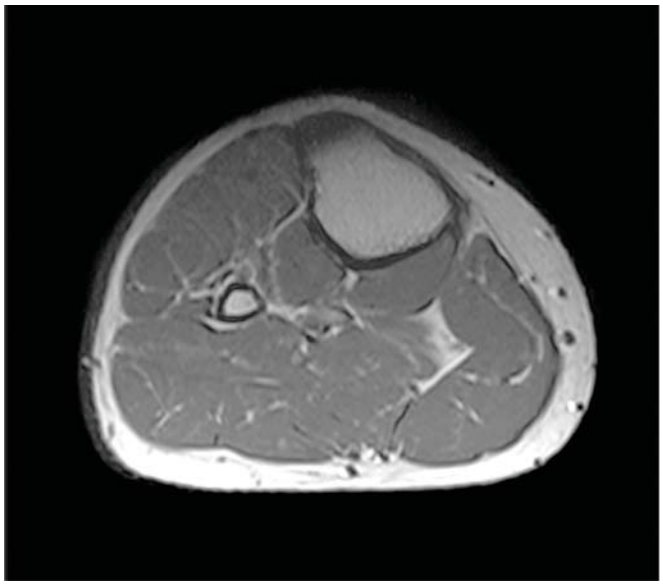

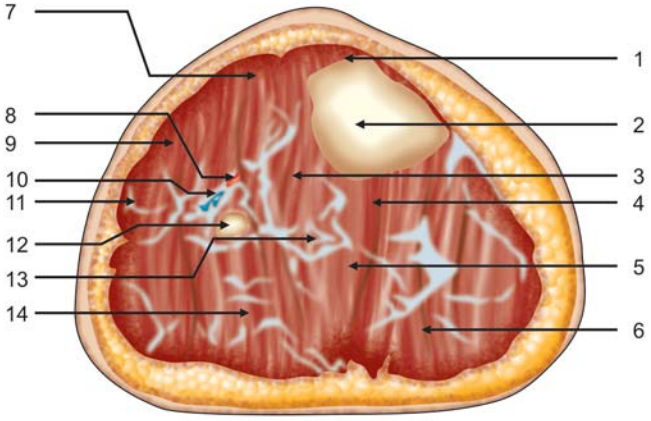

Figure 16.13

1. Tibial tuberosity
2. Tibia
3. Tibialis posterior
4. Popliteus
5. Soleus
6. Gastrocnemius, medial head
7. Tibialis anterior
8. Anterior tibial artery
9. Extensor digitorum longus
10. Common peroneal nerve
11. Peroneus longus
12. Fibula
13. Posterior tibial, peroneal artery
14. Gastrocnemius, lateral head

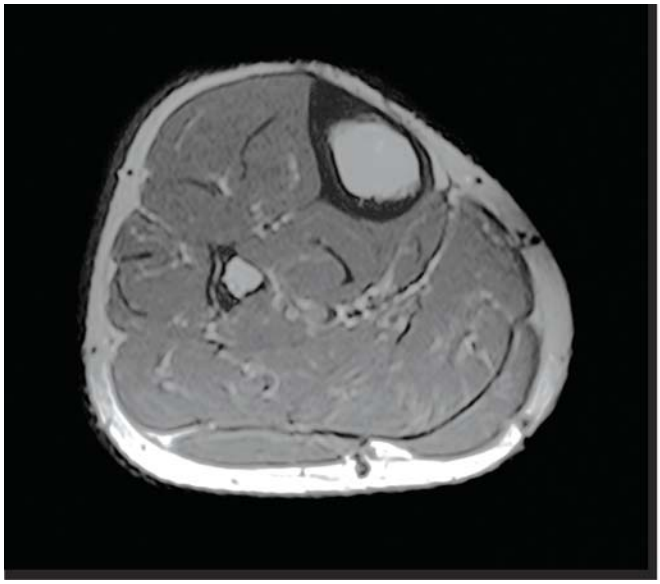

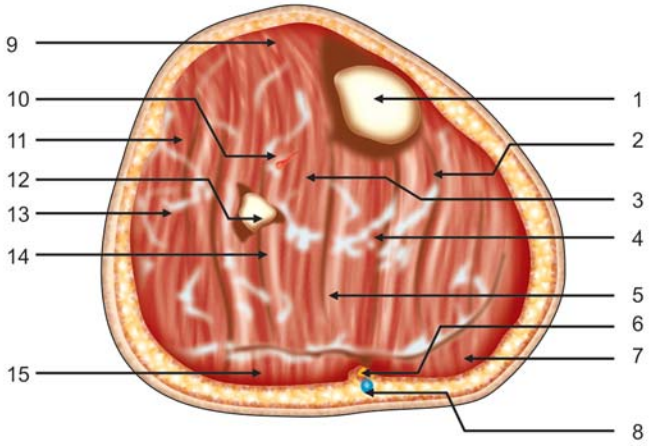

Figure 16.14

1. Tibia
2. Flexor digitorum longus
3. Tibialis posterior
4. Posterior tibial artery, tibial nerve
5. Soleus
6. Sural nerve
7. Gastrocnemius, medial head
8. Lesser saphenous vein
9. Tibialis anterior
10. Anterior tibial artery, Deep peroneal nerve
11. Extensor hallucis and digitorum longus
12. Fibula
13. Peroneus longus, brevis
14. Flexor hallucis longus
15. Gastrocnemius, lateral head

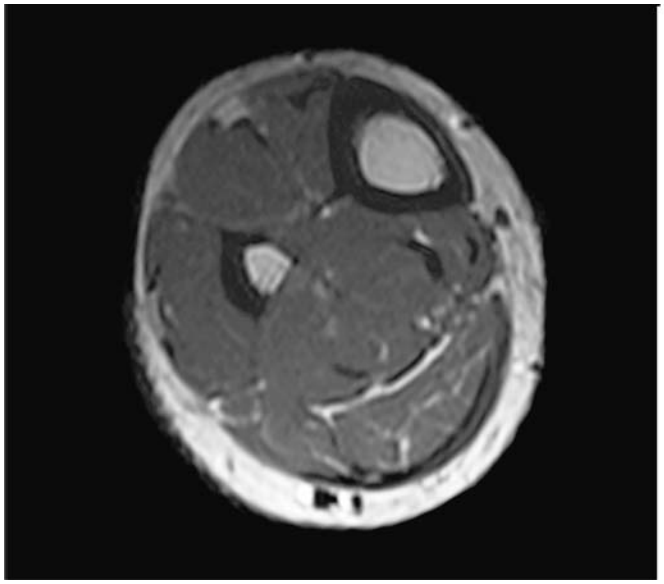

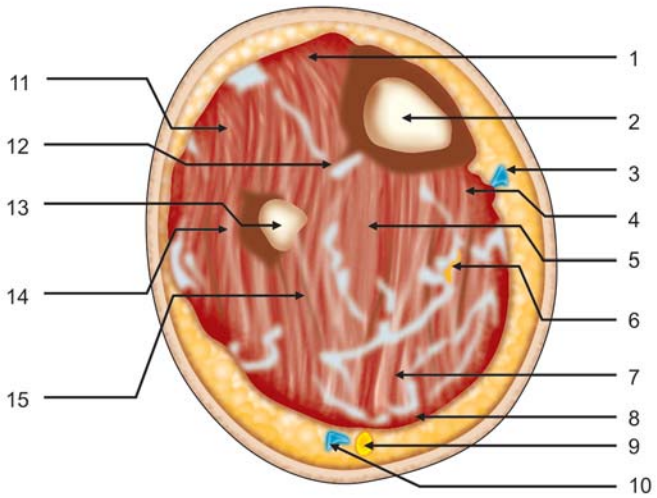

Figure 16.15

1. Tibialis anterior
2. Tibia
3. Greater saphenous vein
4. Flexor digitorum longus
5. Tibialis posterior
6. Posterior tibial artery, tibial nerve
7. Soleus
8. Gastrocnemius tendon
9. Sural nerve
10. Lesser saphenous vein
11. Extensor hallucis and digitorum longus
12. Interosseous membrane
13. Fibula
14. Peroneus longus and brevis
15. Flexor hallucis longus

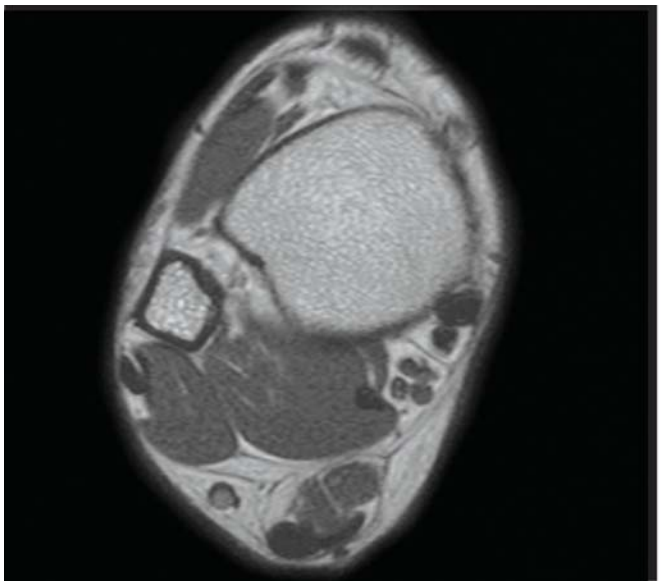

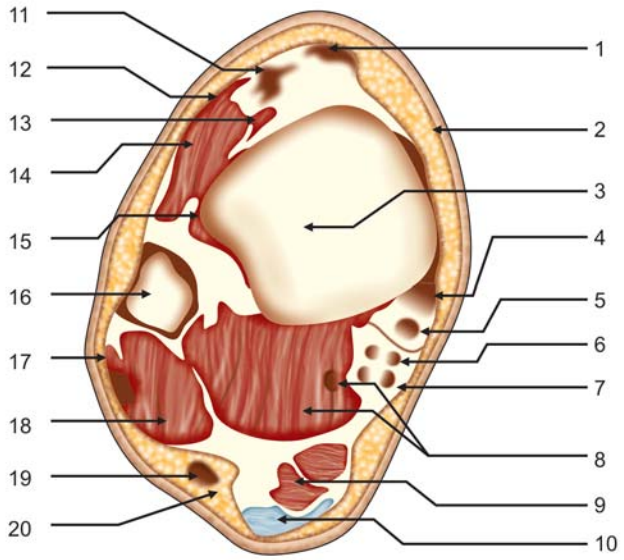

Figure 16.16

1. Tibialis anterior tendon
2. Great saphenous vein
3. Tibia
4. Tibialis posterior tendon
5. Flexor digitorum longus tendon
6. Posterior tibial artery
7. Tibial nerve
8. Flexor hallucis longus muscle and tendon
9. Soleus
10. Achilles tendon
11. Extensor hallucis longus tendon
12. Extensor digitorum longus tendon
13. Anterior tibial artery
14. Peroneus tertius
15. Anterior tubercle, tibia
16. Fibula
17. Peroneus longus tendon
18. Peroneus brevis
19. Lesser saphenous vein
20. Sural nerve

CORONAL IMAGES

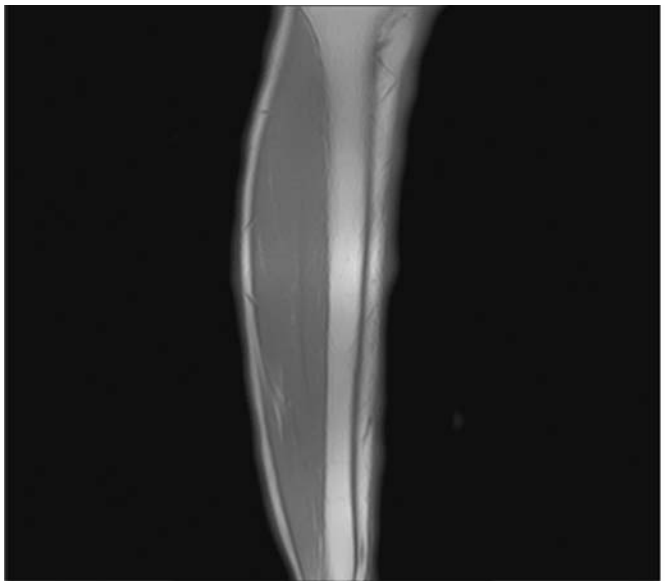

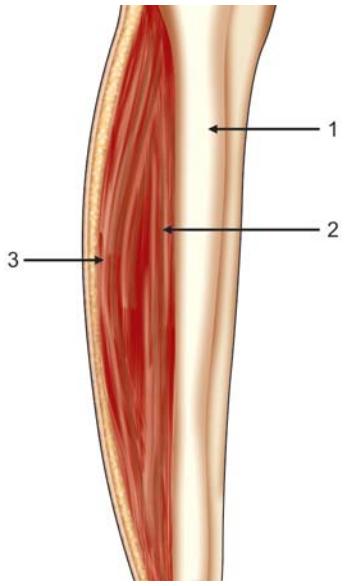

Figure 16.17

1. Tibia
2. Tibialis anterior
3. Extensor digitorum and extensor hallucis longus

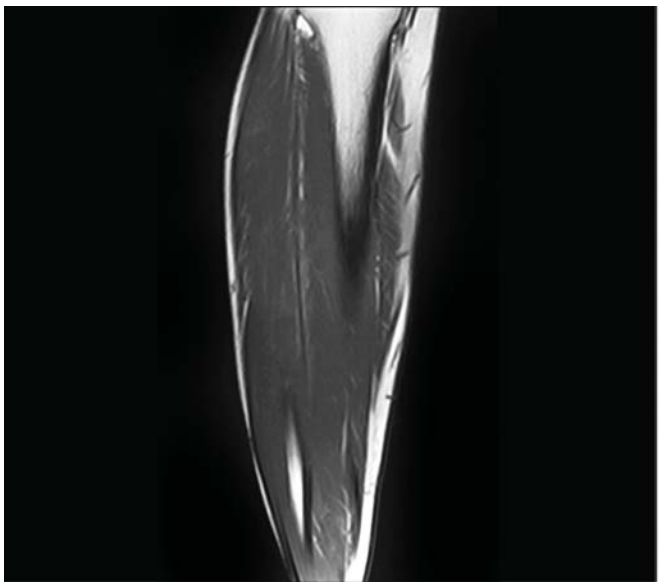

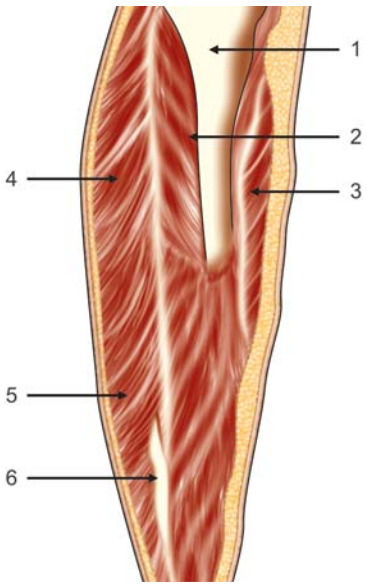

Figure 16.18

1. Tibia
2. Tibialis posterior
3. Soleus
4. Peroneus longus
5. Peroneus brevis
6. Fibula

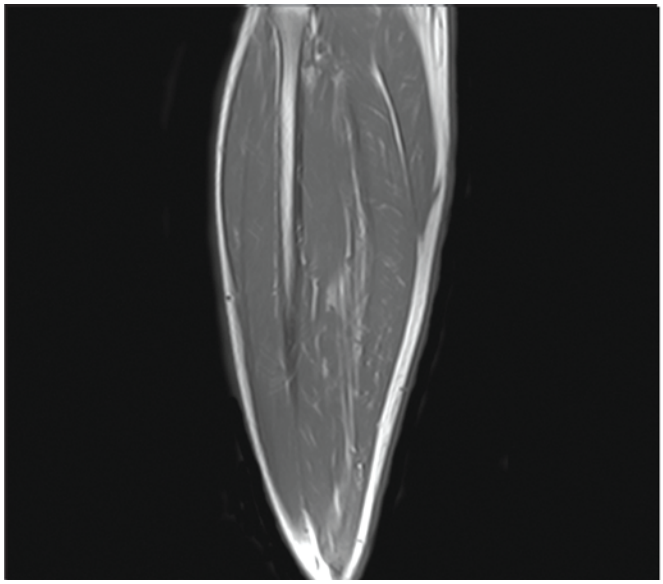

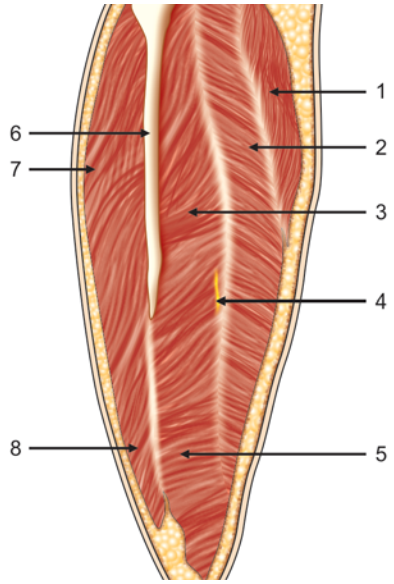

Figure 16.19

1. Gastrocnemius, medial head
2. Soleus
3. Tibialis posterior
4. Posterior tibial artery, tibial nerve
5. Flexor hallucis longus
6. Fibula
7. Peroneus longus
8. Peroneus brevis

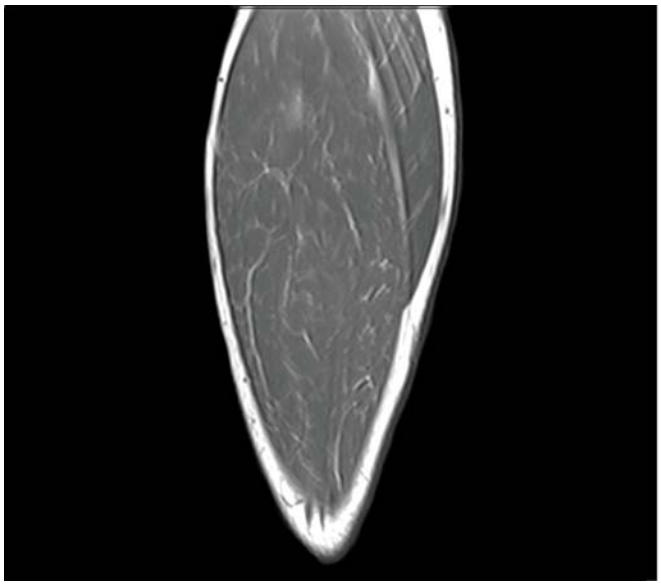

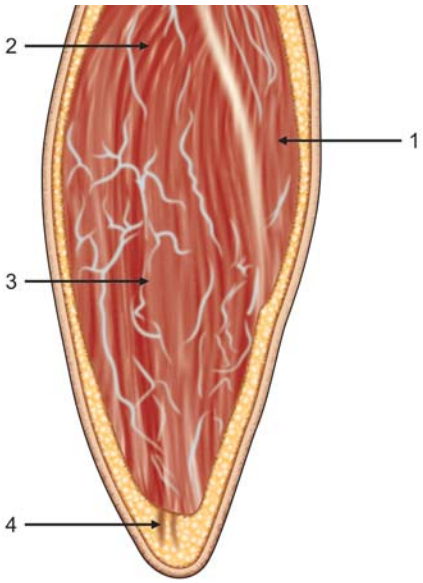

Figure 16.20

1. Gastrocnemius, medial head
2. Gastrocnemius, lateral head
3. Soleus
4. Lesser saphenous vein

SAGITTAL IMAGES

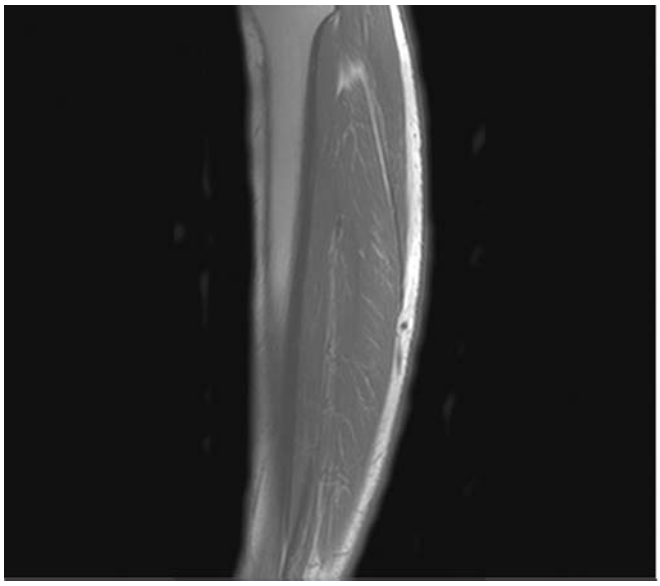

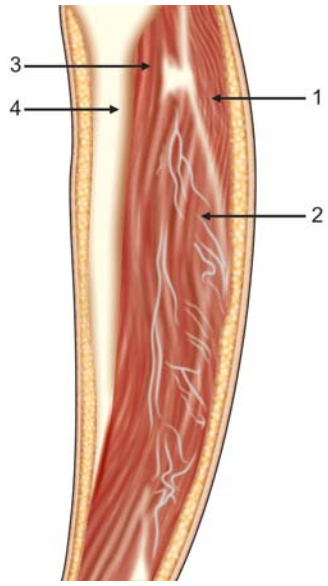

Figure 16.21

1. Gastrocnemius, medial head
2. Soleus
3. Popliteus muscle
4. Tibia



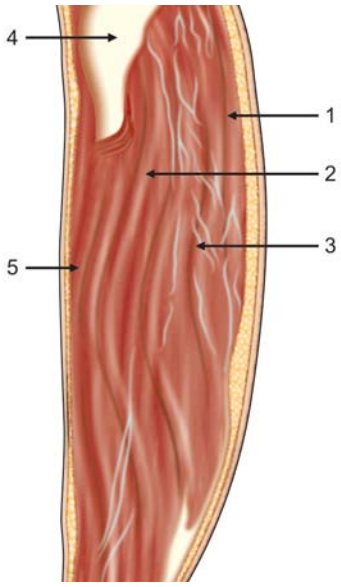

Figure 16.22

1. Gastrocnemius, medial head
2. Tibialis posterior
3. Soleus
4. Tibia
5. Tibialis anterior

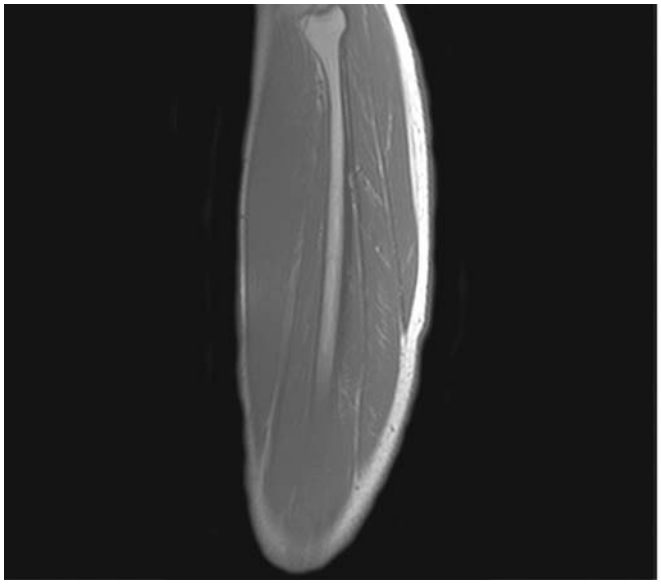

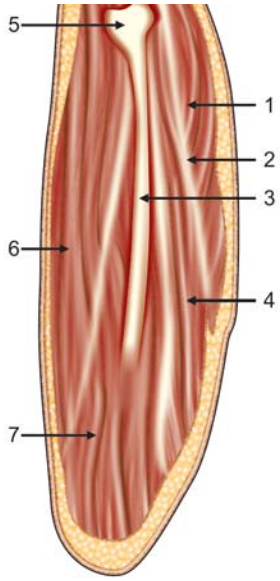

Figure 16.23

1. Gastrocnemius, lateral head
2. Soleus
3. Fibula
4. Flexor hallucis longus
5. Fibula, head
6. Tibialis anterior
7. Extensor hallucis and digitorum longus

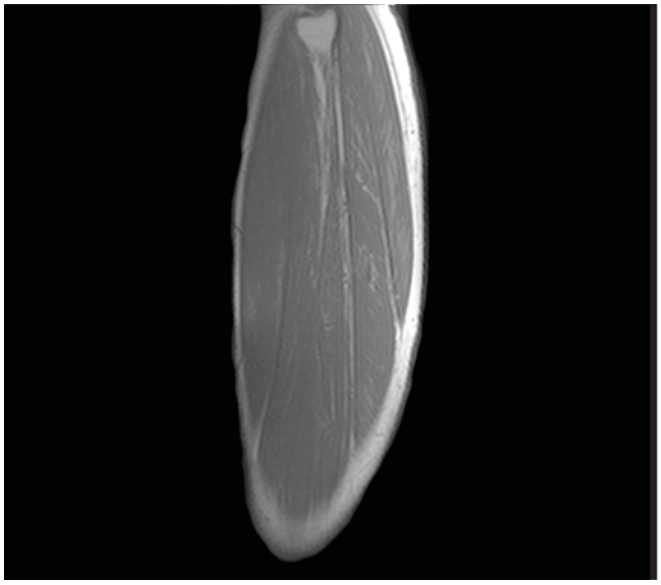

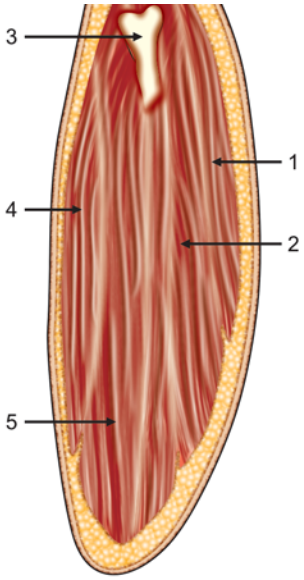

Figure 16.24

1. Gastrocnemius, lateral head
2. Soleus
3. Fibula
4. Extensor hallucis and digitorum longus
5. Peroneus longus and brevis

CHAPTER 17

Knee

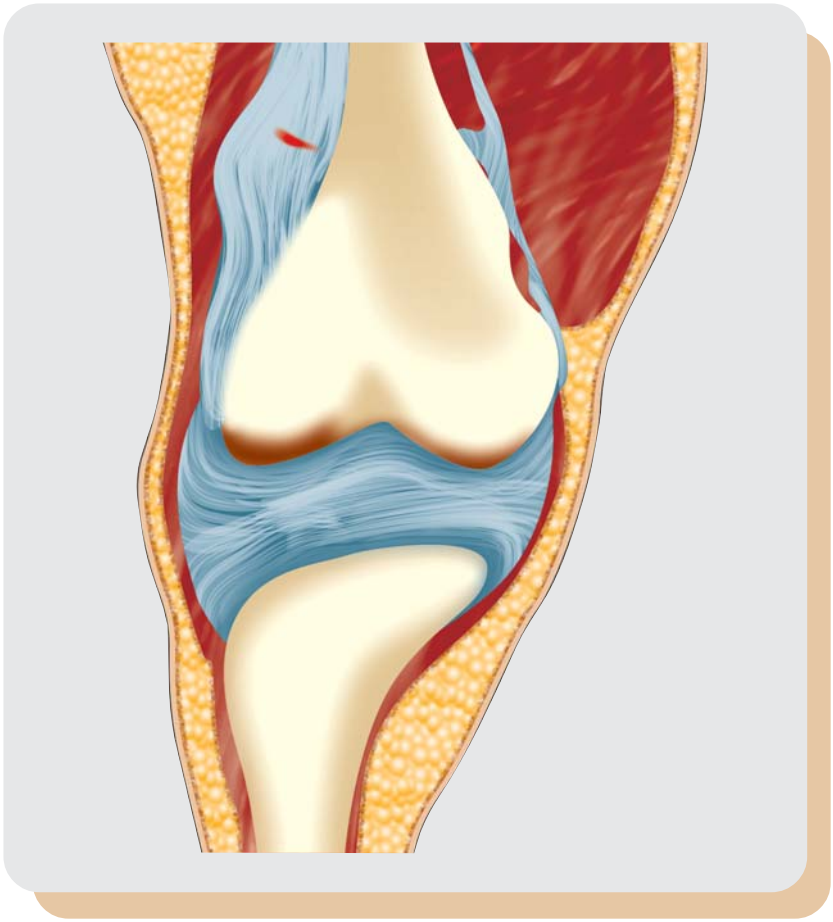

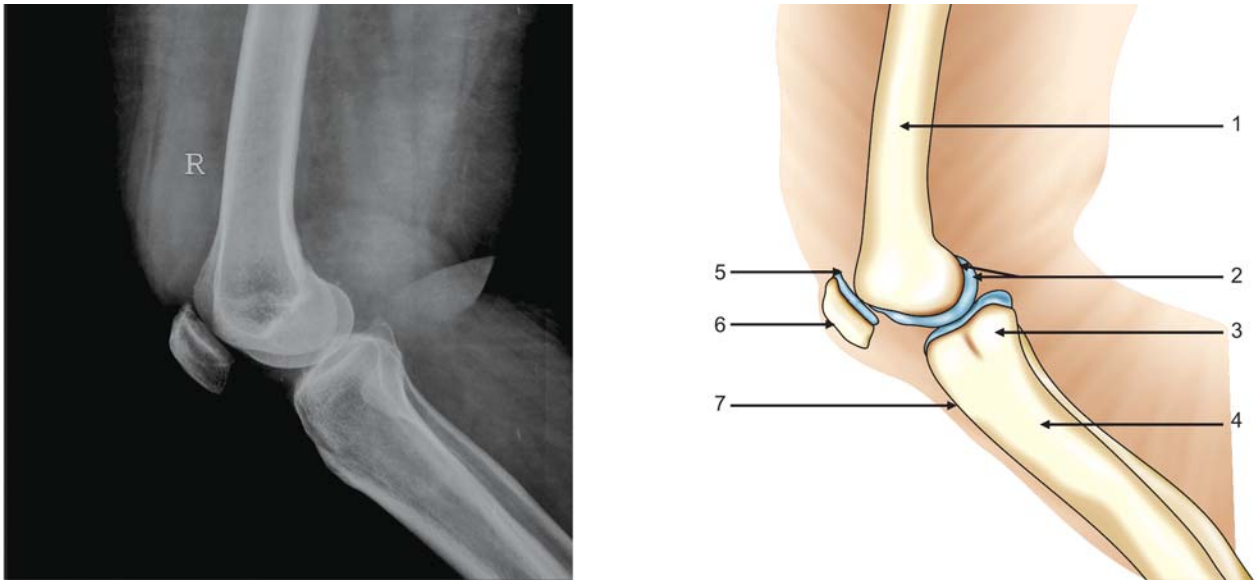

Figure 17.1

1. Femur
2. Femoral condyles
3. Fibula, head
4. Tibia
5. Patello-femoral joint
6. Patella
7. Tibial tuberosity

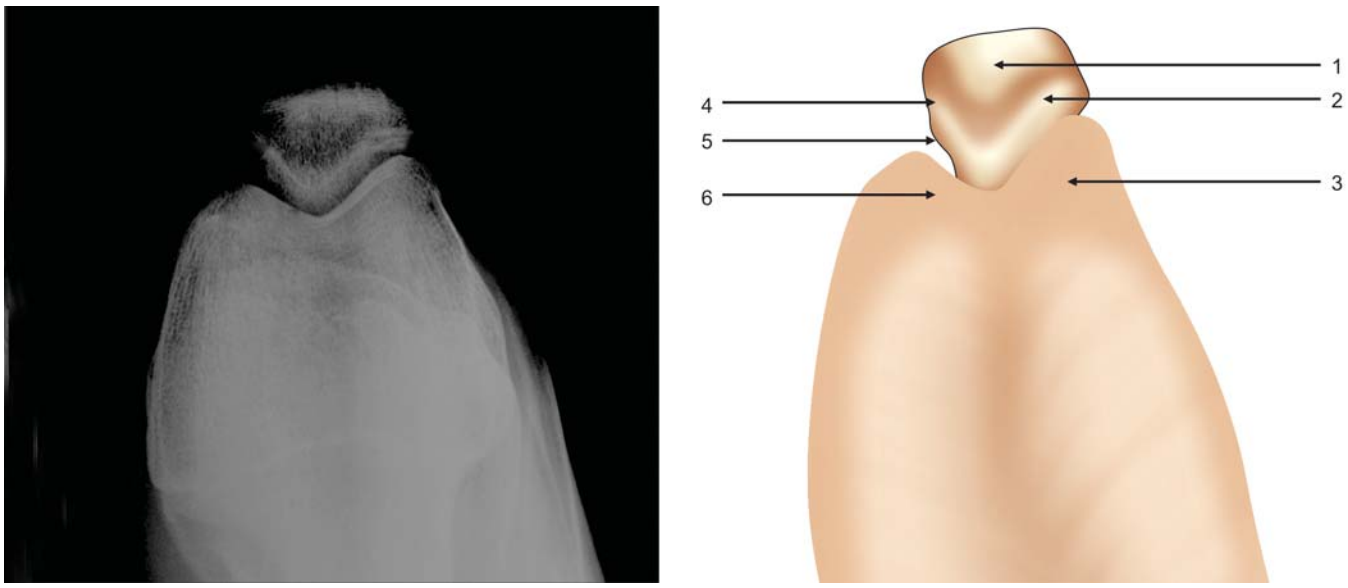

Figure 17.2

1. Patella
2. Lateral patellar facet
3. Lateral femoral condyle
4. Medial patellar facet
5. Patellofemoral joint
6. Medial femoral condyle



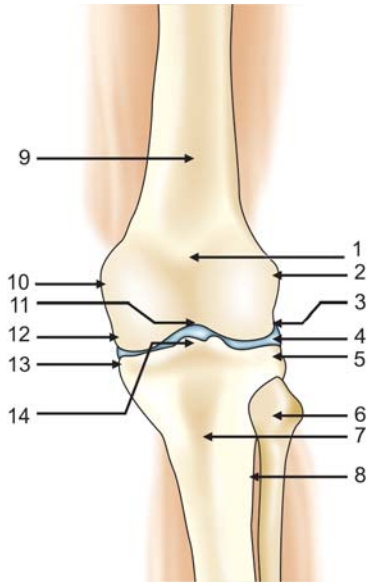

Figure 17.3

1. Patella
2. Lateral femoral epicondyle
3. Lateral femoral condyle
4. Joint space
5. Lateral tibial condyle
6. Fibular head
7. Tibia
8. Interosseous membrane
9. Femur
10. Medial femoral epicondyle
11. Intercondylar fossa
12. Medial femoral condyle
13. Medial tibial condyle
14. Tibial tubercle

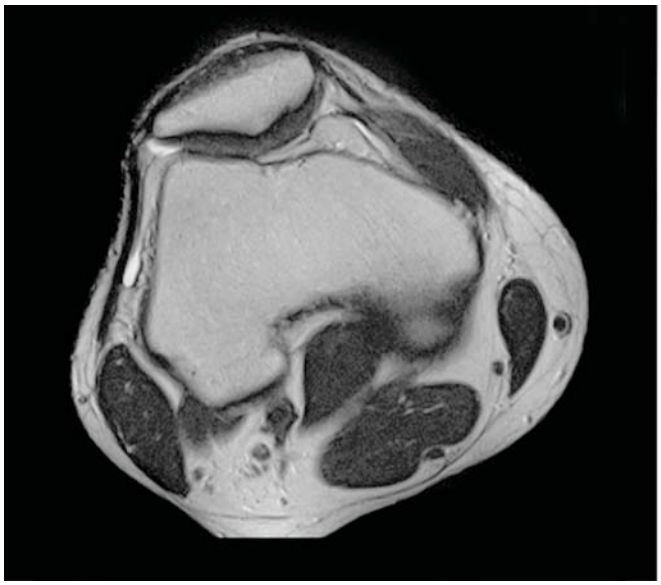

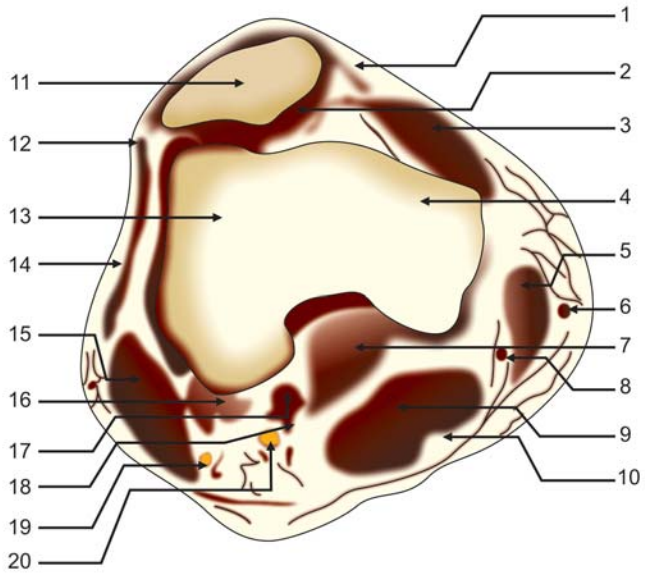

Figure 17.4

1. Medial patellar retinaculum
2. Articular cartilage
3. Vastus medialis
4. Medial femoral condyle
5. Sartorius
6. Great saphenous vein
7. Gastrocnemius, medial head
8. Gracilis
9. Semimembranosus
10. Semitendinosus tendon
11. Patella
12. Lateral patellar retinaculum
13. Lateral femoral condyle
14. Ilio-tibial tract
15. Biceps
16. Gastrocnemius lateral head
17. Popliteal artery
18. Popliteal vein
19. Common peroneal nerve
20. Tibial nerve

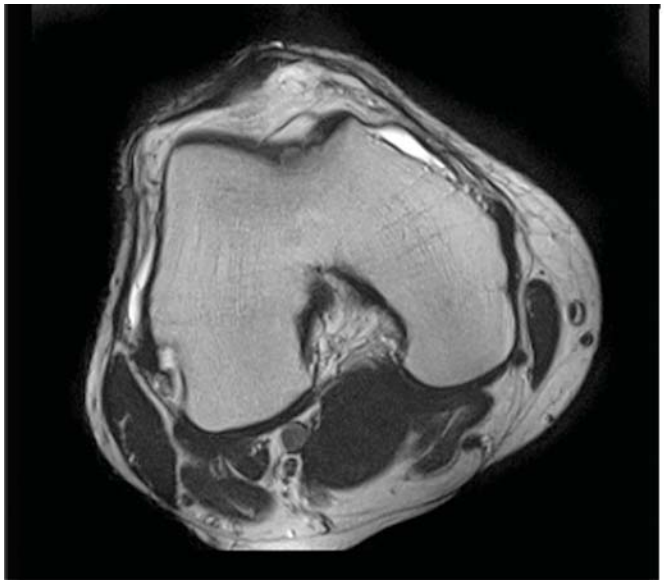

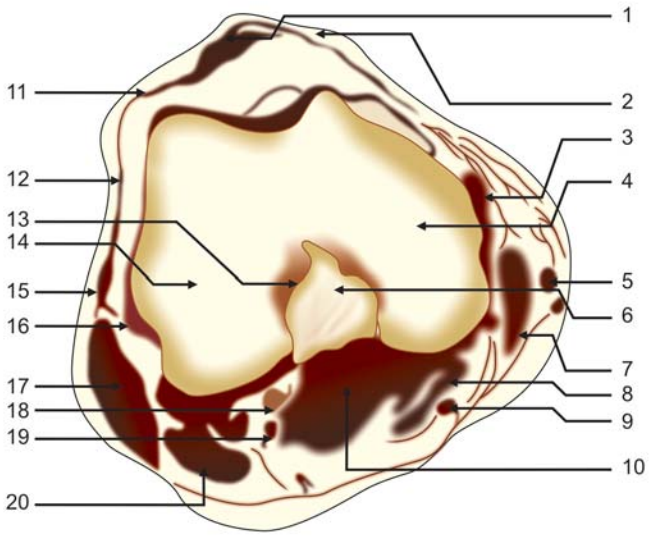

Figure 17.5

1. Patellar ligament
2. Medial patellar retinaculum
3. Medial collateral ligament
4. Medial femoral condyle
5. Great saphenous vein
6. Intercondylar notch
7. Sartorius
8. Semimembranosus
9. Semitendinosus tendon
10. Gastrocnemius, medial head
11. Lateral patellar retinaculum
12. Iliotibial tract
13. Anterior cruciate ligament
14. Lateral femoral condyle
15. Lateral collateral ligament
16. Popliteus tendon
17. Biceps
18. Popliteal artery
19. Popliteal vein
20. Gastrocnemius, lateral head

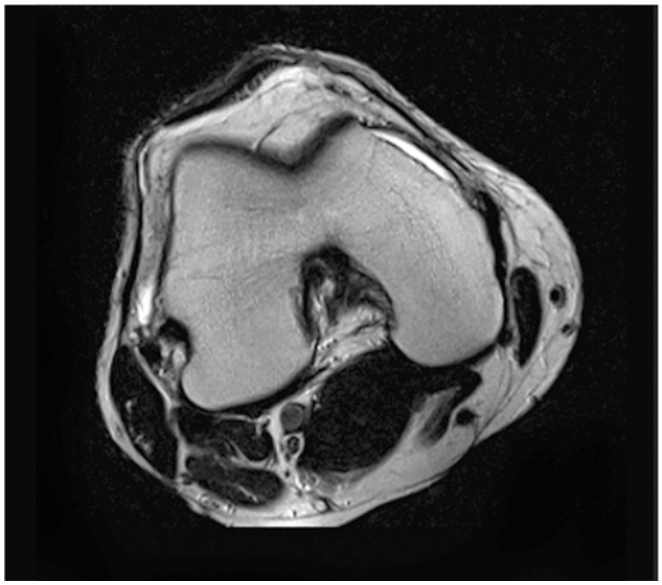

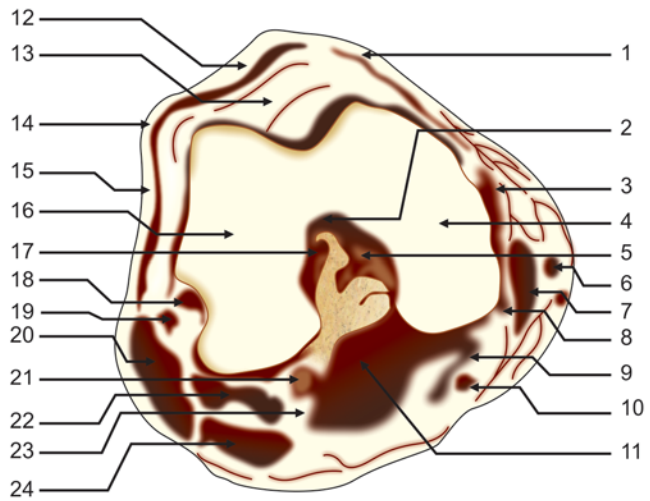

Figure 17.6

1. Medial patellar retinaculum
2. Intercondylar notch
3. Medial collateral ligament
4. Medial femoral condyle
5. Posterior cruciate ligament
6. Great saphenous vein
7. Sartorius
8. Gracilis
9. Semimembranosus
10. Semitendinosus tendon
11. Gastrocnemius, medial head
12. Patellar ligament
13. Infrapatellar fat
14. Lateral patellar retinaculum
15. Ilio-tibial tract
16. Lateral femoral condyle
17. Anterior cruciate ligament
18. Popliteus tendon
19. Lateral collateral ligament
20. Biceps
21. Popliteal artery
22. Plantaris
23. Tibial nerve
24. Gastrocnemius, lateral head



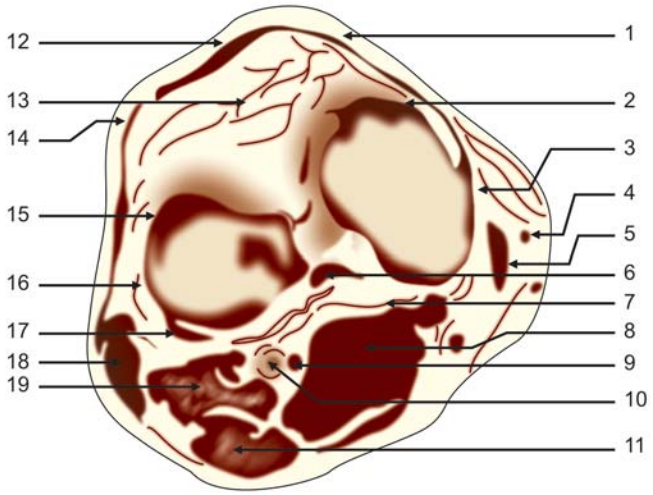

Figure 17.7

1. Medial patellar retinaculum
2. Medial meniscus
3. Medial collateral ligament
4. Great saphenous vein
5. Gracilis
6. Posterior cruciate ligament
7. Posterior joint capsule
8. Gastrocnemius, medial head
9. Popliteal vein
10. Popliteal artery
11. Gastrocnemius, lateral head
12. Patellar ligament
13. Infrapatellar Hoffa's fat pad
14. Lateral patellar retinaculum
15. Lateral meniscus
16. Lateral collateral ligament
17. Popliteus tendon
18. Biceps
19. Plantaris

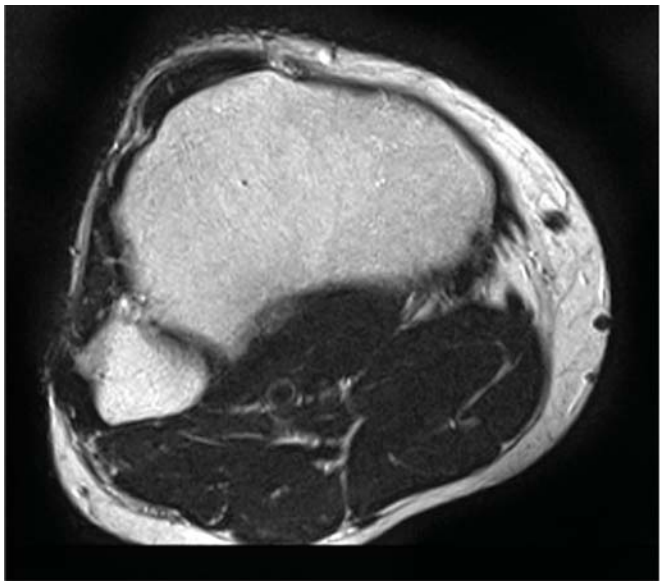

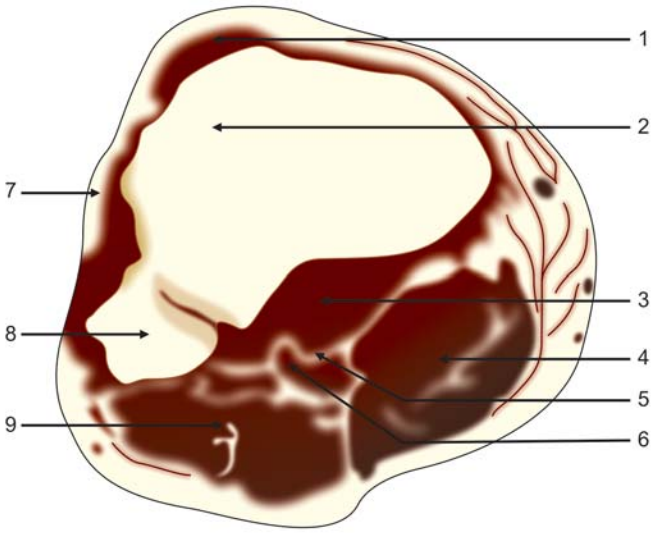

Figure 17.8

1. Patellar ligament
2. Tibia
3. Popliteus
4. Gastrocnemius medial head
5. Popliteal vein
6 Popliteal artery
7 Iliotibial tract
8. Fibula
9. Gastrocnemius lateral head

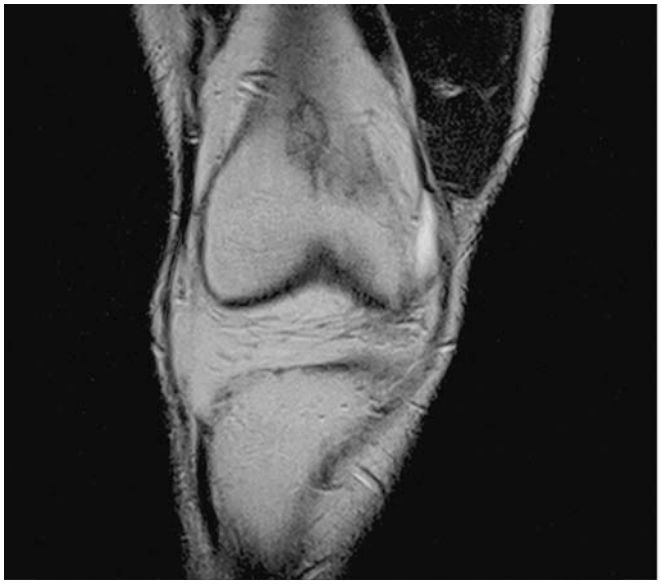

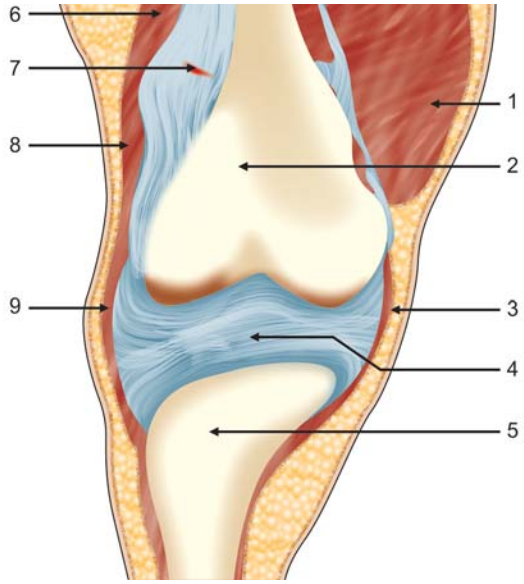

Figure 17.9

1. Vastus medialis
2. Femur
3. Medial patellar retinaculum
4. Infrapatellar fat
5. Tibia
6. Vastus lateralis
7. Superior lateral geniculate artery
8. Iliotibial tract
9. Lateral patellar retinaculum



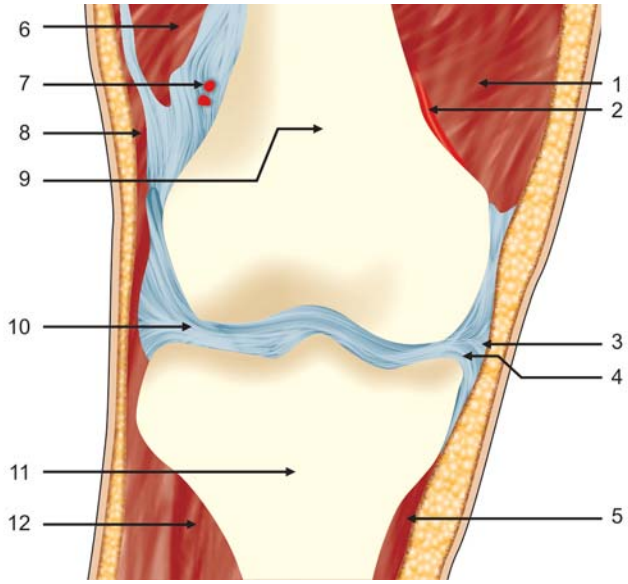

Figure 17.10

1. Vastus medialis
2. Superior medial genicular artery
3. Medial collateral ligament
4. Medial meniscus anterior horn
5. Pes anserinus
6. Vastus lateralis
7. Superior lateral genicular artery
8. Ilio-tibial tract
9. Femur
10. Lateral meniscus, anterior horn
11. Tibia
12. Extensor digitorum longus

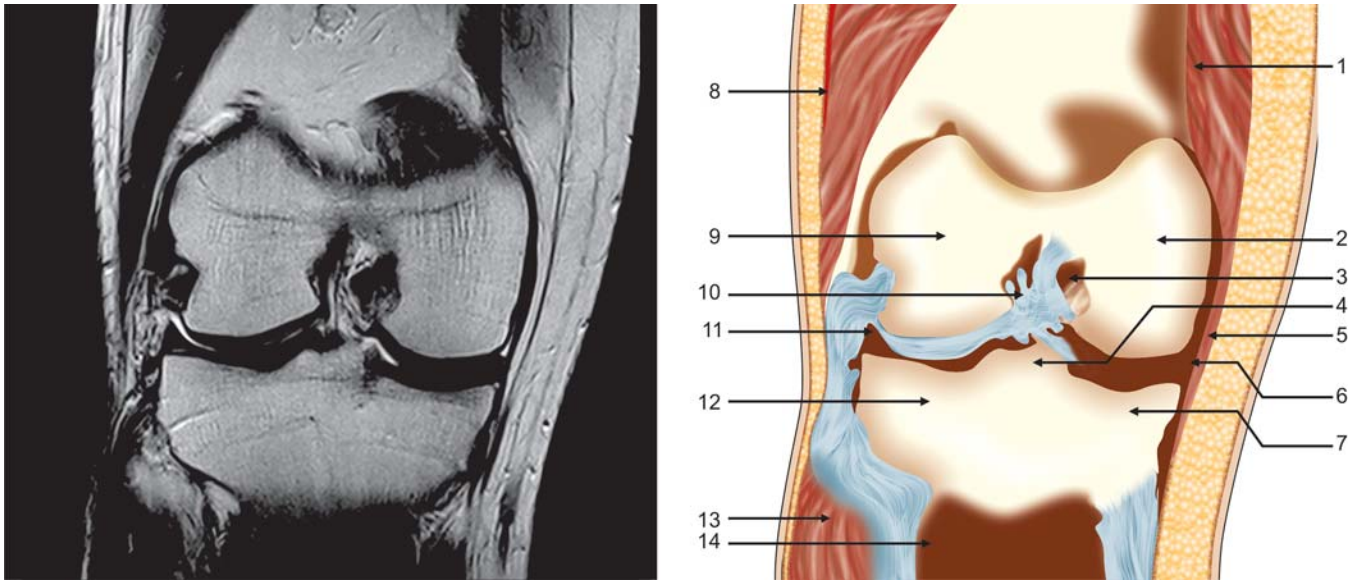

Figure 17.11

1. Vastus medialis
2. Femoral condyle (medial)
3. Posterior cruciate ligament
4. Tibial tubercles
5. Medial collateral ligament
6. Medial meniscus
7. Tibial condyle (medial)
8. Iliotibial tract
9. Femoral condyle (lateral)
10. Anterior cruciate ligament
11. Lateral meniscus
12. Tibial condyle (lateral)
13. Extensor digitorum longus
14. Tibialis posterior

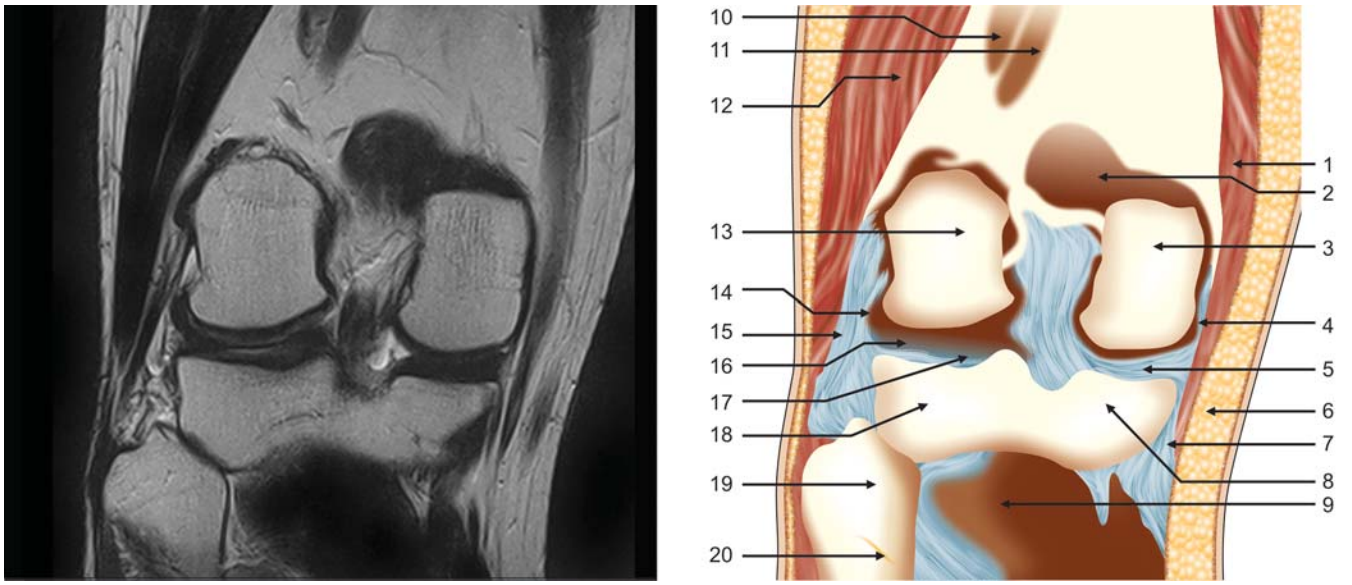

Figure 17.12

1. Sartorius
2. Gastrocnemius, medial head
3. Medial femoral condyle
4. Medial collateral ligament
5. Medial meniscus
6. Great saphenous vein
7. Gracilis tendon
8. Medial tibial condyle
9. Popliteus
10. Popliteal vein
11. Popliteal artery
12. Biceps femoris
13. Lateral femoral condyle
14. Popliteus tendon
15. Lateral collateral ligament
16. Lateral meniscus
17. Articular cartilage
18. Lateral tibial condyle
19. Fibula
20. Common peroneal nerve

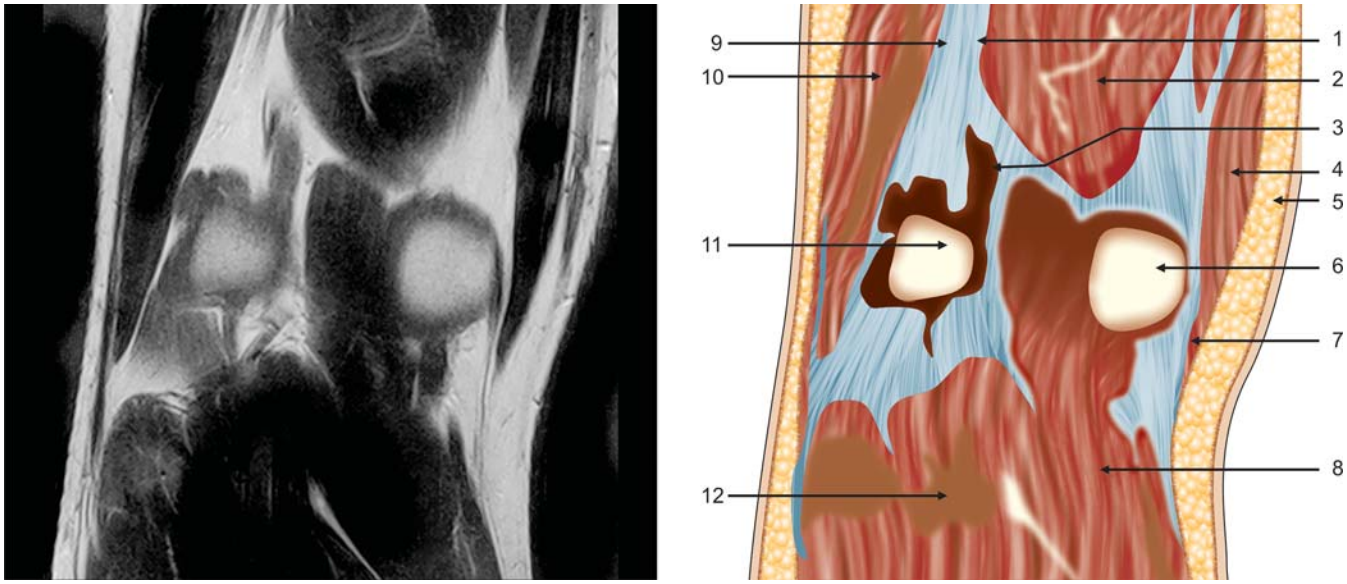

Figure 17.13

1. Tibial nerve
2. Semimembranosus
3. Popliteal artery
4. Sartorius
5. Great saphenous vein
6. Medial femoral condyle
7. Gracilis tendon
8. Gastrocnemius, medial head
9. Common peroneal nerve
10. Biceps femoris
11. Lateral femoral condyle
12. Gastrocnemius, lateral head

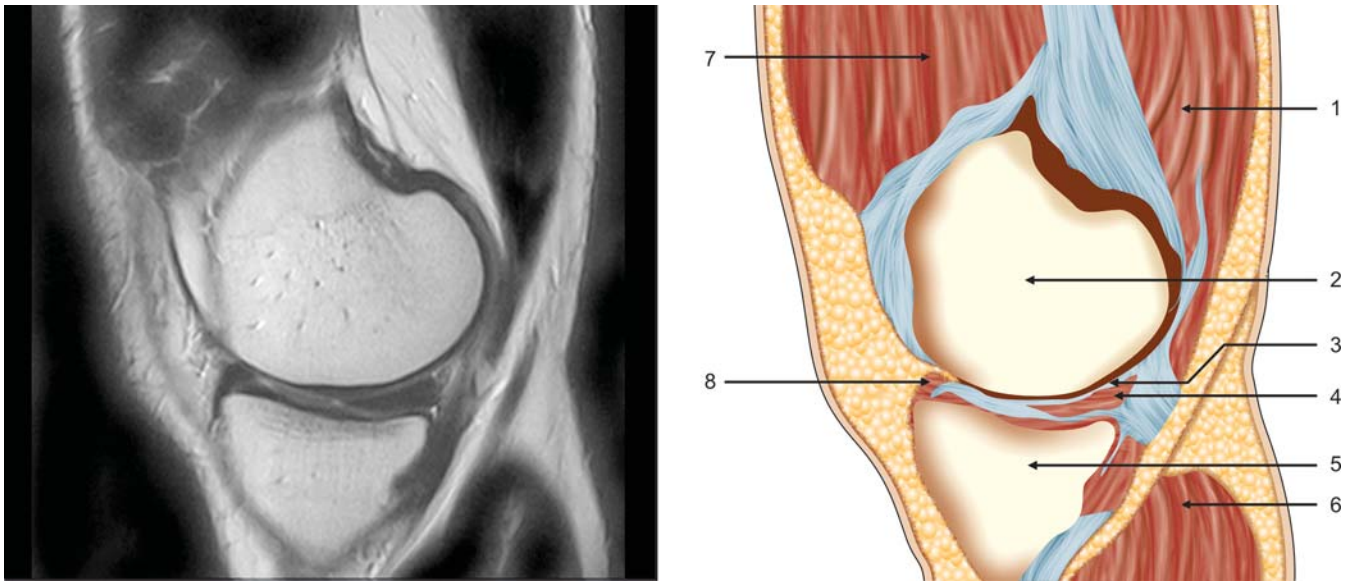

Figure 17.14

1. Semimembranosus
2. Medial femoral condyle
3. Articular cartilage
4. Medial meniscus, posterior horn
5. Medial tibial condyle
6. Gastrocnemius (medial head)
7. Vastus medialis
8. Medial meniscus, anterior horn

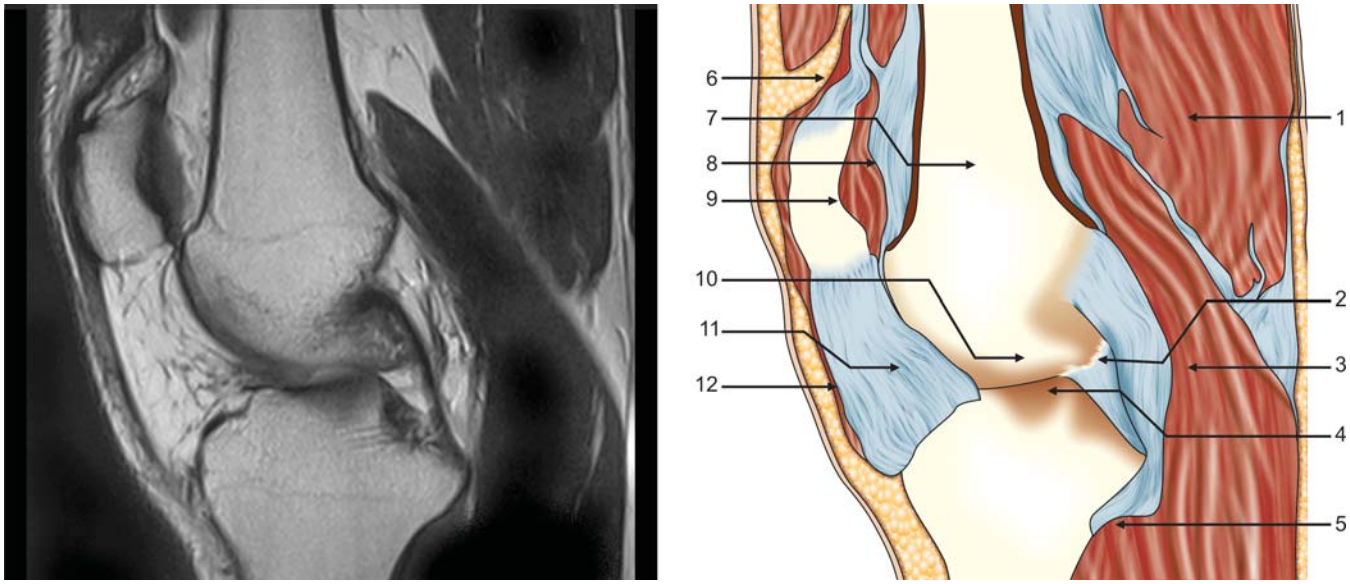

Figure 17.15

1. Semimembranosus
2. Posterior cruciate ligament
3. Gastrocnemius (medial head)
4. Medial intercondylar eminence
5. Popliteus
6. Quadriceps tendon
7. Femur
8. Articular cartilage
9. Patella
10. Anterior cruciate ligament
11. Hoffa's fat pad
12. Patellar ligament

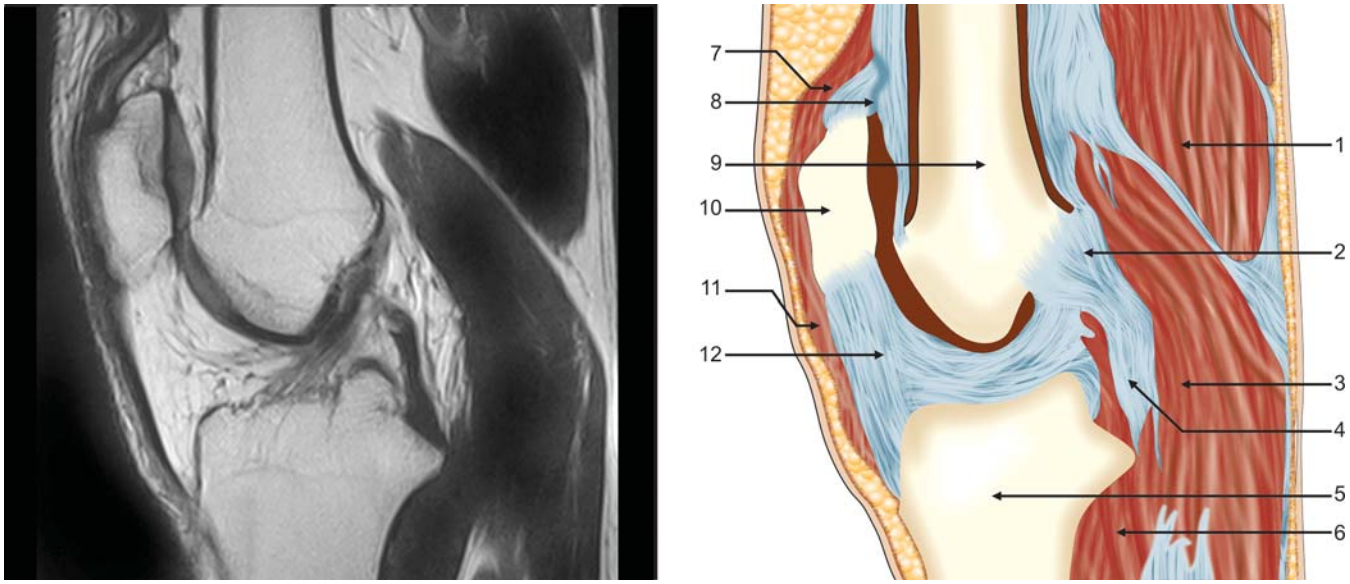

Figure 17.16

1. Semimembranosus
2. Intercondylar shelf
3. Gastrocnemius (medial head)
4. Posterior cruciate ligament
5. Tibia
6. Popliteus
7. Quadriceps tendon
8. Synovial space
9. Femur
10. Patella
11. Patellar ligament
12. Hoffa's fat pad

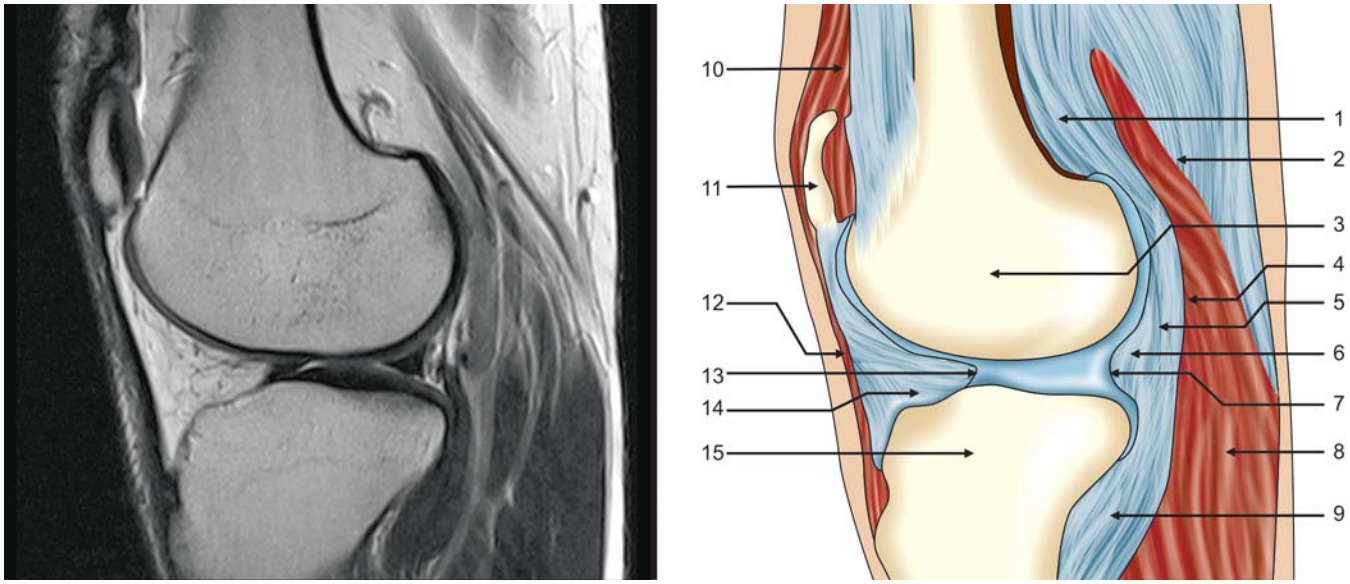

Figure 17.17

1. Superior lateral genicular artery
2. Tibial nerve
3. Femoral condyle (lateral)
4. Popliteal vein
5. Popliteal artery
6. Posterior joint capsule
7. Lateral meniscus, posterior horn
8. Gastrocnemius (lateral head)
9. Popliteus
10. Quadriceps tendon
11. Patella
12. Patellar ligament
13. Lateral meniscus, anterior horn
14. Hoffa's fat pad
15. Tibial condyle (lateral)

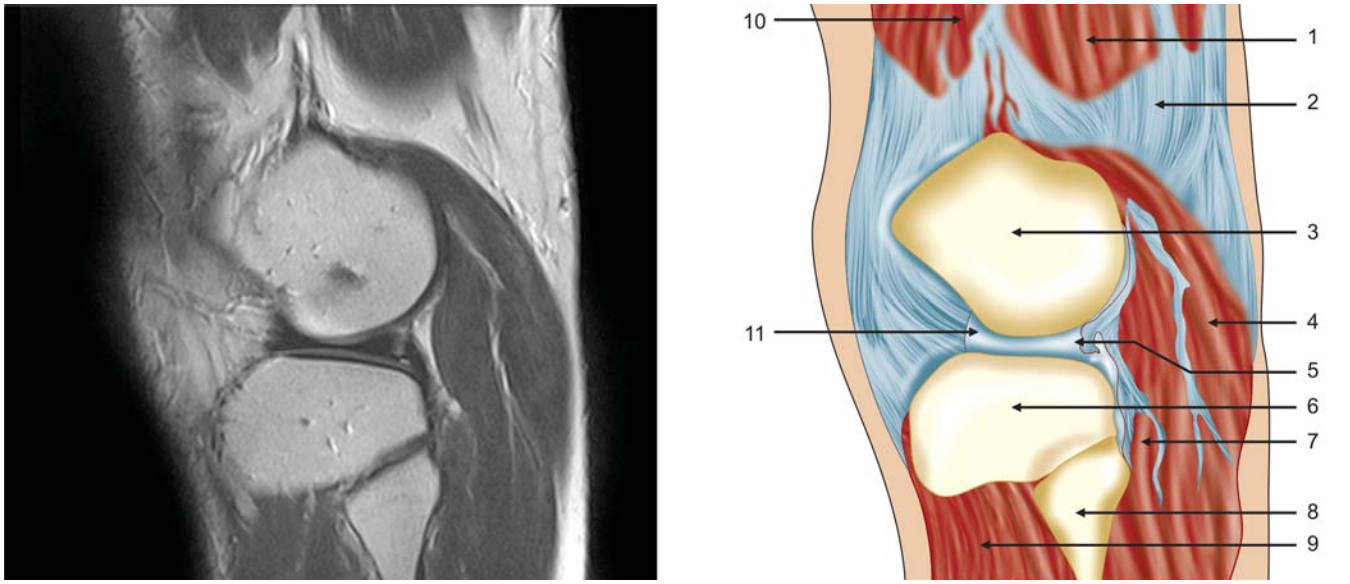

Figure 17.18

1. Biceps femoris
2. Common peroneal nerve
3. Femoral condyle (lateral)
4. Gastrocnemius (lateral head)
5. Lateral meniscus, posterior horn
6. Tibial condyle (lateral)
7. Popliteus
8. Fibula
9. Tibialis anterior
10. Vastus lateralis
11. Lateral meniscus, anterior horn

CHAPTER 18

Ankle and Foot

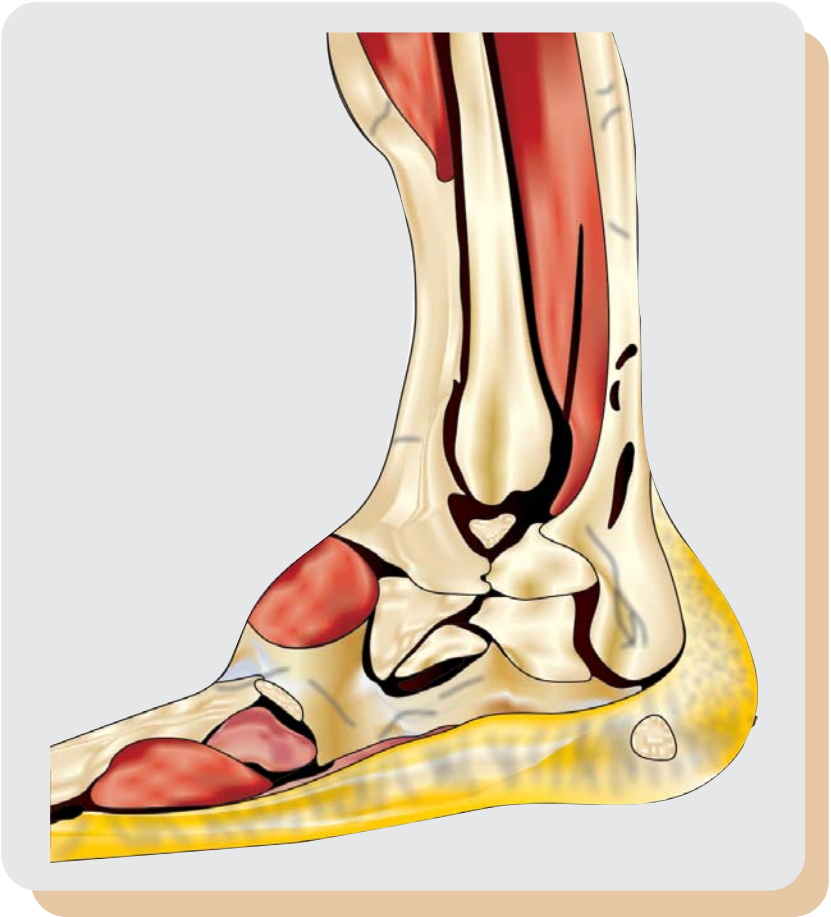

X-RAY FIGURES



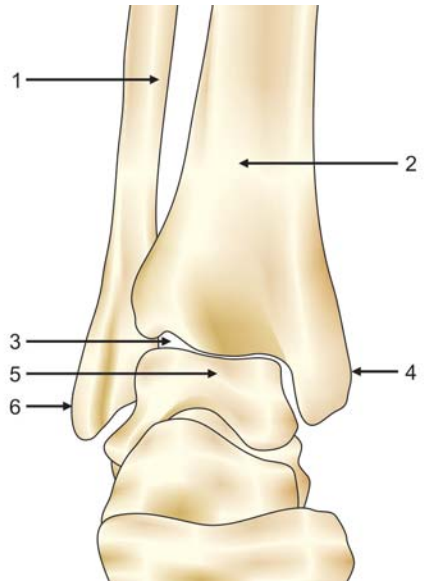

Figure 18.1

1. Fibula
2. Tibia
3. Tibiotalar joint space
4. Medial malleolus
5. Talus
6. Lateral malleolus



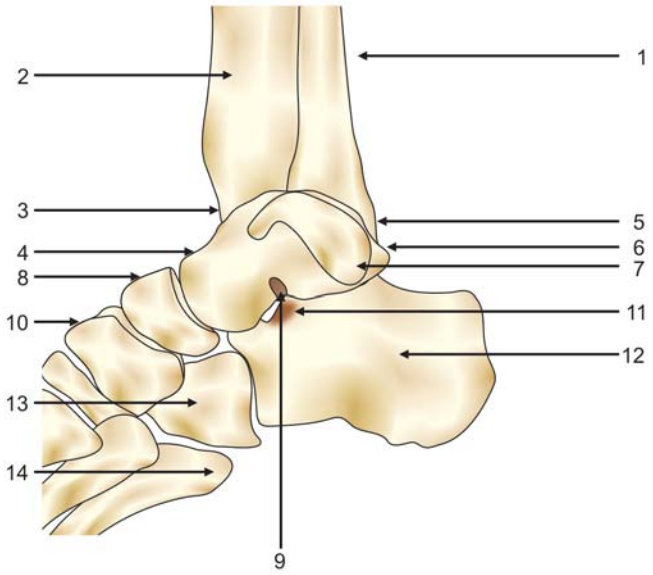

Figure 18.2

1. Fibula
2. Tibia
3. Medial malleolus
4. Head of talus
5. Lateral malleolus
6. Lateral tubercle of talus
7. Medial tubercle of talus
8. Navicular
9. Sinus tarsi
10. Lateral cuneiform
11. Sustentaculum tali
12. Calcaneus
13. Cuboid
14. Base of fifth metatarsal



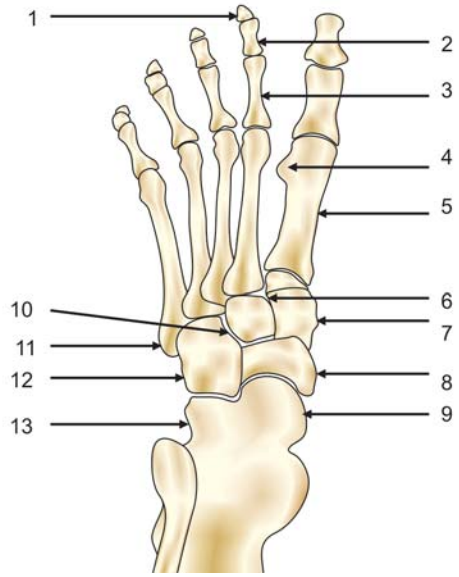

Figure 18.3

1. Distal phalanx of second toe
2. Middle phalanx of second toe
3. Proximal phalanx of second toe
4. Sesamoid bone
5. First metatarsal
6. Intermediate cuneiform
7. Medial cuneiform
8. Navicular
9. Talus
10. Lateral cuneiform
11. Tuberosity of base of fifth metatarsal
12. Cuboid
13. Calcaneus



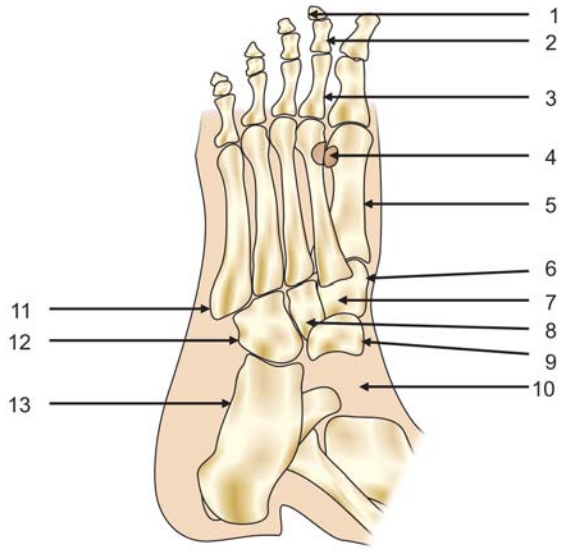

Figure 18.4

1. Distal phalanx of second toe
2. Middle phalanx of second toe
3. Proximal phalanx of second toe
4. Sesamoid bone
5. First metatarsal
6. Medial cuneiform
7. Intermediate cuneiform
8. Lateral cuneiform
9. Navicular
10. Talus
11. Tuberosity of base of fifth metatarsal
12. Cuboid
13. Calcaneus

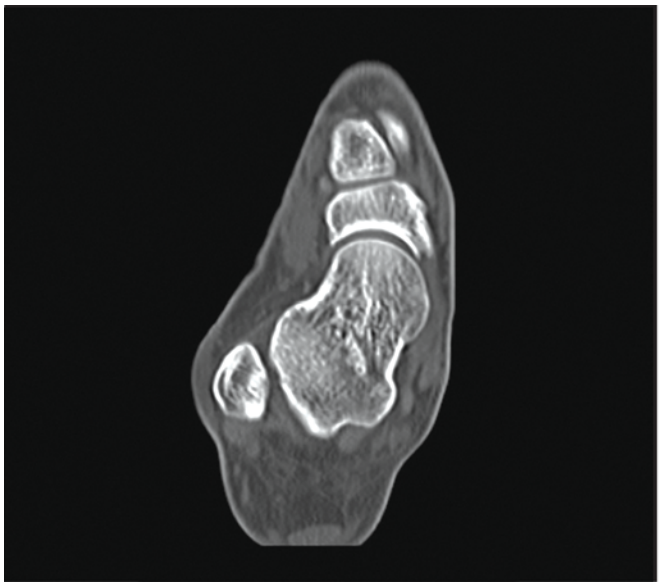

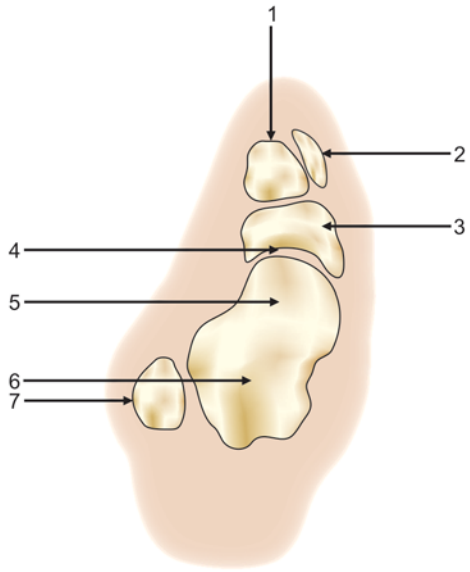

Figure 18.5

1. Intermediate cuneiform
2. Medial cuneiform
3. Navicular
4. Talonavicular joint
5. Head of talus
6. Talus, body
7. Lateral malleolus

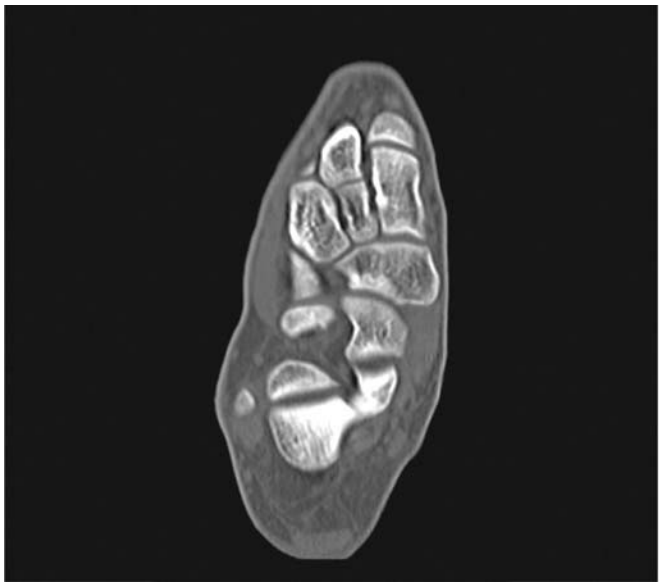

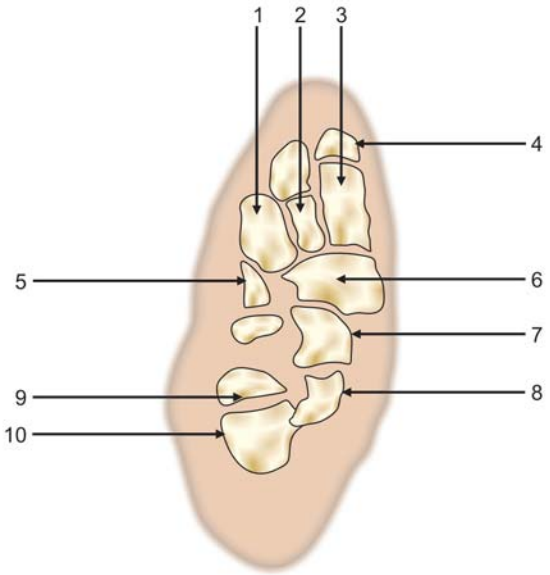

Figure 18.6

1. Lateral cuneiform
2. Intermediate cuneiform
3. Medial cuneiform
4. Base, first metatarsal
5. Cuboid
6. Navicular
7. Talus, head
8. Sustentaculum
9. Talus, posterior facet
10. Calcaneus

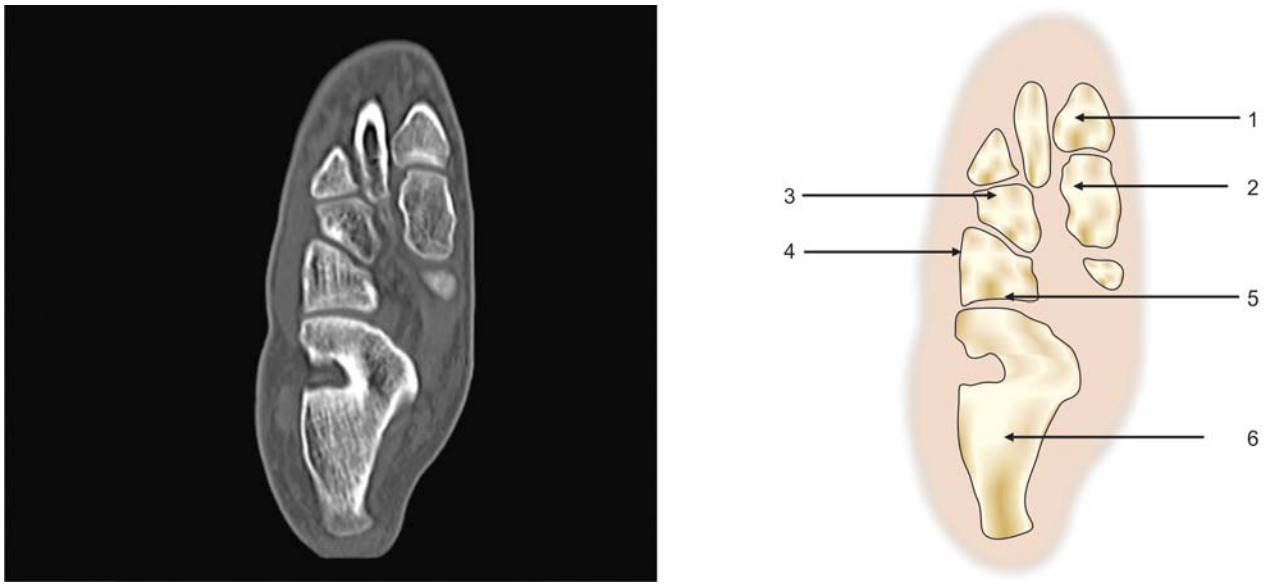

Figure 18.7

1. First metatarsal
2. Medial cuneiform
3. Lateral cuneiform
4. Cuboid
5. Calcaneocuboid joint
6. Calcaneus

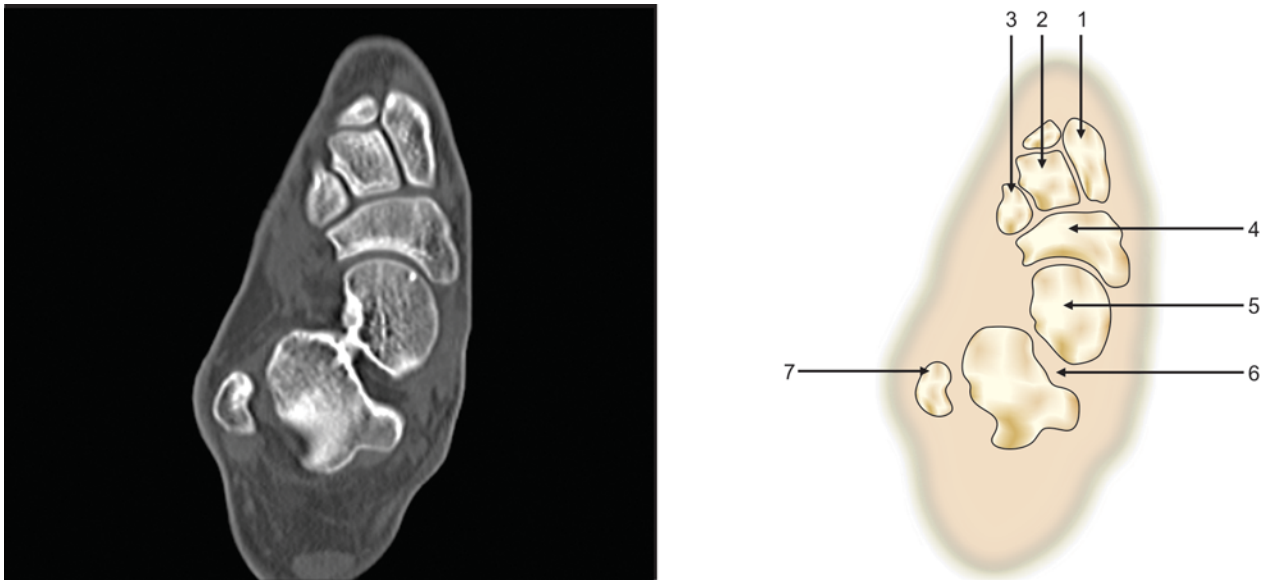

Figure 18.8

1,2,3. Cuneiform
4. Navicular
5. Head, talus
6. Tarsal sinus
7. Lateral malleolus

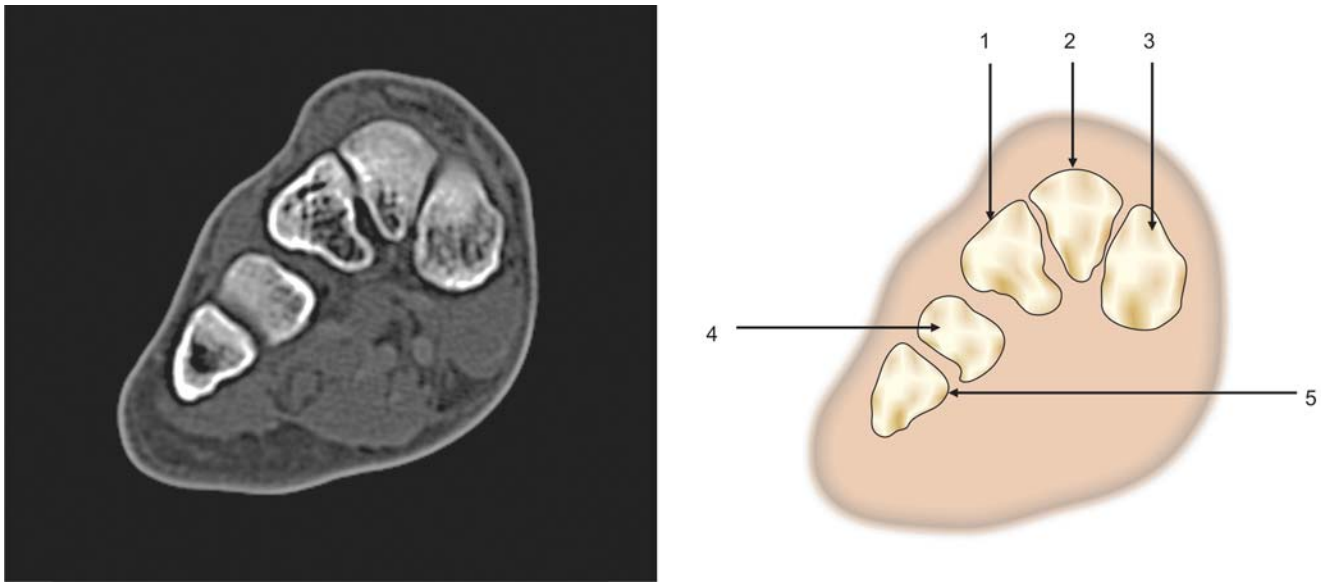

Figure 18.9

1. Lateral cuneiform
2. Intermediate cuneiform
3. Medial cuneiform
4. Cuboid
5. Fifth metatarsal

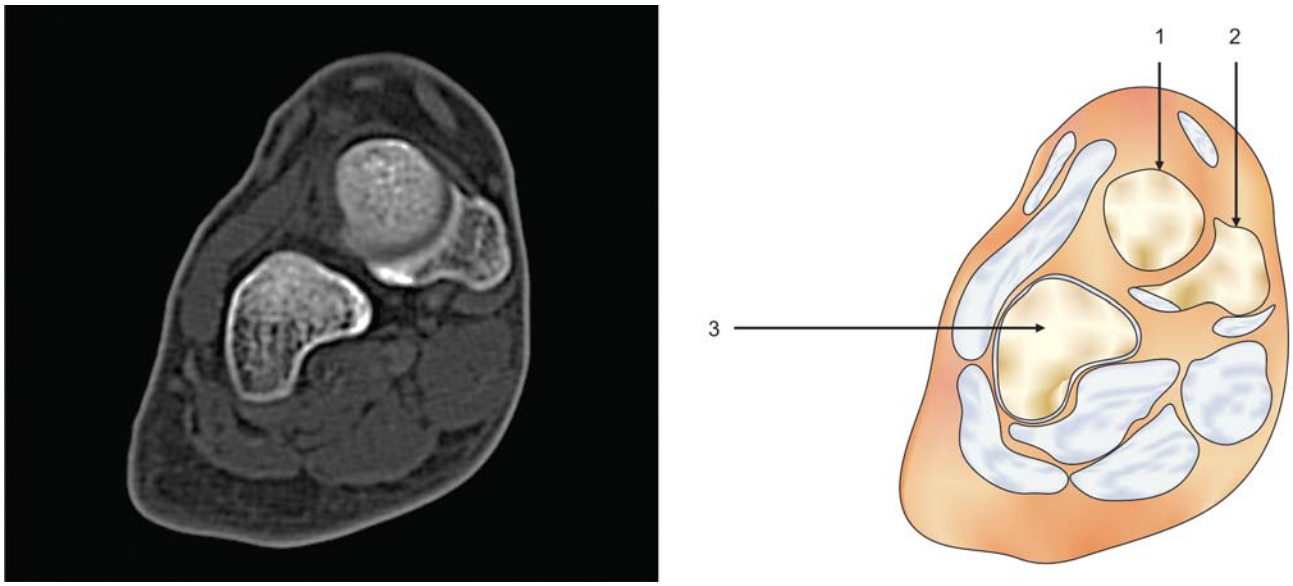

Figure 18.10

1. Talus, head
2. Navicular
3. Cuboid



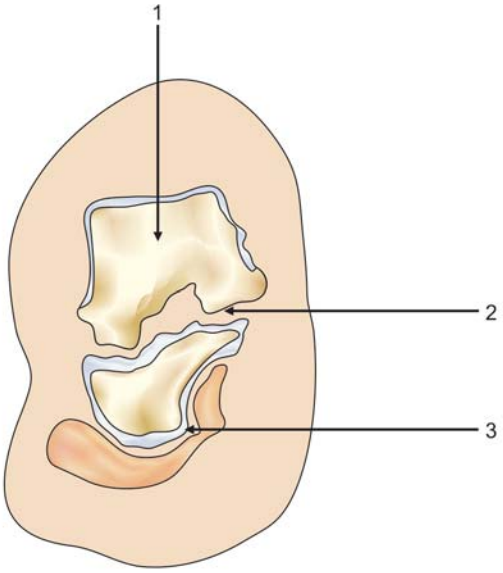

Figure 18.11

1. Talus
2. Middle facet subtalar joint
3. Calcaneus



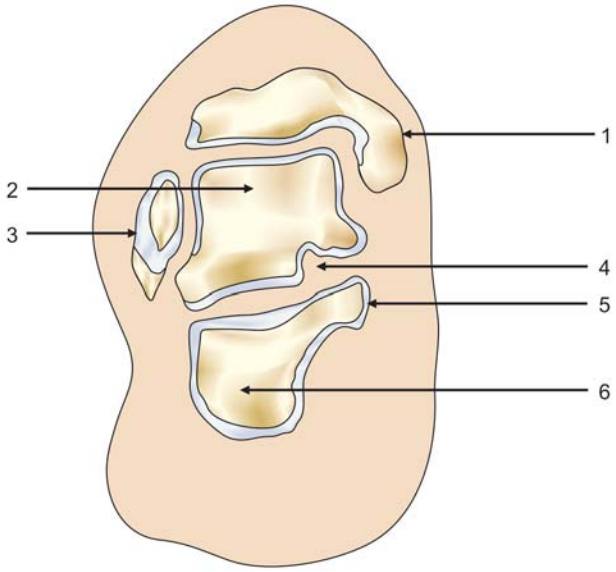

Figure 18.12

1. Medial malleolus
2. Talus, body
3. Lateral malleolus
4. Tarsal sinus
5. Sustentaculum tali
6. Calcaneus

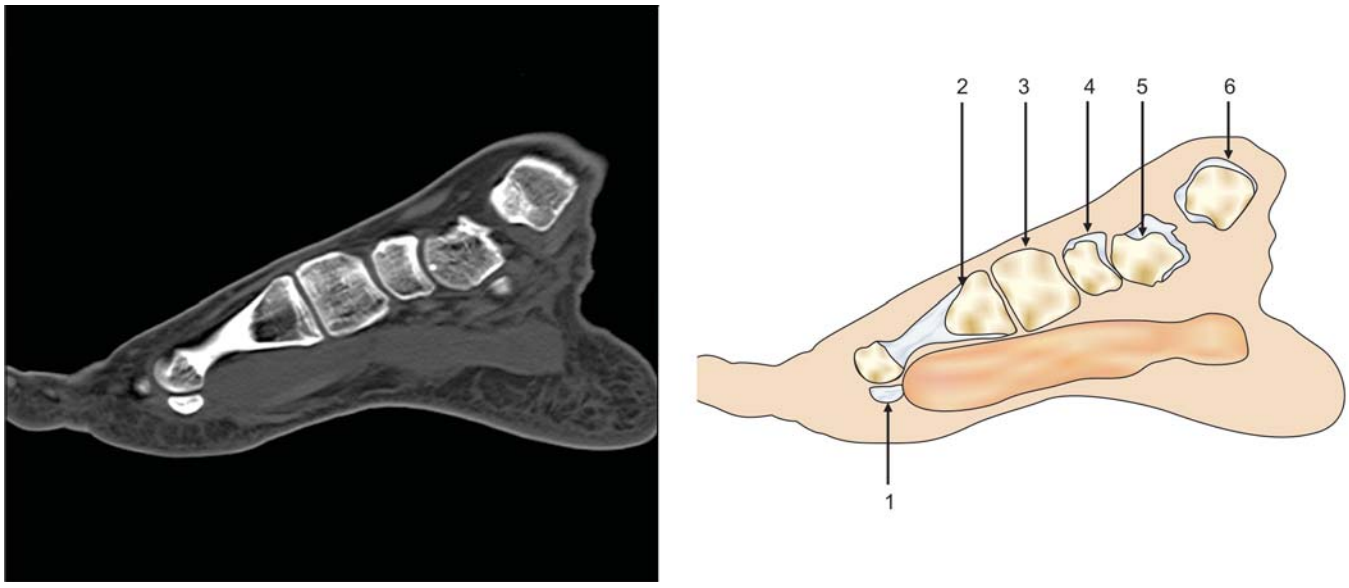

Figure 18.13

1. Sesamoid bone
2. First metatarsal
3. Medial cuneiform
4. Navicular
5. Talus
6. Medial malleolus

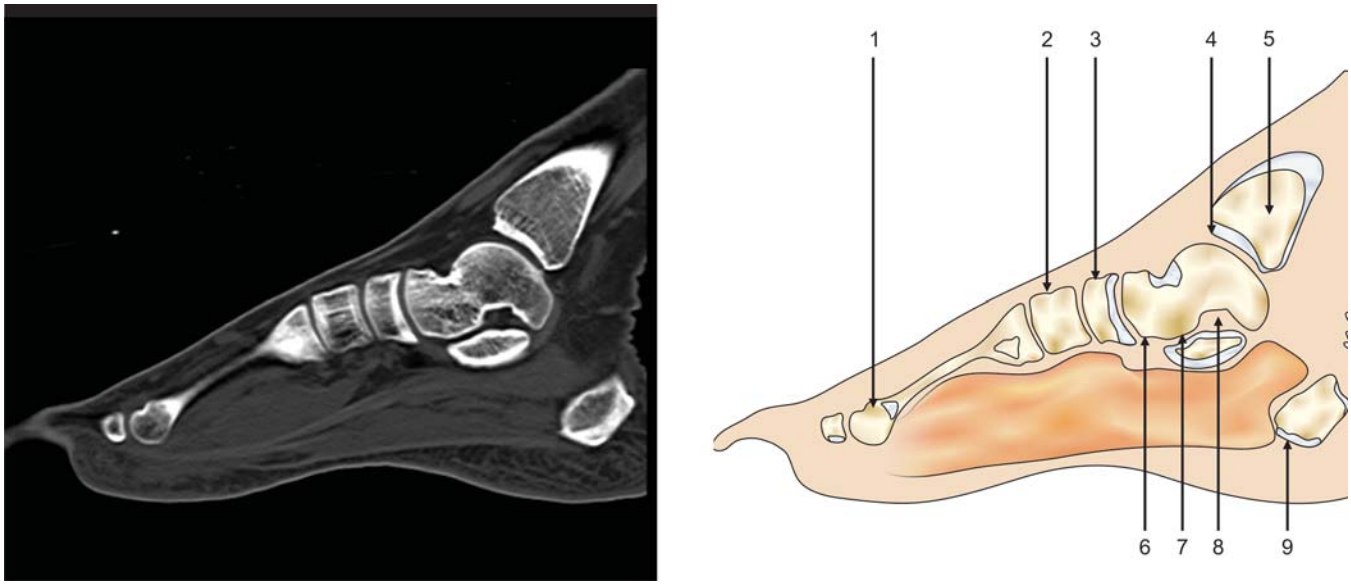

Figure 18.14

1. Second metatarsal
2. Intermediate cuneiform
3. Navicular
4. Ankle joint
5. Tibia
6. Talus, head
7. Medial subtalar joint
8. Tarsal sinus
9. Calcaneus

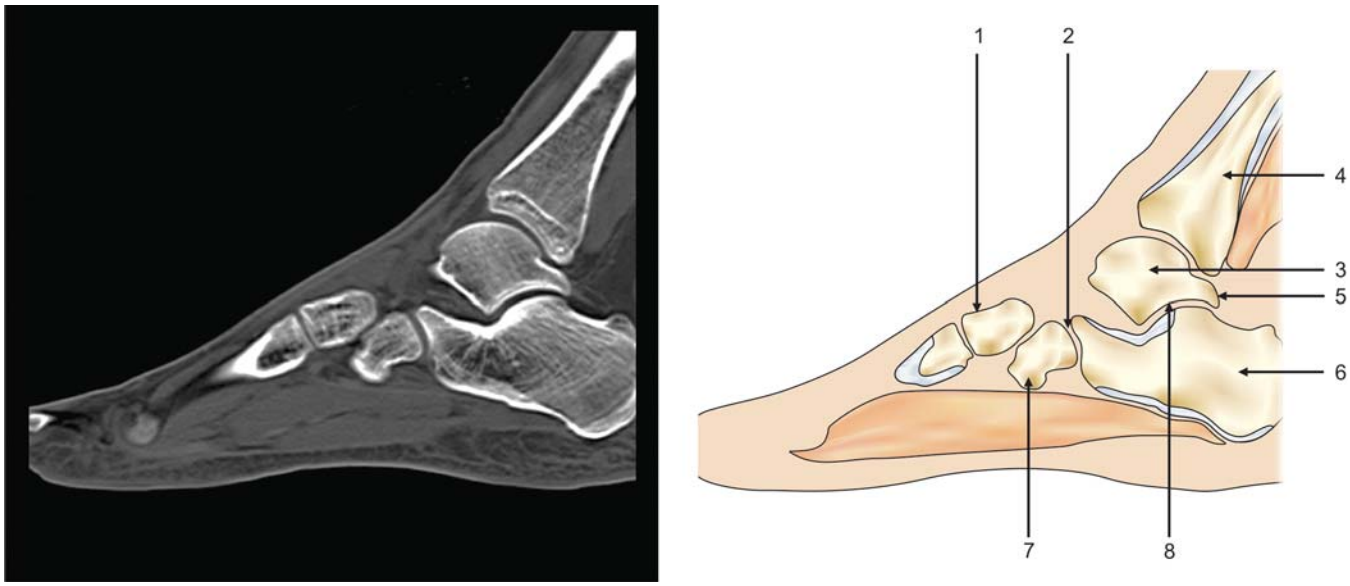

Figure 18.15

1. Lateral cuneiform
2. Calcaneocuboid joint
3. Talar dome
4. Tibia
5. Lateral talar tubercle
6. Calcaneus
7. Cuboid
8. Posterior subtalar joint

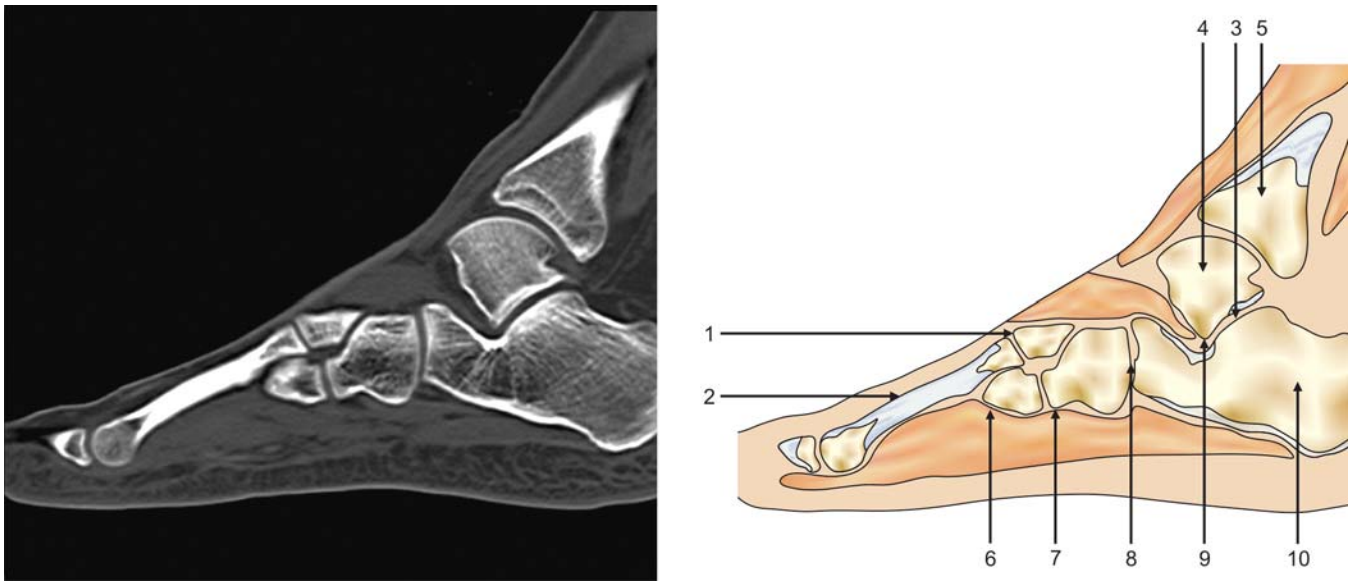

Figure 18.16

1. Lateral cuneiform
2. Third metatarsal
3. Posterior subtalar joint
4. Talar dome
5. Tibia
6. Fourth metatarsal
7. Cuboid
8. Calcaneocuboid joint
9. Lateral process, talus
10. Calcaneus

ANKLE JOINT

Axial Images

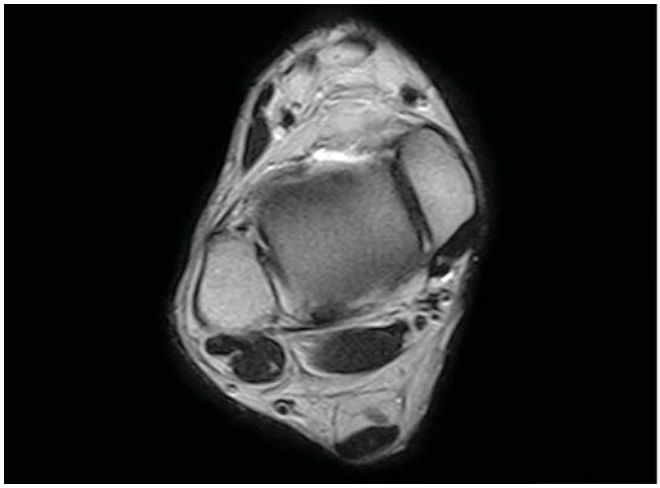

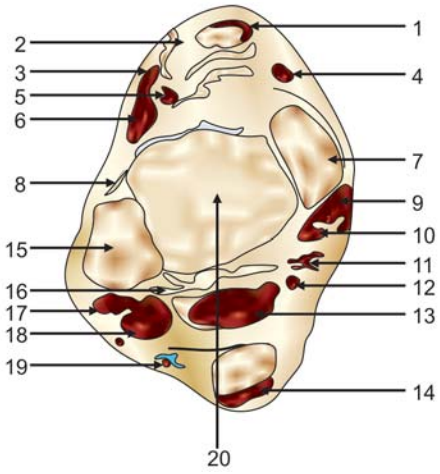

Figure 18.17

1. Tibialis anterior tendon
2. Extensor hallucis longus
3. Extensor digitorum longus
4. Great saphenous vein
5. Anterior tibial artery
6. Peroneus tertius
7. Medial malleolus
8. Anterior tibiofibular ligament
9. Tibialis posterior tendon
10. Flexor digitorum longus tendon
11. Posterior tibial artery
12. Tibial nerve
13. Flexor hallucis longus
14. Achilles tendon
15. Lateral malleolus
16. Post tibiofibular ligament
17. Peroneus longus
18. Peroneus brevis
19. Lesser saphenous vein
20. Tibiotalar joint

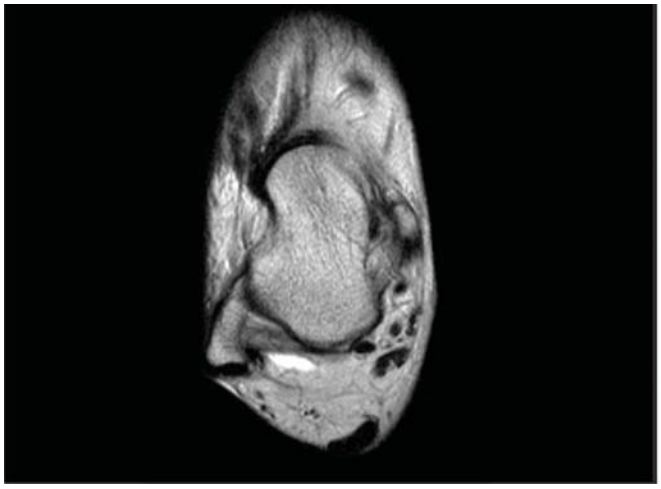

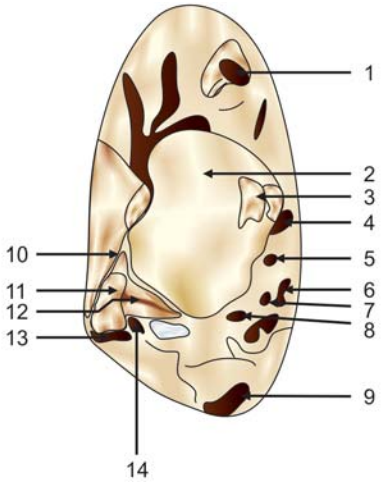

Figure 18.18

1. Tibialis anterior tendon
2. Talus
3. Deltoid ligament
4. Tibialis posterior tendon
5. Flexor digitorum longus
6. Posterior tibial artery
7. Tibial nerve
8. Flexor hallucis longus tendon
9. Achilles tendon
10. Anterior talofibular ligament
11. Lateral malleolus
12. Posterior talofibular ligament
13. Peroneus longus
14. Peroneus brevis

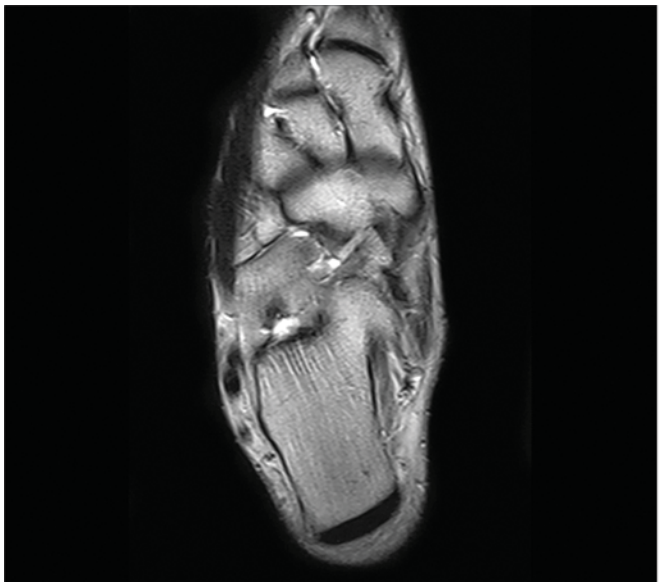

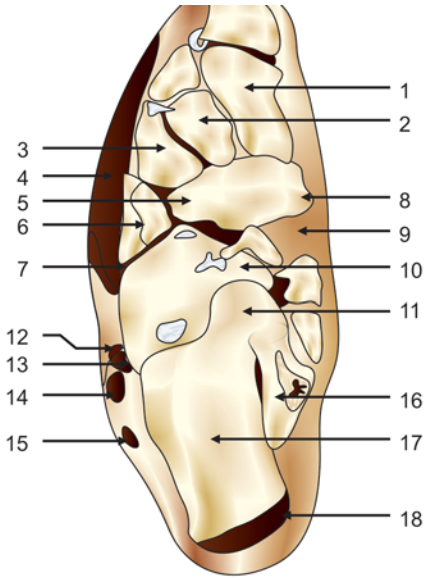

Figure 18.19

1. Medial cuneiform
2. Intermediate cuneiform
3. Lateral cuneiform
4. Extensor digitorum brevis
5. Talus, head
6. Cuboid
7. Calcaneocuboid joint
8. Navicular
9. Tibialis posterior
10. Calcaneonavicular (spring) ligament
11. Sustentaculum tali
12. Peroneus brevis
13. Calcaneofibular ligament
14. Peroneus longus
15. Lesser saphenous vein
16. Quadratus plantae
17. Calcaneus
18. Achilles tendon



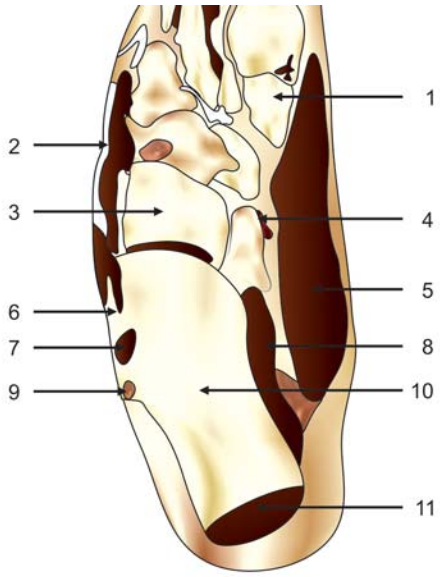

Figure 18.20

1. Medial cuneiform
2. Extensor digitorum brevis
3. Cuboid
4. Flexor hallucis longus tendon
5. Abductor hallucis
6. Peroneus brevis
7. Peroneus longus
8. Quadratus plantae
9. Calcaneofibular ligament
10. Calcaneus
11. Calcaneal tuberosity

Coronal Images

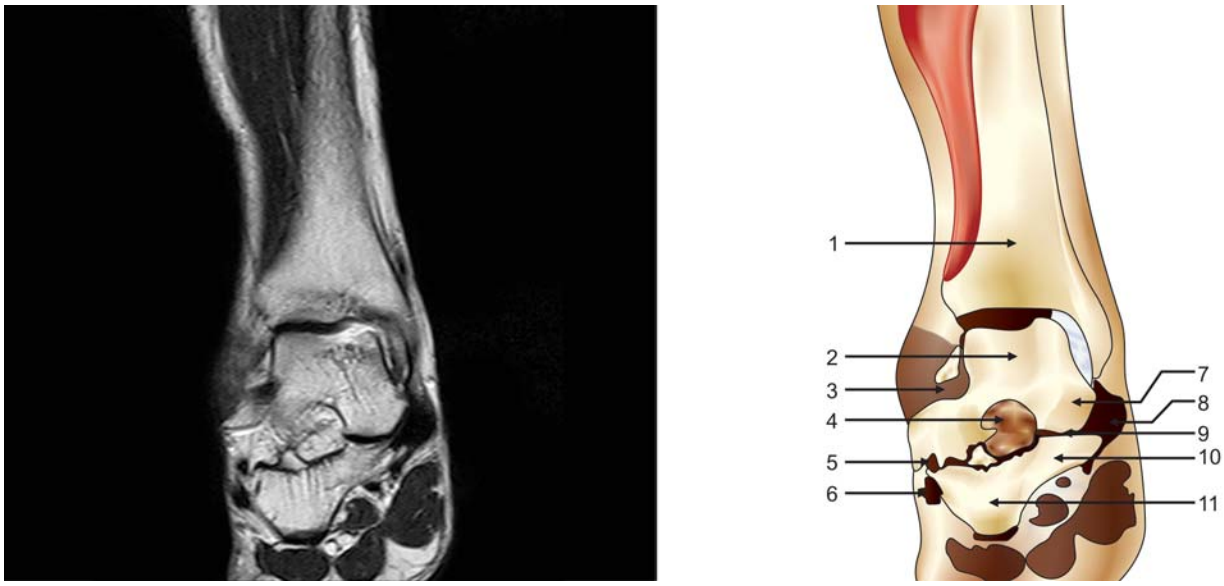

Figure 18.21

1. Tibia
2. Talus
3. Anterior talofibular ligament
4. Tarsal sinus
5. Peroneus brevis
6. Peroneus longus
7. Middle facet of talus
8. Tibialis posterior
9. Middle subtalar joint
10. Sustentaculum tali
11. Calcaneum

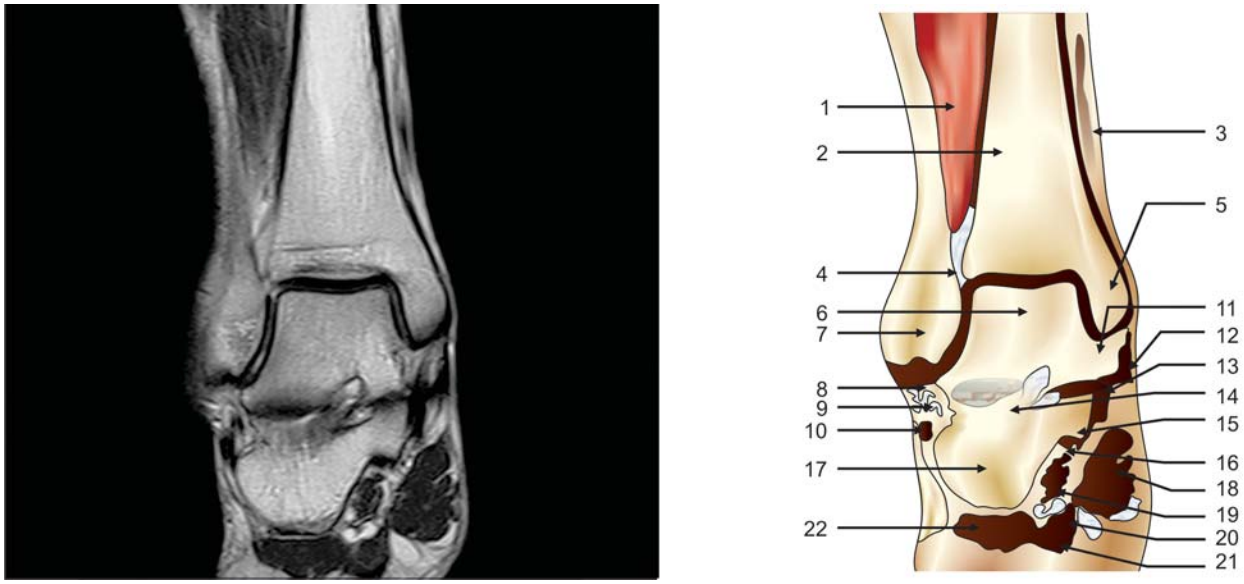

Figure 18.22

1. Extensor hallucis and digitorum longus
2. Tibia
3. Great saphenous vein
4. Anterior tibiofibular ligament
5. Medial malleolus
6. Talus, body
7. Lateral malleolus
8. Calcaneofibular ligament
9. Peroneus brevis
10. Peroneus longus
11. Deltoid ligament (deep)
12. Tibialis posterior tendon
13. Flexor digitorum longus tendon
14. Interosseous ligament
15. Sustentaculum tali
16. Flexor hallucis longus tendon
17. Calcaneus
18. Abductor hallucis
19. Quadratus plantae
20. Flexor digitorum brevis
21. Plantar aponeurosis
22. Abductor digiti minimi



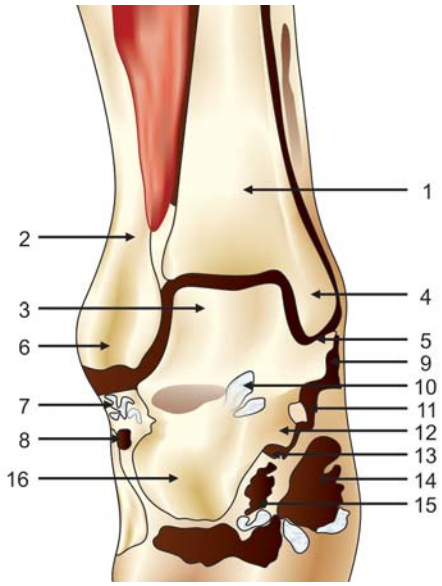

Figure 18.23

1. Tibia
2. Fibula
3. Talus, body
4. Medial malleolus
5. Deltoid ligament
6. Lateral malleolus
7. Peroneus brevis
8. Peroneus longus
9. Tibialis posterior
10. Tarsal sinus
11. Flexor digitorum longus
12. Sustentaculum tali
13. Flexor hallucis longus
14. Abductor hallucis
15. Quadratus plantae
16. Calcaneus



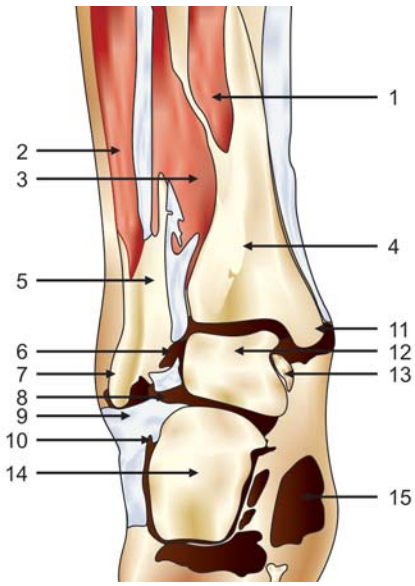

Figure 18.24

1. Tibialis posterior
2. Peroneus longus and brevis
3. Flexor hallucis longus
4. Tibia
5. Fibula
6. Posterior tibiofibular ligament
7. Lateral malleolus
8. Posterior talofibular ligament
9. Peroneus longus
10. Calcaneofibular ligament
11. Medial malleolus
12. Talus
13. Deltoid ligament
14. Calcaneus
15. Abductor hallucis

Sagittal Images

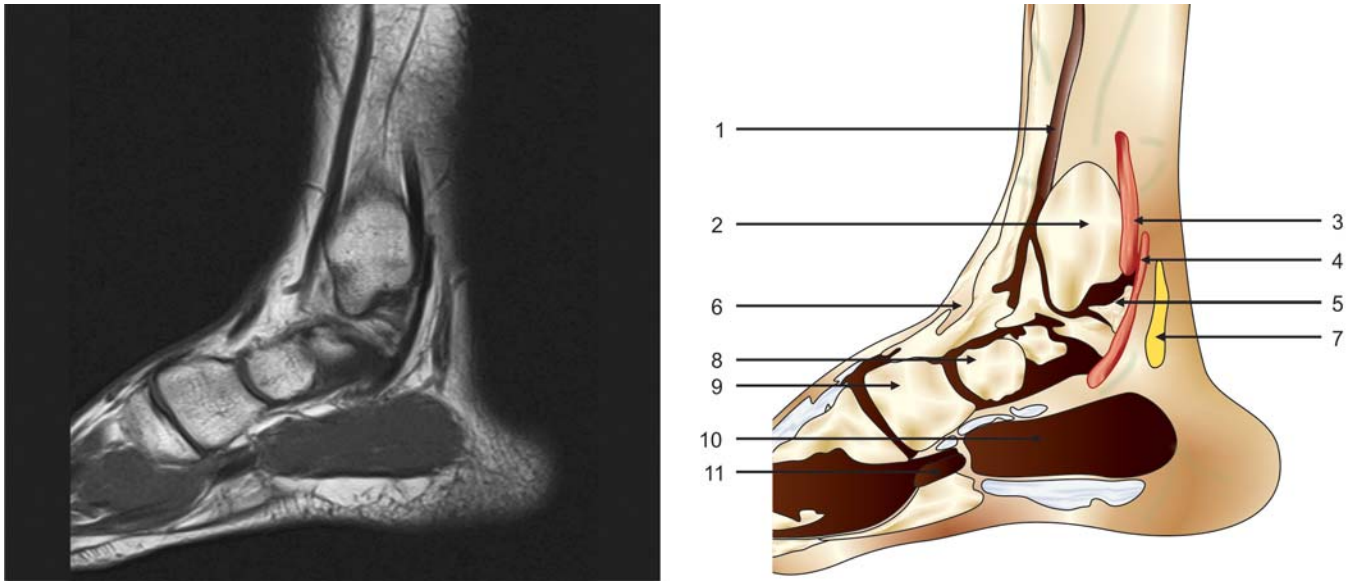

Figure 18.25

1. Great saphenous vein
2. Medial malleolus
3. Tibialis posterior tendon
4. Flexor digitorum longus
5. Deltoid ligament
6. Tibialis anterior tendon
7. Posterior tibial artery and nerve
8. Navicular bone
9. Medial cuneiform
10. Abductor hallucis
11. Flexor hallucis longus tendon

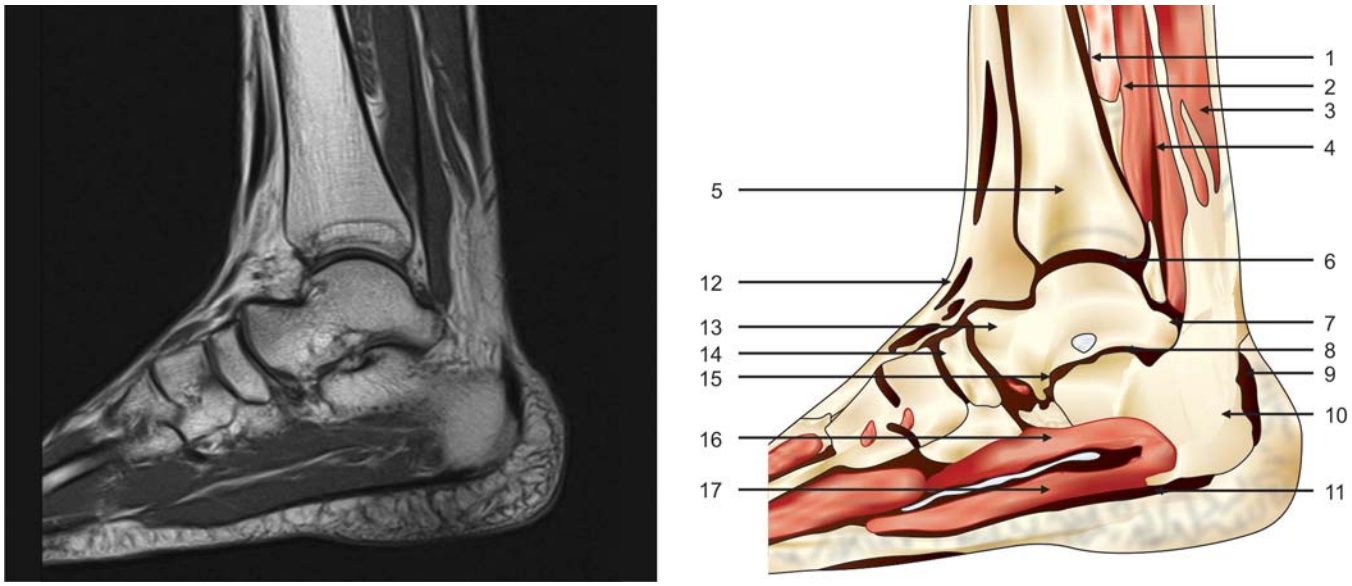

Figure 18.26

1. Tibialis posterior
2. Flexor digitorum longus
3. Soleus
4. Flexor hallucis longus
5. Tibia
6. Ankle joint
7. Lateral talar tubercle
8. Interosseous ligament
9. Achilles tendon
10. Calcaneum
11. Plantar aponeurosis
12. Tibialis anterior tendon
13. Head, talus
14. Navicular
15. Medial subtalar joint
16. Quadratus plantae
17. Flexor digitorum brevis



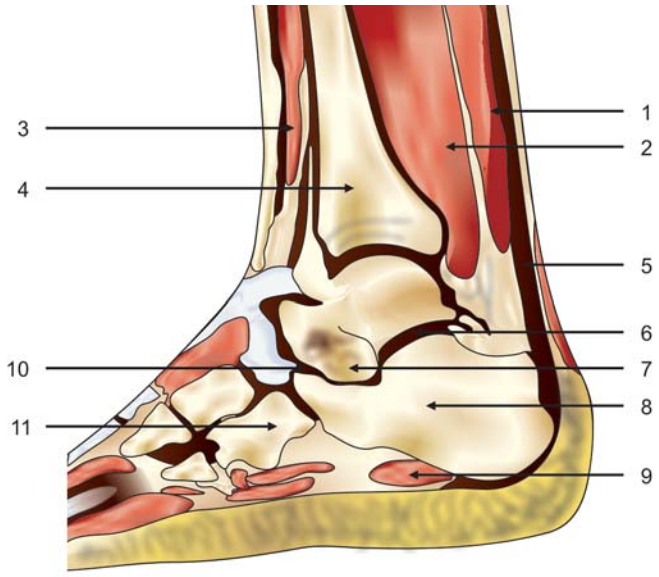

Figure 18.27

1. Soleus
2. Long flexor muscles
3. Tibialis anterior
4. Tibia
5. Achilles tendon
6. Posterior subtalar joint
7. Tarsal sinus
8. Calcaneum
9. Abductor digiti minimi
10. Anterior subtalar joint
11. Cuboid



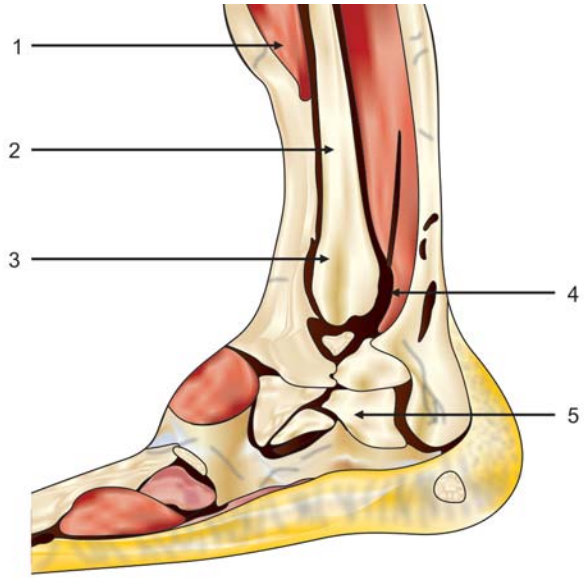

Figure 18.28

1. Extensor digitorum longus
2. Fibula
3. Lateral malleolus
4. Peroneus longus tendon
5. Calcaneum

FOOT

Axial Images



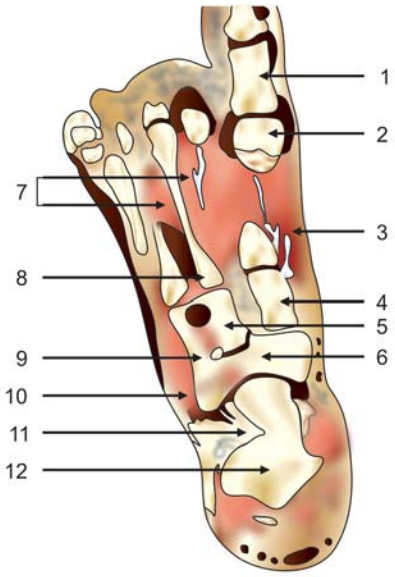

Figure 18.29

1. Proximal phalanx
2. First metatarsal
3. Abductor hallucis
4. Medial cuneiform
5. Lateral cuneiform
6. Navicular
7. Dorsal interosseous muscles
8. Third metatarsal
9. Cuboid
10. Extensor digitorum brevis
11. Tarsal sinus
12. Talus



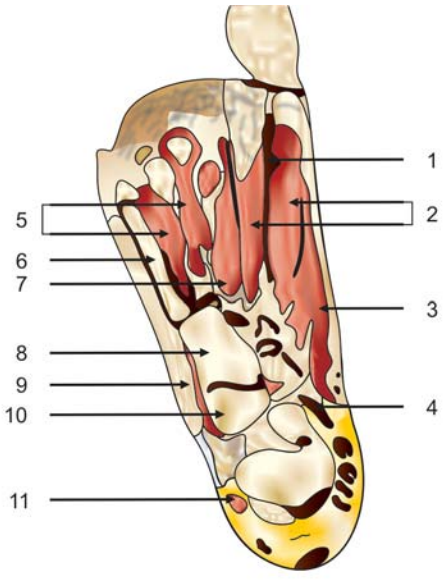

Figure 18.30

1. Flexor hallucis longus tendon
2. Flexor hallucis brevis (medial, lateral heads)
3. Abductor hallucis
4. Flexor digitorum longus tendon
5. Plantar interosseous muscles
6. Fifth metatarsal
7. Adductor hallucis
8. Cuboid
9. Extensor digitorum brevis
10. Calcaneus
11. Peroneal tendons

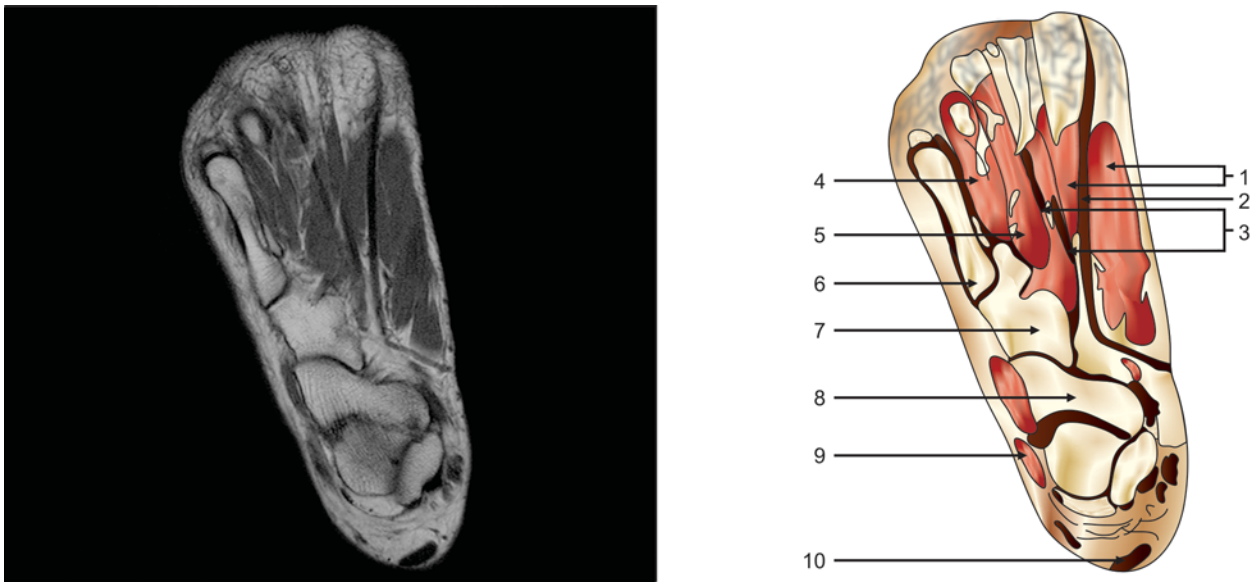

Figure 18.31

1. Flexor hallucis brevis (medial, lateral heads)
2. Flexor hallucis longus tendon
3. Flexor digitorum longus tendons
4. Plantar interosseous muscles
5. Adductor hallucis (oblique head)
6. Fifth metatarsal base
7. Cuboid
8. Calcaneus
9. Peroneal tendons
10. Achilles tendon

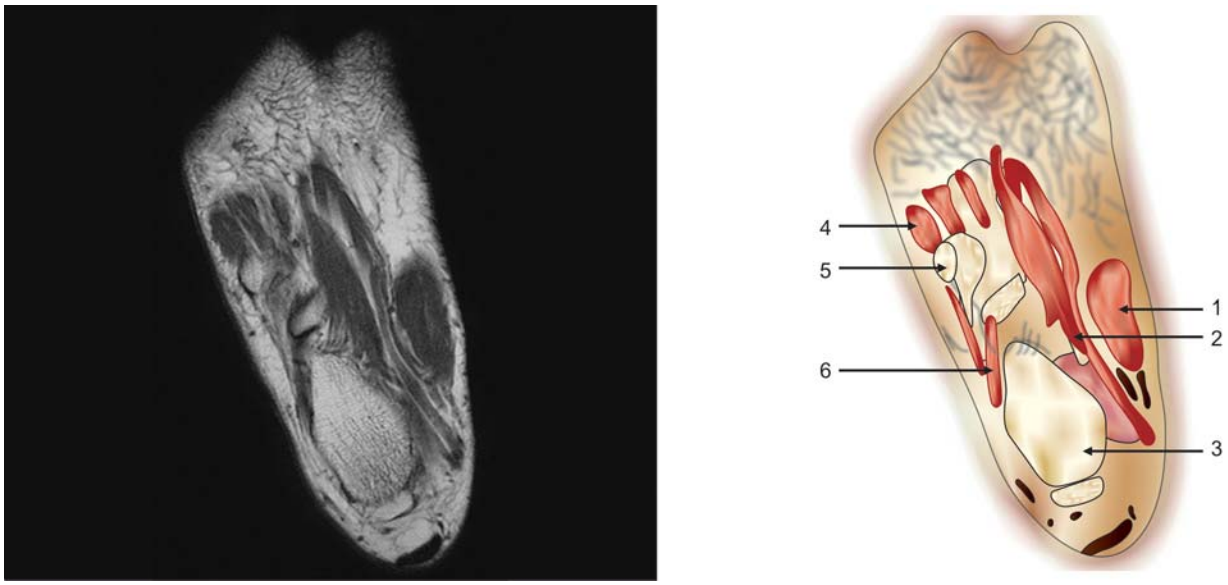

Figure 18.32

1. Quadratus plantae
2. Flexor digitorum brevis
3. Calcaneal tuberosity
4. Flexor digiti minimi
5. Fifth metatarsal tuberosity
6. Abductor digiti minimi

Coronal Images

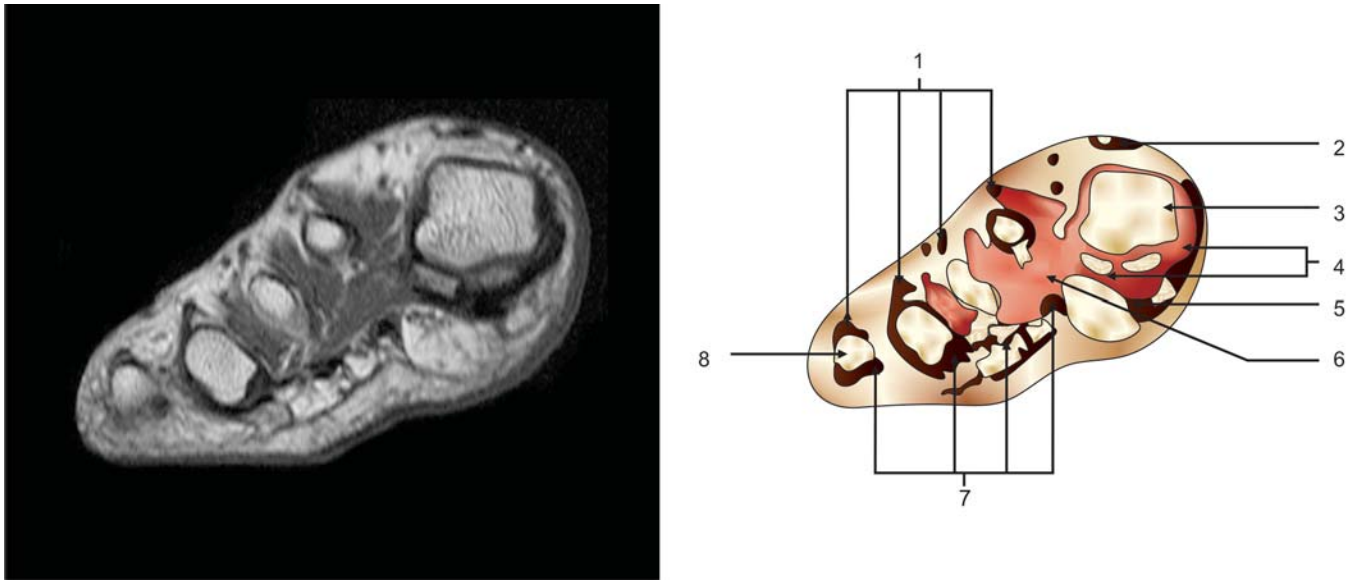

Figure 18.33

1. Short and long extensor tendons, digits
2. Extensor tendon, great toe
3. Great toe
4. Flexor hallucis brevis (medial, lateral heads)
5. Flexor hallucis longus tendon
6. Adductor hallucis (transverse head)
7. Short and long flexor tendons, digits
8. Fifth digit

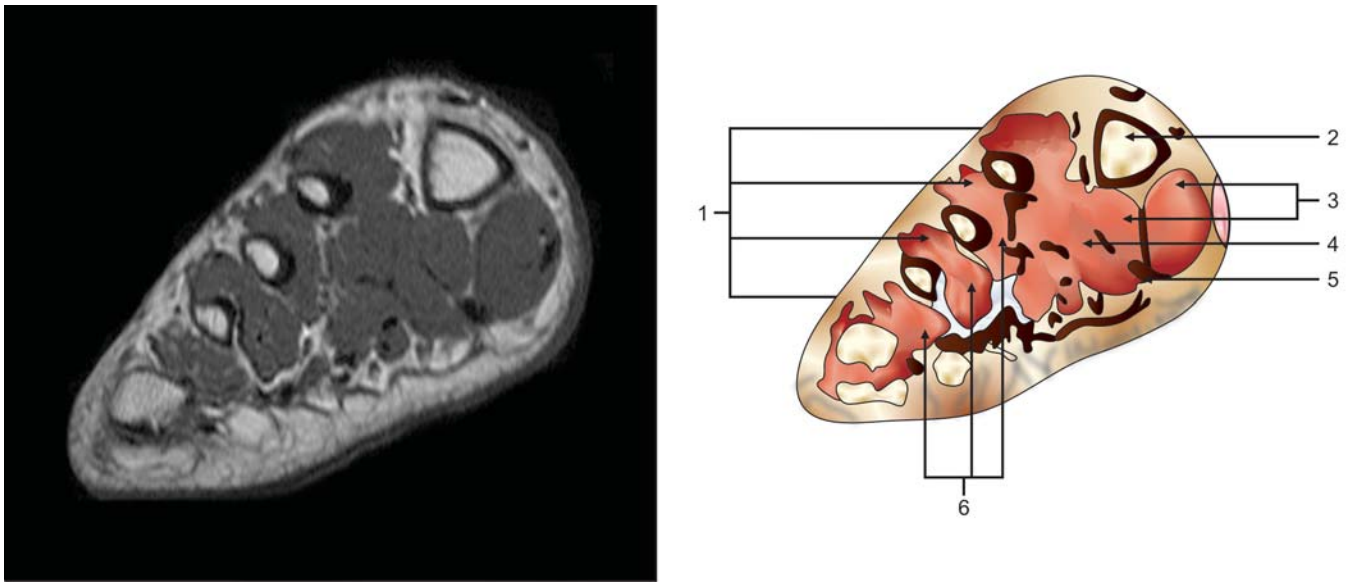

Figure 18.34

1. Dorsal interosseous muscles
2. First metatarsal
3. Flexor hallucis brevis (medial, lateral heads)
4. Adductor hallucis (oblique head)
5. Flexor hallucis longus tendon
6. Plantar interosseous muscles

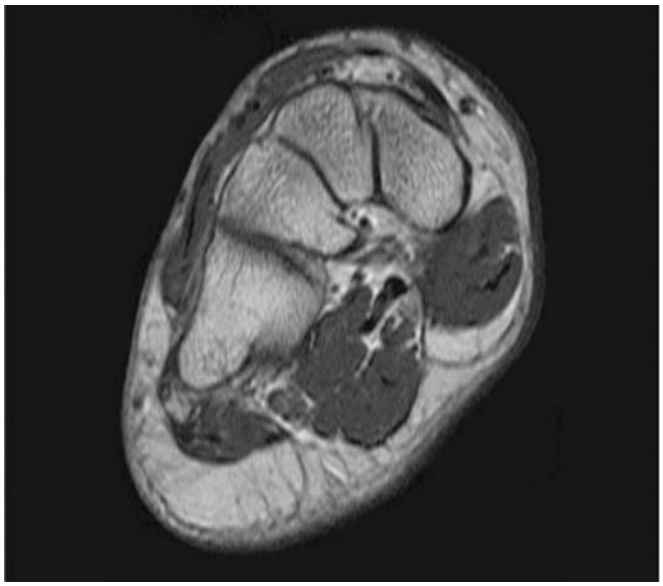

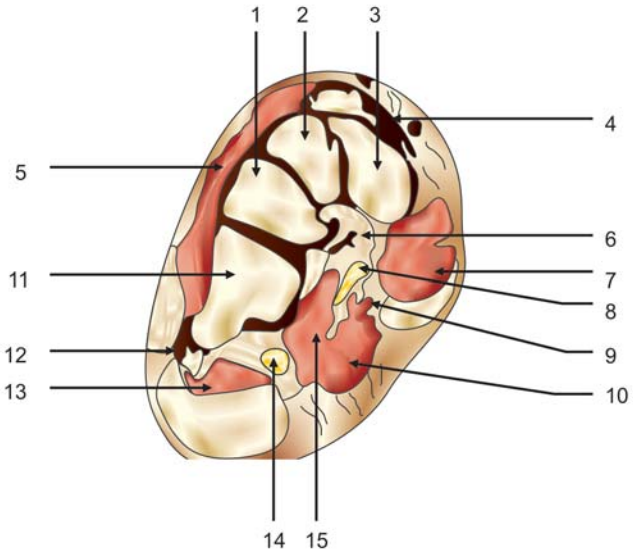

Figure 18.35

1. Lateral cuneiform
2. Intermediate cuneiform
3. Medial cuneiform
4. Extensor hallucis longus tendon
5. Short extensor tendons
6. Flexor hallucis brevis tendon
7. Abductor hallucis muscle
8. Flexor hallucis longus tendon
9. Medial plantar artery, nerve
10. Flexor digitorum brevis
11. Cuboid
12. Peroneus brevis tendon
13. Abductor digiti minimi
14. Lateral plantar artery, nerve
15. Quadratus plantae

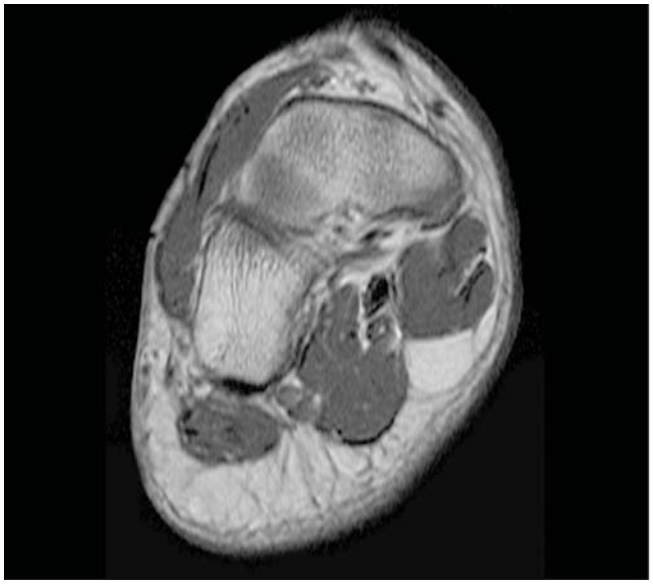

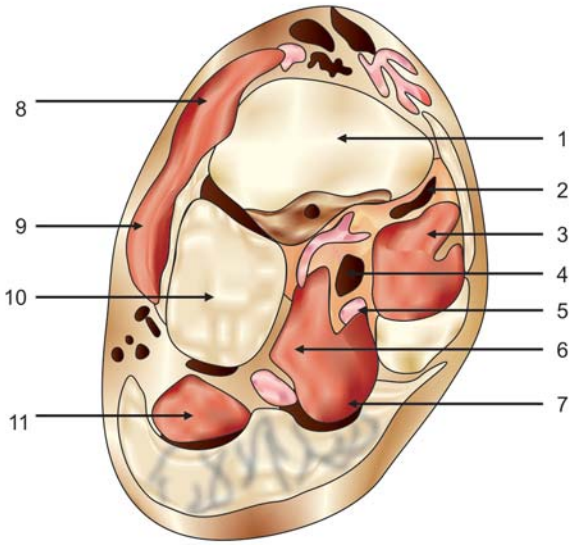

Figure 18.36

1. Navicular
2. Tibialis posterior tendon
3. Abductor hallucis
4. Flexor hallucis longus tendon
5. Medial plantar artery, nerve
6. Quadratus plantae
7. Flexor digitorum brevis
8. Extensor digitorum longus
9. Extensor digitorum brevis
10. Cuboid
11. Abductor digiti minimi

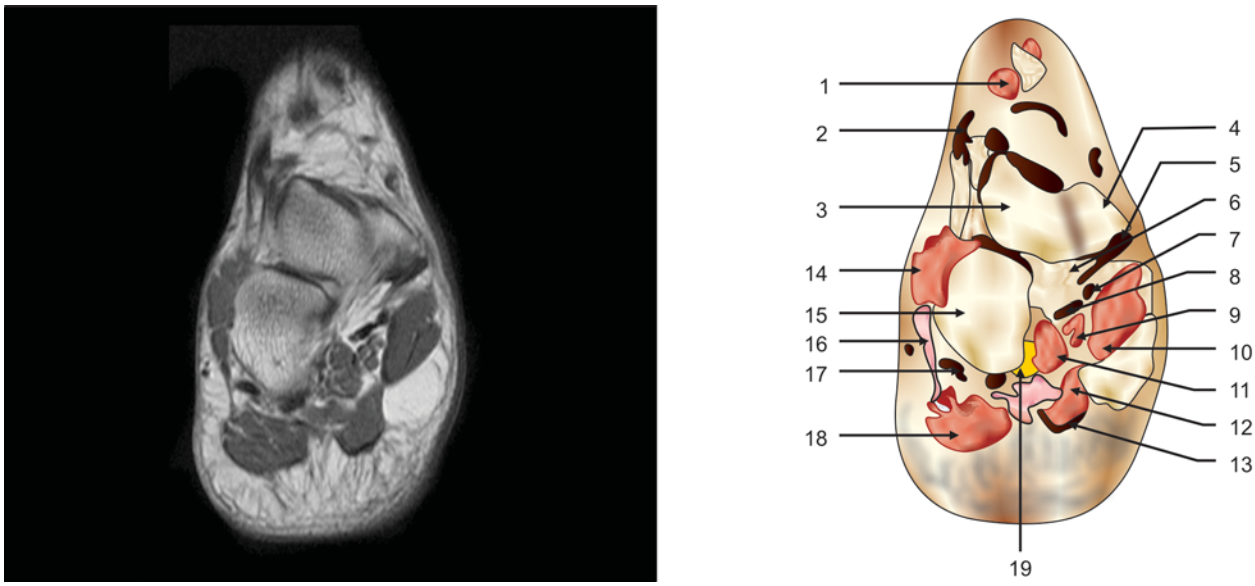

Figure 18.37

1. Extensor hallucis longus
2. Extensor digitorum longus
3. Talus
4. Navicular tuberosity
5. Tibialis posterior tendon
6. Plantar calcaneonavicular (spring) ligament
7. Flexor digitorum longus tendon
8. Flexor hallucis longus tendon
9. Medial plantar artery, nerve
10. Abductor hallucis
11. Quadratus plantae
12. Flexor digitorum brevis
13. Plantar aponeurosis
14. Extensor digitorum brevis
15. Calcaneus
16. Peroneus brevis
17. Peroneus longus
18. Abductor digiti minimi
19. Lateral plantar artery, nerve

Sagittal Images

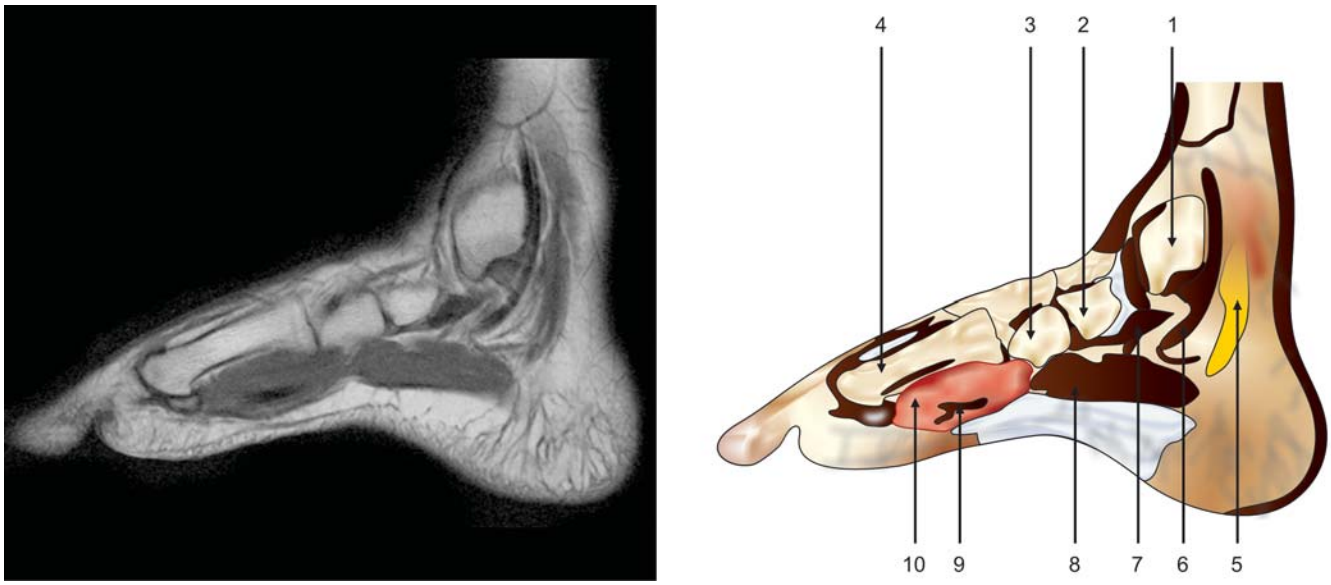

Figure 18.38

1. Medial malleolus
2. Navicular
3. Medial cuneiform
4. First metatarsal
5. Posterior tibial artery nerve
6. Flexor digitorum longus tendon
7. Tibialis posterior tendon
8. Flexor digitorum brevis
9. Flexor hallucis longus tendon
10. Flexor hallucis brevis

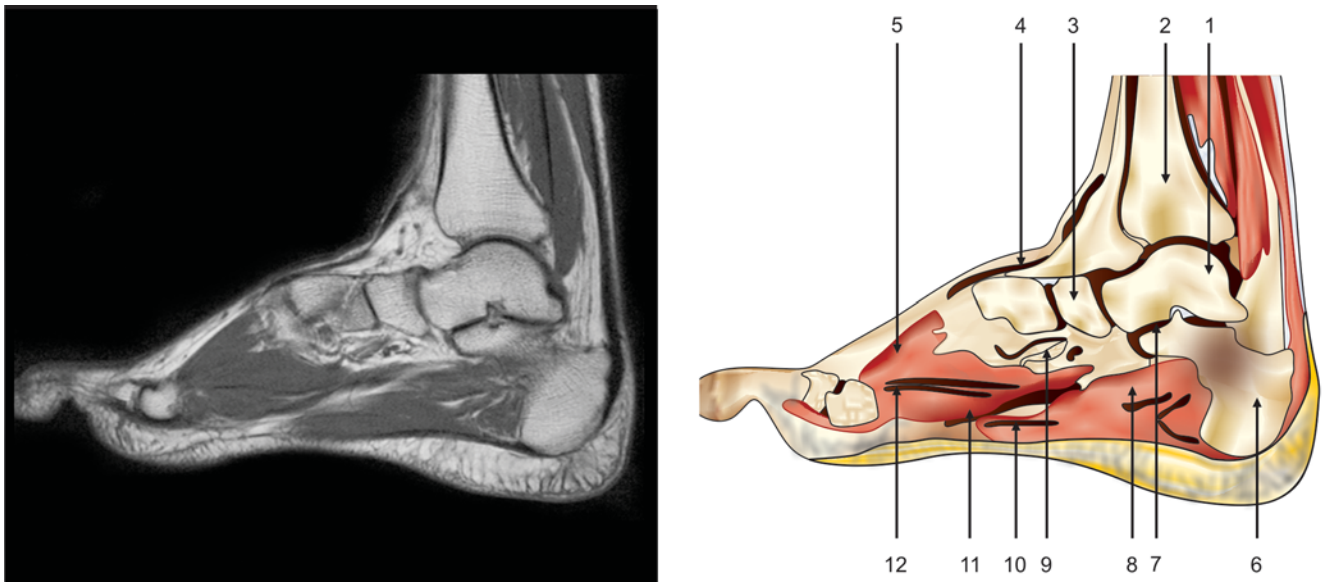

Figure 18.39

1. Talus
2. Tibia
3. Navicular
4. Tibialis anterior tendon
5. Dorsal interosseous muscle
6. Calcaneus
7. Medial subtalar joint
8. Quadratus plantae
9. Medial plantar artery
10. Flexor digitorum brevis
11. Flexor hallucis longus tendon
12. Adductor hallucis

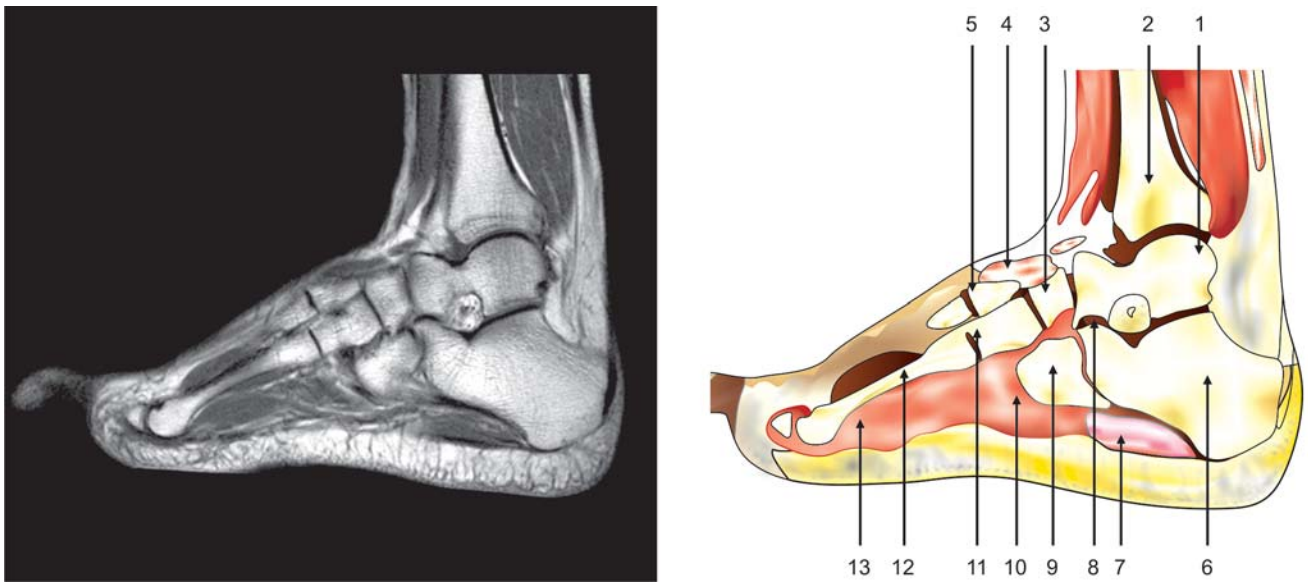

Figure 18.40

1. Talus
2. Tibia
3. Navicular
4. Extensor hallucis longus
5. Intermediate cuneiform
6. Calcaneus
7. Abductor digiti minimi
8. Anterior subtalar joint
9. Cuboid
10. Peroneus longus tendon
11. Lateral cuneiform
12. Third metatarsal
13. Interosseous muscle



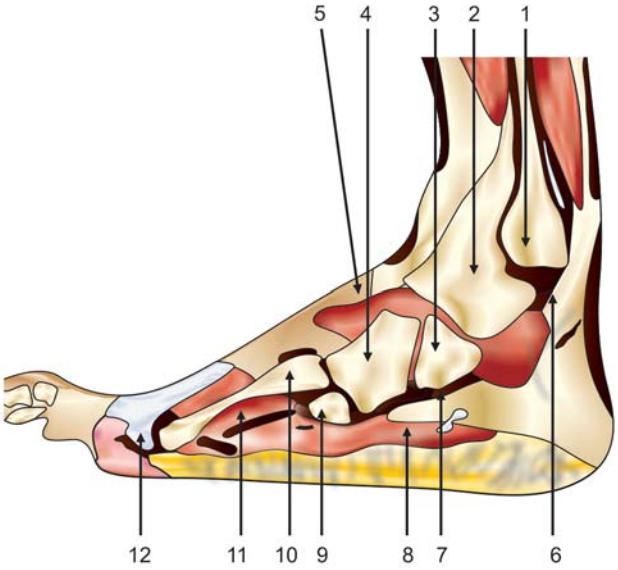

Figure 18.41

1. Lateral malleolus
2. Talus
3. Calcaneus
4. Cuboid
5. Extensor digitorum brevis
6. Peroneal tendon
7. Peroneus longus tendon
8. Abductor digiti minimi
9. Fifth metatarsal
10. Fourth metatarsal
11. Lumbrical and plantar interosseous
12. Proximal phalanx, fifth toe

CHAPTER 19

Lower Extremity Vessels

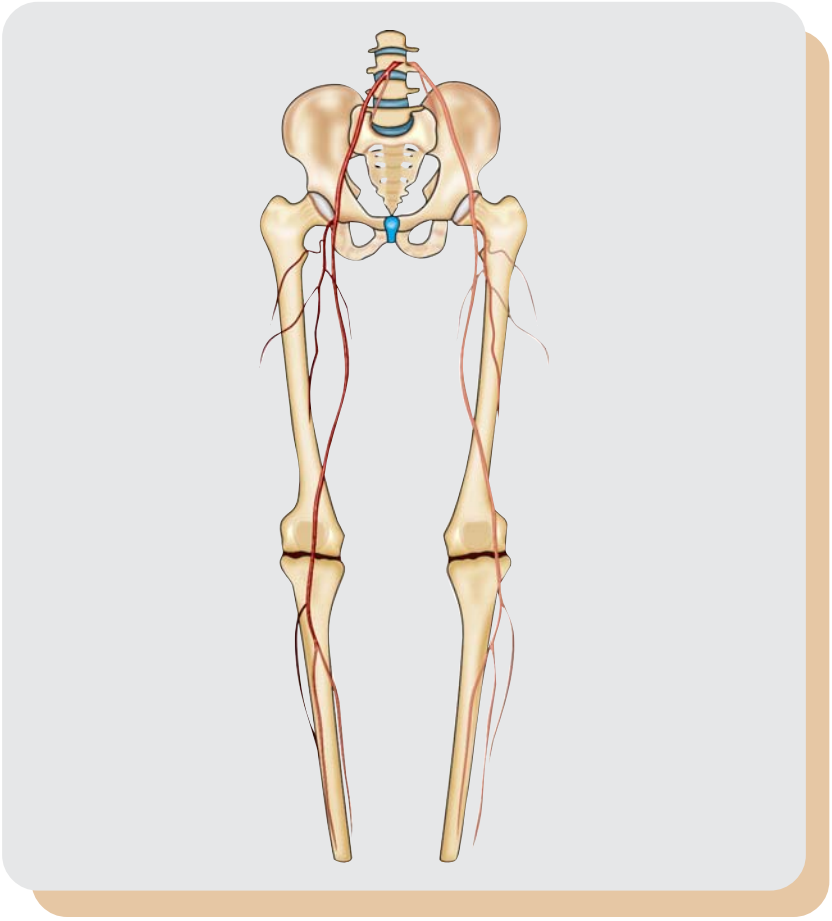

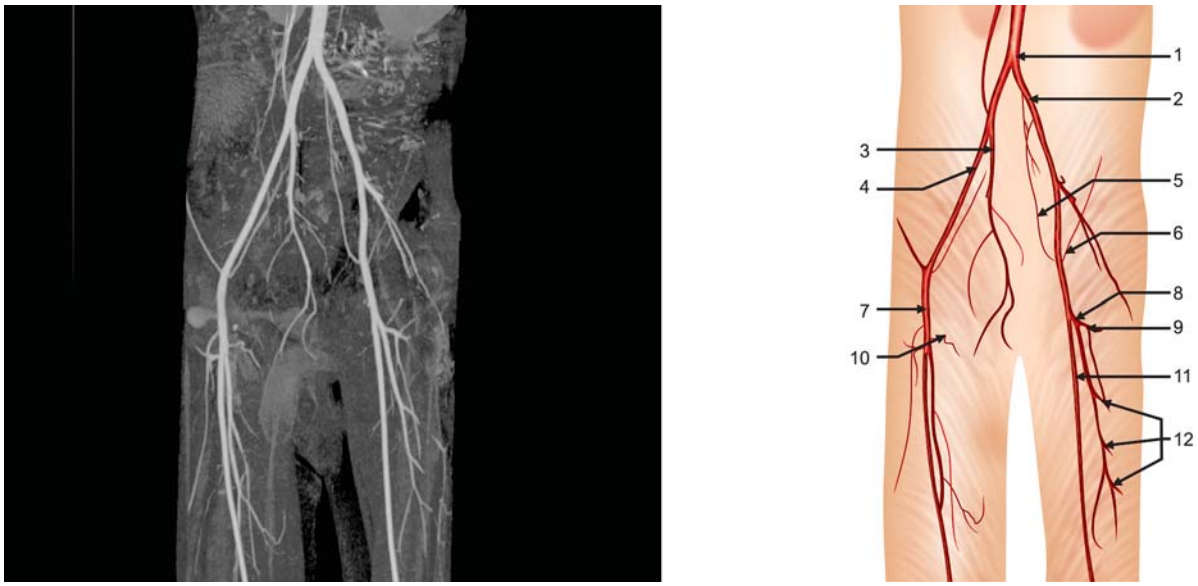

Figure 19.1

1. Aorta
2. Common iliac artery
3. Internal iliac artery
4. External iliac artery
5. Superficial inferior epigastric artery
6. Superficial circumflex epigastric artery
7. Common femoral artery
8. Profunda femoral artery
9. Lateral circumflex artery
10. Medial circumflex artery
11. Superficial femoral artery
12. Muscular branches

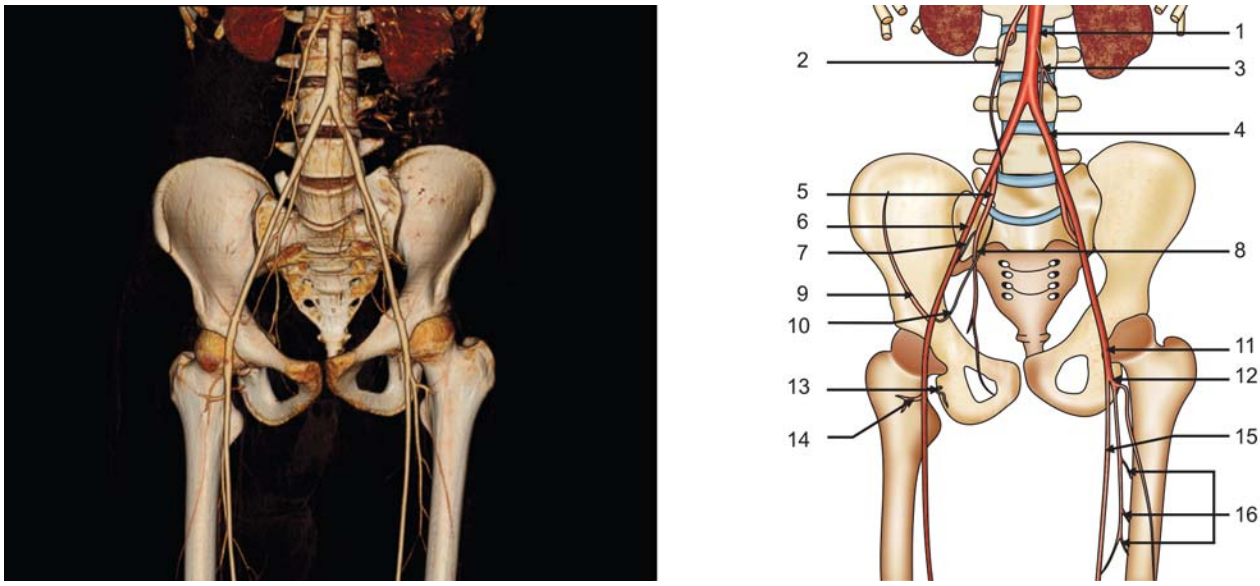

Figure 19.2

1. Aorta
2. Superior mesenteric artery
3. Inferior mesenteric artery
4. Common iliac artery
5. Internal iliac artery
6. External iliac artery
7. Interior iliac, anterior division
8. Posterior division
9. Superficial circumflex epigastric artery
10. Superficial inferior epigastric artery
11. Common femoral artery
12. Profunda femoral artery
13. Medial circumflex artery
14. Lateral circumflex artery
15. Superficial femoral artery
16. Muscular branches

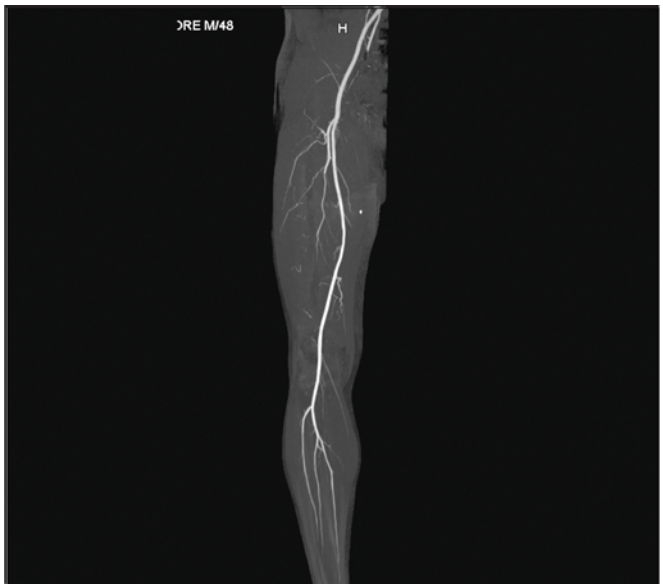

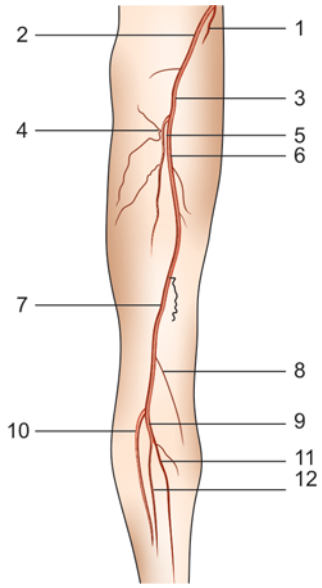

Figure 19.3

1. Internal iliac artery
2. External iliac artery
3. Common femoral artery
4. Lateral circumflex artery
5. Profunda femoral artery
6. Superficial femoral artery
7. Popliteal artery
8. Genicular branch
9. Tibioperoneal trunk
10. Anterior tibial artery
11. Posterior tibial artery
12. Peroneal artery



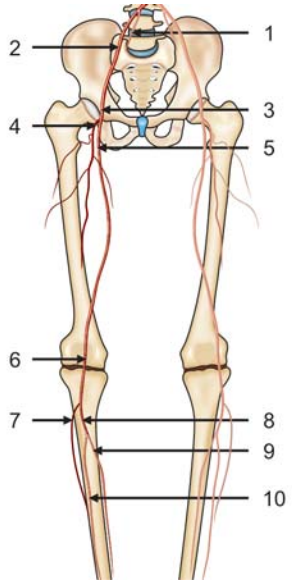

Figure 19.4

1. Internal iliac artery
2. External iliac artery
3. Common femoral artery
4. Profunda femoral artery
5. Superficial femoral artery
6. Popliteal artery
7. Anterior tibial artery
8. Tibioperoneal trunk
9. Posterior tibial artery
10. Peroneal artery

Index

A

Abdomen 117
Abdominal wall 128
Abducent nerve 7
Abductor
  digiti minimi 189-191, 248, 251, 253, 255-258
  hallucis 247-250, 252, 255, 256
    muscle 255
  pollicis 191
    brevis 189, 190
    longus 177, 189, 190
Accessory tubercle 89, 92, 93
Acetabular roof 211
Acetabulum 202, 203, 205, 206, 209, 211
Achilles tendon 221, 246, 247, 250, 251, 253
Acromio-clavicular joint 162
Adductor
  brevis 143, 149, 209, 214
  hallucis 252-254, 257
  longus 149, 209, 211, 214, 216, 218
  magnus 149, 208, 211, 214, 215, 217-219
Air in esophagus 111, 112
Alveolar margin 36, 60
  of maxilla 45
Ambient cistern 14
Anal canal 128, 142, 145-147, 149, 150, 152, 154, 156, 157, 207, 208
Ankle
  and foot 237
  joint 244, 250
Annular fibrosis 96
Anterior
  arch of atlas 45, 77, 80, 83
  cerebral artery 4, 5, 20
  chamber 28, 29
  circumflex humeral artery 196
  clinoid 45, 67, 69
  commissure 8, 9, 15, 22, 64
  communicating artery 4, 15
  cruciate ligament 230, 233, 235
  ethmoid cells 38, 44
  fat pad 185
  fornix 147, 150
  inferior iliac spine 206
  interhemispheric fissure 16
  jugular vein 64-66
  labrum 164, 167, 205
  lamina 8
  limb of internal capsule 16
  longitudinal ligament 84, 86, 95, 96
  median sulcus 7
  pillar acetabulum 202
  pituitary 9
  ramus-lateral sulcus 11
  rib 115
  segment 106
    bronchus 107, 110
  subtalar joint 251, 257
  talofibular ligament 246, 248
  tibial artery 220, 221, 246, 261
  tibiofibular ligament 246, 248
  tubercle 221
    C1 8, 77
    of atlas 74, 77, 80, 81, 83
    of transverse process 79
Antrum 121
Anus 143, 152, 153
Aorta 88, 94, 105, 112, 118-123, 131, 260
Aortic
  knuckle 115
  root 103, 104
Apical segment
  bronchus 111
  vessels 106
Apicoposterior
  bronchus 106
  segment bronchus 111, 112
Appendix 119, 120
Aqueduct of Sylvius 8, 9, 15, 24
Arch of aorta 102, 114, 197
Articular
  cartilage 229, 233-235
  disk 57
  pillar 80, 83-85
  tubercle 57
    of temporal bone 57
Aryepiglottic fold 63, 66
Arytenoid cartilage 64, 69
Ascending
  aorta 103
  colon 119, 120, 125, 130, 131, 136
  pharyngeal vessels 61
  ramus-lateral sulcus 11
Atlantoaxial joint 80, 81, 83
Atlanto-occipital joint 82, 83, 87
Atrium of lateral ventricle 10, 15, 16, 25
Axial compartment of hip joint 138
Axillary
  artery 196, 197
  nerve 170
  pouch 164
Azygoesophageal recess 107
Azygos vein 102, 105, 121

B

Basal
  lamina 45
  turn of cochlea 49
  vein of Rosenthal 5, 6
Base of fifth metatarsal 238
Basilar artery 4, 5, 7, 8, 12, 13, 22
Basivertebral vein 95
Biceps 229-231
  brachii 169, 174, 175, 181, 185
    tendon 182
  femoris 214, 215, 217, 219, 233, 234, 236
  labral complex 163, 165, 169
  tendon 163, 165-169, 183
Bicipital
  aponeurosis 182, 185
  groove 167, 168
Bladder 135, 148, 203, 208
  neck 139, 156
Body of
  caudate nucleus 17
  lateral ventricle 17
  pancreas 123
  pubis 204
  uterus 138, 147
Bowel loops 139, 140, 145, 147, 148
Bracheocephalic
  artery 68
  vein 68
Brachial
  artery 174, 181-185, 196, 197
  veins 174
Brachialis 175, 181-183, 185
  muscle 183, 185
    and tendon 182
Brachioradialis 176, 177, 181-183, 186
Brain 3
Bronchovascular structures 106
Bronchus 106
  intermedius 107, 111
Buccinator muscle 65, 70
Bulb of penis 156
Bulbospongiosus muscle 153
Bulbous urethra 139
Bulla ethmoidalis 45

C

C1 vertebra 84
C2
  body 74, 78, 79, 81, 83
  lamina 83
  spinous process 81, 83
  vertebra 74, 82, 84, 87

C3
lamina 81
vertebra 84
C4
body 83
lamina 83
spinous process 83
vertebra 84
C5 vertebra 81
C7 transverse process 74
Caecum 119, 126, 129, 130
Calcaneal tuberosity 247, 253
Calcaneocuboid joint 241, 245, 247
Calcaneofibular ligament 247-249
Calcaneonavicular ligament 247
Calcaneum 248, 250, 251
Calcarine
fissure 15
sulcus 8-10, 15, 26
Capitate 188-192, 194
Capitulum 180, 182-184, 186
Cardiac apex 105
Cardiophrenic angle 115
Carina 75, 111, 115
Carotid
artery 63, 67, 85
canal 48, 49, 52
Carpometacarpal joint 194
Cauda equina 96
Caudate nucleus 10, 16, 21, 23
body 10
head 17, 21
Celiac
artery 118, 119, 130
trunk 123
Central sulcus 11, 17-19
Centrum semiovale 18
Cephalic vein 174, 175, 181, 182, 185
Cerebellar
hemisphere 10, 11
tonsil 8
vermis 13
white matter 12, 13
Cerebellopontine cistern 13
Cerebellum 7, 8, 12, 14, 24, 87
Cerebral peduncle 10, 14, 23
Cervical
canal 141, 144, 147
vertebral body 85
Cervix 138, 140, 147, 149, 150
Chest 101
Ciliary body 29
Cingulate
gyrus 8, 9, 17, 18, 21, 23
sulcus 8-10, 17, 18, 25
Circumflex humeral arteries 197
Cisterna magna 9, 25
Claustrum 16, 21
Clitoris 143
Clivus 7-9, 45, 60, 68, 81, 86
Coccygeus 128
muscle 157
Coccyx 76, 128, 138, 141, 148, 202, 206
Cochlea 7, 22, 50-54
Cochlear aqueduct 49
Collateral sulcus 22
Collis muscle 60
Common
bile duct 135
carotid artery 63, 78, 82
extensor tendon 182-84, 186
femoral artery 260, 261
flexor tendon 182, 184, 185
hepatic duct 135
iliac
artery 118, 260
vessels 209
interosseous artery 196
peroneal nerve 214, 215, 220, 229, 233, 234, 236
Conus medullaris 96
Copper-T 138
Coracobrachialis 168, 174
Coracoid process 162, 164, 166, 169
Cornea 29
Cornu of uterus 138
Corona radiata 17
Coronoid process 60, 180-185
Corpora cavernosa 153-155
Corpus
callosum 8, 9, 23
body 8, 22
cavernosum 156
spongiosum 153-155
Cortical vein 6, 18
Costocervical trunk 196, 197
Costovertebral joint 90
Cribriform plate 45
Cricoid cartilage 64, 66, 68, 69
Crura of diaphragm 122
Crus
cerebri 15
of diaphragm 90
Cuneiform 241
Cuneus 10
Cyst in left ovary 144

D

Deep
brachial artery 175
femoral vessels 214
peroneal nerve 220
Deltoid
insertion 175
ligament 246, 248-250
tuberosity 174
Dens of axis 45
Descending
aorta 103-106, 110, 111, 115, 122, 136
colon 119, 123-126, 131, 132
Diaphragm 122, 123, 128, 129
Digastric muscle 62, 63, 65, 67, 70
Diploic space 18
Disk space 74, 75, 121
Distal
phalanx 188, 239
radioulnar joint 191, 192
Dorsal
interosseous muscles 252, 254, 257
nerve root 87
root ganglion 84, 86, 87, 95
Dorsum sella 45
Duodenal cap 121
Duodenojejunal
flexure 124, 130
junction 121
Duodenum 121, 123-125, 129, 130, 135
Dural sac 95

E

Elbow 179
Endometrial cavity 145, 150
Endometrium 147
Epiglottis 62, 63, 66, 68, 69, 81
Epitympanum 51, 53
Erector spinae 88, 89, 94
Esophagus 65, 102, 103, 105, 106, 110, 121, 131
Ethmoid
air cells 28, 29
sinuses 66, 68
Eustachian tube 45, 49, 52
Extensor carpi
longus 176
radialis
brevis 176, 177, 184
longus 177, 181-184, 186, 189, 190
ulnaris 176, 177, 189, 190, 193
tendon 189-192
Extensor digitorum 176, 177, 182, 186, 222
brevis 247, 252, 255, 256, 258
longus 220, 232, 233, 246, 251, 255, 256
tendon 221
tendon 189, 194
Extensor hallucis
and digitorum longus 220, 221, 225, 248
longus 222, 246, 256, 257
tendon 221, 255
Extensor
muscles 184
pollicis
brevis 191, 192
longus 189, 192
retinaculum 189, 190
tendons 190, 192, 254
External
auditory
canal 48, 52, 57, 67
meatus 45
capsule 16, 21
iliac
artery 118, 126, 260, 261
vein 126
vessels 131, 139-141, 150, 206, 209
jugular vein 63, 64, 67
obturator muscle 149

Extraconal fat 28, 29
Extreme capsule 16
Eyeball 28

F

Facet joint 74-76, 78, 80, 82-84, 86-88, 91-96, 98
Facial
  colliculus 8
  nerve 7, 49-51, 53-56
    canal 48
  recess 49
  vein 60, 61, 66
Fallopian tube 145, 148
False vocal cord 66, 69
Fat stripe 136
Femoral
  artery 127, 130, 151, 152
  condyle 228, 233, 236
  head 202, 203, 205-208
  neck 202
  vein 127, 130, 151, 152
  vessels 129, 203, 206, 207, 211, 214-218
Femur 138, 152, 154, 204, 207, 214-216, 219, 228, 229, 232, 235
Femur head 139
Fibula 220-223, 225, 231, 233, 236, 238, 249, 251
Fibular head 229
Fissure for ligamentum venosum 123
Flexor
  carpi
    radialis 176, 177, 183, 189
    ulnaris 176, 177, 182-185, 189-191, 193
  digiti minimi 253
  digitorum
    brevis 248, 250, 253, 255-257
    longus 220, 221, 246, 249, 250
  digitorum
    longus tendon 221, 246, 248, 252, 253, 256
    profundus 176, 177, 184, 185, 189, 191
    superficialis 176, 177, 182, 183, 189
    tendons 189, 190
  hallucis
    brevis 252-256
    longus 220, 221, 223, 225, 246, 249, 250
    longus tendon 246-248, 250, 252-257
  retinaculum 189, 190, 194
  tendons 190, 193, 194
Foramen
  of Magendie 9
  of Monro 22
  ovale 67
  rotundum 45
  transversarium 79, 84
Fossa of Rosenmuller 45
Fovea
  capitis 202
  ethmoidalis 45
Free spill of contrast in pelvis 138
Frontal
  horn of lateral ventricle 16, 20
  operculum 20
  recess 45
  sinus 39, 40, 41, 44, 68
Fundic
  bubble 120, 136
  gas bubble 115
Fundus 121
  of uterus 138, 147, 150
Fusiform gyrus 25

G

Gallbladder 124, 128-130, 135
  neck 123
Gastric rugae 121
Gastrocnemius 220, 223-225, 229-231, 233-236
  tendon 221
Gastroduodenal artery 118, 119, 123, 124
Gastroesophageal junction 130
Gemelli 208, 210, 211
Genioglossus muscle 62, 65
Geniohyoid muscle 65
Genu 9, 10
  of corpus callosum 16, 17, 20
Glenoid 169
  fassa 162
Globus pallidus 16, 22
Glottis 81
Gluteus
  maximus 126, 127, 141, 146, 147, 204, 206-208, 210, 211, 214, 217-219
  medius 126, 146, 205, 206, 208-210
    fat plane 138
    minimus 207
  minimus 205, 206, 208, 210, 211
Gracilis 145, 209, 214, 215, 217, 218, 229-231
  muscle 143
  tendon 233, 234
Great
  saphenous vein 214, 215, 221, 229-231, 233, 234, 246, 248, 250
  toe 254
Greater
  curvature 121
  saphenous vein 221
  trochanter 138, 202, 203, 205-207, 208, 210
  tuberosity 162, 167, 170
  wing of sphenoid 29
Gyrus rectus 15, 19, 20, 30, 31

H

Habenular commissure 9
Hamate 188-193
Hard palate 45, 60, 68, 69
Haustra 119
Head of
  caudate nucleus 16
  femur 203
  mandible 57
  pancreas 124
  talus 238, 240
Heart 121, 129
Hepatic
  artery 118, 123, 129, 130
  flexure 119, 124, 129, 130, 136
Hiatus semilunaris 45
Hip
  bone 139
  joint 76
Hippocampus 11, 22, 23
Hippocampus body 24
Hoffa's fat pad 235, 236
Hook of Hamate 190, 191, 193
Humerus 62, 169-171, 174, 180, 181, 184, 185
Hyoglossus muscle 62
Hyoid 69, 74, 81, 82
  bone 63, 66-69
Hypoglossal canal 55, 56
Hypopharynx 68
Hypotympanum 48, 54

I

Ileal loops 120, 126, 128-131
Ileocecal
  junction 120
  valve 130
Ileocolic
  artery 118, 119
  veins 132
Ileum 76
Iliac
  bone 138, 150, 209
  branches 119
  crest 76, 136, 138
  loops 126, 127
Iliacus 126, 154, 155, 209
Iliocolic artery 130
Iliofemoral
  ligament 205-210
  tract 208
Iliopsoas 126, 127, 130, 140-142, 205-207, 209-211
  muscle 139, 150-152
Ilio-tibial tract 205, 206, 207, 214, 215, 229-233
Ilium 154, 202, 205, 209-211
Incisive canal 36, 45
Incisura angularis 121
Incus 49, 50, 52, 53
Inferior
  cerebellar peduncle 12, 23
  colliculus 14
  facet 74-76, 78, 82, 84, 88, 92-94, 97
  frontal gyrus 19, 21

gemellus 207
glenohumeral ligament 163-166
gluteal artery 127
horn of thyroid cartilage 64
labrum 164, 168, 169
margin of vertebra 93
mesenteric
artery 118, 260
vein 131, 133
parietal lobule 17
pubic ramus 202, 207
pulmonary
artery 112, 113
vein 112, 113
radioulnar joint 188
rectus 28, 31-33
temporal gyrus 11, 22
thyroid artery 196, 197
turbinate 36, 42, 45, 60, 65
Infraorbital foramen 45
Infrapatellar
fat 230, 232
Hoffa's fat pad 231
Infraspinatus 167, 168, 170, 171, 174
Infratemporal fossa 45
Infundibulum 45, 112-114, 138
of right ventricle 104
Inguinal ligament 129
Innominate substance 22
Insertion of inferior oblique 28
Insula 15, 21, 23
Insular cortex 16
Intercondylar
fossa 229
notch 230
shelf 235
Interhemispheric fissure 17-19, 25
Intermediate cuneiform 239, 240, 242, 244, 247, 255, 257
Intermuscular septum 32
Internal
auditory canal 7, 13, 50, 51, 54, 55
capsule 10, 21-23
carotid artery 4, 5, 29, 45, 60
cerebral vein 5, 6, 9, 16, 24
iliac
artery 118, 132, 260, 261
branches 126, 139
vessels 149, 150
jugular vein 5, 6, 63-67, 70, 78
mammary artery 196
os of cervix 147
Interosseous
artery 197
ligament 248, 250
membrane 177, 221, 229
muscle 192, 193, 257
Interpeduncular
cistern 22
fossa 14
Interspinous ligament 94, 95
Intertrochanteric line 138, 202
Intertubercular sulcus 162
Interventricular septum 104, 105
Intervertebral
disk 78, 84, 86-88, 90-92, 96, 97
foramen 75, 76, 83, 86-90, 92, 95, 97, 98
Intraconal fat 29
Intraparietal sulcus 17, 18
Intravenous urogram 135
Ischial
spine 138, 202, 206
tuberosity 138, 152, 154, 202, 207
Ischioanal fossa 142, 143, 145, 146, 148, 203, 207
Ischiocavernosus muscle 153
Ischiofemoral ligament 206, 207
Ischiopubic ramus 144
Ischiorectal fossa 128, 152-154, 156, 206
Ischium 141, 142, 156, 158, 203-205, 207, 208, 211
Isthmus of fallopian tube 138
IVC opening into RA 105

J

Jejunal
branches 118, 119
of SMA 118
loops 120, 124, 129-131
vein 132
Jejunum 121
Joint space 203, 205, 229
Jugular
foramen 7
fossa 48, 54, 56, 60
Junctional zone 140, 145, 150

K

Knee 227

L

L1 body 92
L2 body 76
L5 transverse process 138
Labium majora 143, 145
Labrum 163, 170, 207
Lacrimal gland 30, 32, 33
Lamina 78, 79, 84, 89, 91-97
papyracea 45
terminalis 9
Large intestine 119
Laryngeal ventricle 66, 69
Larynx 68
Lateral
basal 109
circumflex artery 260, 261
collateral ligament 230, 231, 233
cuneiform 238-242, 245, 247, 252, 255, 257
epicondyle 180, 182-184, 186
femoral
condyle 228-230, 233, 234
epicondyle 229
geniculate body 23
malleolus 238, 240, 241, 243, 246, 248, 249, 251, 258
mass of atlas 74, 80, 82, 83, 87
meniscus 231, 232, 233, 236
patellar
facet 228
retinaculum 229-232
plantar artery 255, 256
pterygoid
muscle 57, 60, 66, 67, 70
plate 45, 61, 66
rectus 28-32
semicircular canal 7, 50, 54-56
sulcus 11
supracondylar ridge 181
talar tubercle 245, 250
thoracic artery 196, 197
tibial condyle 229, 233
tubercle of talus 238
ventricle 10, 17, 23
Latissimus dorsi 169
Left
adrenal gland 123, 131, 132
atrial
appendage 103, 104
border 114
atrium 104, 113, 114
brachiocephalic vein 102
carotid artery 102, 196, 197
common iliac artery 118, 131
coronary artery 103
crus of diaphragm 90
diaphragm 75
dome of diaphragm 115
external iliac artery 126
gastric artery 130
hepatic
artery 118, 119
duct 135
lobe 122
vein 122
inferior pulmonary
artery 103, 104, 114
vein 104, 114
internal iliac artery 119, 126
kidney 90, 123, 124, 132, 135, 136
lobe of liver 122
main
bronchus 103, 114
pulmonary artery 113, 114
mainstem bronchus 106, 107, 111
ovarian cyst with fluid level 140
ovary 139, 144, 145
portal vein 122, 132
psoas muscle 136
pulmonary artery 103, 112, 114, 115
renal
artery 118, 123, 131
vein 123, 131
sacroiliac joint 136
subclavian artery 102, 196, 197
superior pulmonary vein 103, 110, 114
ventricle 104, 105, 112, 115
vertebral artery 7, 197

Lens 28, 29
Lesser
curvature 121
saphenous vein 220, 221, 223, 246, 247
trochanter 138, 202, 204, 210
tuberosity 162, 167, 169
Levator
ani 142, 157, 207, 208
muscle 128, 141, 142, 144, 146, 148, 152-156, 158
palpebrae
muscles 33
superioris muscle 32
scapulae 63, 64, 67, 70
Ligamentum
flavum 85-89, 91, 92, 94-97
nuchae 86
teres 206
Limbus 48
Linea
alba 125, 139, 150, 206
semilunaris 125, 139, 150
Lingual septum 62, 65
Lingular
gyrus 25
lobe bronchus 107, 108
Liver 110, 120-122, 124, 128, 129, 131, 132, 136
Long
flexor muscles 251
posterior ciliary artery 31
Longus
capitis 60, 67
Collis muscle 62
Lower
extremity 199
vessels 259
eyelid 28
lobe
bronchus 108
segment bronchus 111, 112
Lumbosacral plexus 156
Lumbrical and plantar interosseous 258
Lunate 188, 190-192, 194

M

Main pulmonary artery 103, 112, 113
Major
calyx 134, 135
fissure 106-108, 110-112
Malleus 49, 50, 52, 53
Mammillary
body 8, 9, 15, 22
process 89
Mammillothalamic tract 15
Mandible 45, 60, 61, 66, 70, 74
Massa intermedia 8, 9
Masseter muscle 60, 62, 66
Mastoid sinus 45, 48, 49, 56, 60, 67
Maxillary
antrum 60, 65, 66
sinus 28, 40-42
Meckel's cave 8, 21
Medial
basal 109
circumflex artery 260
collateral ligament 230-233
compartment of hip joint 138
cuneiform 239-242, 244, 247, 250, 252, 255, 256
epicondyle 180, 182, 184, 185
femoral
condyle 228-230, 233, 234
epicondyle 229
geniculate body 23
intercondylar eminence 235
intermuscular septum 185
longitudinal fasciculus 13, 14
malleolus 238, 243, 244, 246, 248-250, 256
meniscus 231, 233
anterior horn 232, 234
patellar
facet 228
retinaculum 229-232
plantar artery, nerve 255-257
pterygoid
muscle 60-62, 66, 70
plate 45
rectus 28, 29, 31-33
subtalar joint 244, 250, 257
supracondylar ridge 181
tibial condyle 229, 233, 234
tubercle of talus 238
Median
glossoepiglottic fold 63, 66
nerve 176, 177, 182, 189, 190
sulcus of medulla 12
Medulla 12, 23
oblongata 8, 9
Medullary pyramid 134
Membranous urethra 139
Metacarpophalangeal joint 188
Midbrain 9
Middle
cerebellar peduncle 8, 10, 13, 23
cerebral artery 4, 5, 15
ear 49, 53
ethmoid cells 39
facet
of talus 248
subtalar joint 243
frontal gyrus 17, 19, 21
glenohumeral ligament 164, 165
hepatic vein 122
lobe bronchus 108, 110
meatus 41, 45
phalanx 188
of second toe 239
scalene muscle 64, 65
subtalar joint 248
temporal gyrus 11, 22
turbinate 37, 45
Minor calyx 134, 135
Muscle 180
Muscular branches 260
Mylohyoid muscle 63, 65, 68, 69
Myometrium 147

N

Nasal
bone 38, 45
septum 28, 33, 36, 37, 45, 60
Nasolacrimal duct 28, 45
Nasopharynx 45, 66, 68, 81
Navicular
bone 250
tuberosity 256
Neck 59, 203
of mandible 57
Nerve roots 87, 90, 94-97
Neurovascular bundle 168, 169, 174, 175, 181
Nodule of cerebellum 24
Nucleus pulposis 86, 96

O

Oblique
abdominal muscles 150
muscles 125, 139
Obturator
externus 142-145, 152, 154, 155, 204, 205, 207-209, 211
foramen 138, 202
internus 127, 128, 140-142, 144, 145, 153, 155, 157, 158, 204-206, 208, 210
fat plane 138
muscle 149, 151, 152, 156
tendon 205
Occipital
bone 86, 87
condyle 53, 77, 82, 87
horn 15, 25
lobe 14, 17
pole 14
Occipitotemporal
gyrus 11, 22
sulcus 22
Oculomotor nerve 22
Olecranon
fossa 180, 181, 183-185
process 180-182, 184, 185
Olfactory sulcus 19
Ophthalmic artery 31
Optic
canal 29, 45
chiasm 8, 9, 21
disk 30
nerve 14, 19, 20, 29-32, 66
radiation 15, 16, 25
tract 10, 15, 21, 22
Orbit 27, 45
Orbital
apex 45
gyri 19
Oropharynx 62, 68
Outer myometrium 150
Oval window 50, 54

P

Palmar
aponeurosis 190, 194
radiocarpal ligament 194
Palmaris longus 177, 182
tendon 189
Pancreas 130, 131
Pancreatic duct 135
Papilla 134, 135
Paracentral lobule 19
Paracolic gutter 131
Parahippocampal gyrus 10, 11, 23
Parametrium 140
Parapharyngeal space 61, 67
Paraspinal muscles 61, 64
Parieto-occipital sulcus 8-10, 16-18
Parotid gland 61, 62, 67
Pars
interarticularis 76, 91, 92, 97
opercularis 11
orbitalis 11
triangularis 11
Part of uterus 145
Patella 228, 229, 235, 236
Patellar ligament 230, 231, 235, 236
Patellofemoral joint 228
Pectineus 143, 204, 207, 209, 211
muscle 128, 142, 149, 152
Pectoral muscles 102
Pectoralis
major 168, 174
minor 168, 174
Pedicle 75, 76, 78-80, 82, 85, 87, 88, 90, 92, 93, 95, 97, 98
Pelvis 134, 135, 137
Pelviureteric junction 135
Penile urethra 139
Penis 156
Pericallosal
artery 21
sulcus 8, 9
Peripheral zone 154
Peroneal
artery 261
tendons 252, 253, 258
Peroneus
brevis 221-223, 246-249, 256
tendon 255
longus 220-223, 246-249, 256
tendon 221, 251, 257, 258
tertius 221, 246
Perpendicular plate of ethmoid 45
Pes anserinus 232
Petro-occipital fissure 48, 53
Petrous
apex 51
bone 52
Pharynx 67, 79
Pineal gland 9
Piriformis 139, 140, 146, 147, 206, 210
muscle 126, 149, 156
Pisiform 188, 189, 191, 193
Pisohamate ligament 191
Pituitary
fossa 45
gland 8, 21, 68
stalk 8, 9, 14
Plantar
aponeurosis 248, 250, 256
calcaneonavicular ligament 256
interosseous muscles 252-254
Plantaris 230, 231
Platysma 66
muscle 66
Pons 7, 9, 13, 14, 22, 23
Popliteal
artery 229-231, 233, 234, 236, 261
vein 229-231, 233, 236
vessels 215
Popliteus 220, 231, 233, 235, 236
muscle 224
tendon 230, 231, 233
Portal
confluence 132, 133
vein 129, 130, 132, 133
Porus acusticus 54
Post
central gyrus 17-19
circumflex humeral artery 196
fat pad 181
tibiofibular ligament 246
Postcentral sulcus 19
Posterior
arch of atlas 74, 77, 83, 84
cerebellar artery 14
cerebral artery 4, 5
circumflex artery 170
commissure 9, 15
communicating artery 4, 5
costophrenic recess 114
cruciate ligament 230, 231, 233, 235
fat pad 185
fornix, vagina 144-146, 150
joint capsule 231, 236
labrum 164, 167, 205, 206
longitudinal ligament 86, 95
margin of foramen magnum 81
pillar acetabulum 202
pituitary 9
rib 115
root 84-86
scalene muscle 65
segment bronchus 106, 111, 112
semicircular canal 7, 49-51, 56
subtalar joint 245, 251
talofibular ligament 246, 249
tibial artery 220, 221, 223, 246, 250, 261
nerve 256
tibiofibular ligament 249
tubercle 8, 77
of atlas 74, 81, 83
of transverse process 79
Postolivary sulcus 7
Precentral gyrus 17, 18
Pre-epiglottic space 63, 68
Primary ostium of maxillary antrum 45
Profunda
brachii
artery 196
vessels 170
femoral artery 260, 261
Pronator
quadratus 189, 191, 192, 194
teres 182, 183
Prostate 132, 155, 156, 207, 208
central zone 152, 153
gland 128, 155
peripheral zone 152, 153
Prostatic urethra 139, 153, 156
Proximal phalanx 188, 252
of second toe 239
Prussak's space 53
Psoas
fat plane 138
muscle 88-90, 94, 149
shadow 135
Pterygopalatine fossa 28, 45
Pubic
ramus 152, 155, 157, 158
symphysis 130, 138, 142, 143, 150, 152, 154, 204, 209
Pubis 148, 205, 207
bone 147, 148, 156
Pulmonic valve 113, 114
Pulvinar of thalamus 16, 24
Putamen 11, 16, 21-23
Pyloric
antrum 121
canal 121
Pyramid 7, 12, 134
Pyramidal eminence 49
Pyriform sinus 63, 66, 69
Pyriformis 158
muscle 150

Q

Quadratus lumborum 88, 89
Quadratus
femoris 207, 208, 210, 211
lumborum 94, 95, 125
plantae 247-250, 253, 255-257
Quadriceps
femoris 215
tendon 235, 236
Quadrigeminal plate cistern 14, 24
Quadrilateral plate 202, 206

R

Radial
artery 176, 177, 186, 189-191, 196, 197
nerve 181-183
recurrent artery 196
tuberosity 180, 184
Radiocarpal joint 194
Radioulnar joint 184
Radius 176, 177, 180, 188, 189, 191, 192, 194

Ramus of mandible 57
Rectal gas shadow 138
Rectovaginal pouch 147, 149
Rectum 119, 126, 127, 140, 141, 146-151, 153, 156, 157, 206
Rectus
  abdominis 125, 147, 150, 156, 206
    muscle 139, 149, 150, 157
  femoris 127, 205-207, 209, 210, 214-216, 219
    muscle 142
Red nucleus 15, 23
Reflected tendon of superior oblique 30, 33
Renal
  cortex 134
  pelvis 134
Retromandibular vein 61, 62, 67
Retropubic space of Retzius 207
Right
  adrenal gland 123, 131, 132
  atrial appendage 103
  atrium 104, 105, 112, 115
  brachiocephalic
    artery 102
    vein 102
  diaphragm 114
  hepatic
    artery 118, 119
    duct 135
    vein 122
  inferior pulmonary artery 104
  internal iliac artery 118
  kidney 90, 124, 125, 130-132, 135
  lobe of liver 122, 123
  main
    bronchus 103, 114
    pulmonary artery 113
  mainstem bronchus 106, 111
  ovary 140, 144-146
  portal vein 123, 132
  pulmonary artery 103, 114, 115
  renal
    artery 118, 119, 124, 131
    vein 131
  round ligament 140
  subclavian vein 102
  superior pulmonary
    artery 103, 113
    vein 113
  upper lobe bronchus 106, 111
  ventricle 104, 105, 112-114
  ventricular outflow tract 103
Root entry zone 8
Rostrum of corpus callosum 21
Round
  ligament 140
  window 49, 55

S

Sacral
  ala 138
  foramen 76, 92
  nerve roots 98
  promontory 76, 90-92
Sacrococcygeal joint 76
Sacroiliac joint 90, 135, 138, 208
Sacrotuberous ligament 206
Sacrum 76, 90, 91, 139, 140, 146, 149-151, 206, 208
Scalenus
  anterior muscle 67, 70
  medius muscle 70
Scalp 19
Scaphoid 188-190, 192
Scapholunate ligament 192
Scapula 104, 114, 162, 167, 168, 170
  spine 162
Scapular
  body 167
  spine 162, 166, 170, 171
Sciatic nerve 146, 205, 206, 208, 210, 211, 214, 219
Sclera 28, 33
Segmental bronchi 109
Sella 30
Semicircular canals 13
Semimembranosus 217, 218, 229, 230, 234, 235
Seminal vesicle 127, 151, 155-157, 206
Semitendinosis 214, 215
Semitendinosus tendon 229, 230
Septum pellucidum 16, 17, 21, 22
Sesamoid bone 188, 239, 244
Short
  and long flexor tendons 254
  extensor tendons 255
Shoulder 161
Sigmoid
  colon 119, 150
  groove 51
  sinus 5, 6
Sinus tympani 49, 55
Small intestine 120
Snuff box 191
Soft palate 45, 61, 66, 68, 69
Soleus 220-225, 250, 251
Sphenoethmoidal recess 45
Sphenoid
  ostium 45
  sinus 13, 28, 29, 38, 43, 44, 67-69
Spinal
  canal 78, 81
  cord 8, 9, 67, 84-86, 105
  gray matter 85
Spine 71, 73
Spinolaminar
  junction 84, 91
  line 74
Spleen 120-123, 131, 132
Splenic
  artery 118, 119, 122, 123, 129, 130
  flexure 119, 123, 128-131, 136
    of colon 122
  vein 122, 131-133
Splenium 8
  corpus callosum 17
Splenius muscle 62, 63
Stapes bone 49
Stem of lateral sulcus 11
Sternoclavicular joint 102
Sternocleidomastoid muscle 62-67, 69, 70
Sternothyroid muscle 66
Sternum 102-104, 114
Stomach 122-124, 128-131
Straight sinus 5, 6, 9, 15, 25
Strap muscles 64, 69
Stria medullaris thalami 9, 16
Styloid process of
  radius 188
  of ulna 188
Stylomastoid foramen 56
Subclavian
  artery 70, 197
  vein 70
Submandibular gland 62, 63, 66, 67, 70
Subscapular artery 196, 197
Subscapularis 164, 169, 174
  bursa 163
  muscle 169
  tendon 165, 166
Superficial
  circumflex epigastric artery 260
  femoral artery 260, 261
  flexor muscles 185
  inferior epigastric artery 260
Superior
  basal segment bronchus 107, 108, 111, 112
  cerebellar
    artery 4, 5
    cistern 9
    peduncle 13, 14, 24
  cerebral artery 4
  colliculus 15, 24
  compartment of hip joint 138
  facet 74-76, 78, 82, 84, 88, 92-94, 97
  frontal
    gyrus 17-19, 21
    sulcus 19
  glenohumeral ligament 163-165
  horn, thyroid cartilage 63, 69
  labrum 164, 169, 205
  lateral
    genicular artery 232, 236
    geniculate artery 232
  medial genicular artery 232
  medullary velum 8, 9
  mesenteric
    artery 118, 119, 123, 133, 260
    vein 123, 132, 133
  ophthalmic vein 30-32
  orbital fissure 28, 45
  parietal lobule 17, 18
  pubic ramus 138, 143, 149, 202
  pulmonary vein 113
  ramus of pubis 203
  rectus 30-32
  sagittal sinus 5, 6, 15, 16, 18, 20, 24, 26

semicircular canal 51, 54, 55, 56
temporal gyrus 11, 22
thoracic artery 196, 197
turbinate 45
vena cava 115
vermis 14, 15
Supinator 176, 182-184, 186
crest 182
muscle 183
Supracapsular
artery 196
fat plane 138
Supraglenoid tuberosity 166
Suprascapular artery 166, 197
Suprasellar cistern 14, 21
Supraspinatus 166, 169, 170
muscle 169
tendon 166, 169
Surgical neck 162, 170
Sustentaculum tali 238, 243, 247-249
Sylvian fissure 15, 16, 20, 21, 24
Symphysis pubis 149, 207

T

Tail of
caudate nucleus 16
pancreas 123
Talar dome 245
Talonavicular joint 240
Talus 238, 239, 243, 244, 246, 248, 249, 256-258
Tarsal sinus 241, 243, 244, 248, 249, 251, 252
Tectum-midbrain 9
Tegmen tympanum 54
Temporal
bones and TM joint 47
horn 15, 21
of lateral ventricle 14
lobe 13, 20, 57
operculum 16, 20
pole 13
Temporalis muscle 60, 61, 66, 70
Tensor
fascia lata 205-207
muscle 127, 142
tympani 49, 52
muscle 49, 52
Tentorium cerebelli 23
Teres
major 170, 171
minor 168, 170, 171
Terminal ileum 119, 120, 126, 130
Thalamus 10, 16, 23
Thecal sac 88, 89, 91
Thoracoacromial artery 196
Thyrocervical trunk 196, 197
Thyroid
cartilage 63, 64, 66, 68, 69, 78
gland 65
isthmus 65
lobe 66
Tibia 220-222, 224, 228, 229, 231, 232, 235, 238, 244, 245, 248, 249-251, 257
Tibial
condyle 233, 236
nerve 214, 215, 221, 229, 230, 234, 236, 246
tubercle 229, 233
tuberosity 220, 228
Tibialis
anterior 220-222, 224, 225, 236, 251
tendon 221, 246, 250, 257
posterior 220-224, 233, 247-250
tendon 221, 246, 248, 250, 255, 256
Tibioperoneal trunk 261
Tibiotalar joint 246
space 238
Tongue 61, 65, 66, 68, 69
Tonsil 9, 12
Torus tubarius 45, 60
Trachea 65, 66, 74, 75, 81, 102, 106, 111, 114, 115
Transverse
cervical artery 196, 197
colon 119, 125, 128, 129
foramen 61, 83-85
sinus 5, 6, 26
Trapezium 188, 190-192
Trapezius 63, 67, 68, 169-171
muscle 61-64, 70
Trapezoid 188, 190-192
Triangular fibrocartilage 191, 193
Triceps 171, 174, 184-186
muscle 181
tendon 181, 185
Trigeminal nerve 8, 10, 13
Trilaminar pattern of uterus 150
Triquetrum 189-193
Trochlea 33, 180, 182-185
Trochlear notch 180, 185
True vocal cord 66, 69
Tuber cinereum 9
Tubercle of trapezium 190
Tuberosity of base of fifth metatarsal 239
Twelfth rib 76, 91

U

Ulna 176, 177, 180, 182, 185, 188, 189, 191-193
Ulnar
artery 176, 177, 189, 183, 196, 197
nerve 177, 181, 182, 184, 185, 190
recurrent artery 196
styloid 190, 191
Uncovertebral joint 74, 79
Uncus 10, 14, 15, 21
Upper
extremity 159
vessels 195
Ureter 134, 135
Ureteric jet 134
Urethra 142, 143, 145, 147, 149-154
Urinary bladder 127, 129-132, 134, 139, 141-143, 145, 147-151, 154-157, 206, 209
Urogenital diaphragm 152, 155, 156
Uterine
cavity 140
fundus 139, 140
Uterosacral ligament 140
Uterus 140, 144-149
Uvula 69

V

Vagina 142-144, 147-149
Vaginal fornix 141, 144
Vallecula 63, 66, 68, 69
Valvulae conniventes 120
Vascular impression 134
Vastus
intermedius 209, 210, 214, 215, 216, 219
lateralis 207-209, 214-217, 219, 232, 236
medialis 214-216, 218, 229, 232-234
Vein of Galen 6, 8, 16
Venous plexus 141
Ventral nerve root 87
Vermis 7-9, 13, 14, 24, 25
Vertebral
artery 12, 23, 69, 77-80, 84, 85, 87, 196
body 75, 79, 88, 89, 93-97
Vestibular
aqueduct 49, 50
nerve 7
Vestibule 7, 23, 49-51, 54, 55
Vitreous 29, 33
Vocal cord 64
Vomer 45

W

Wrist 187

Z

Zygoma 28, 29, 60
Zygomatic
arch 45, 66
bone 29
Zygomatico-frontal suture 45